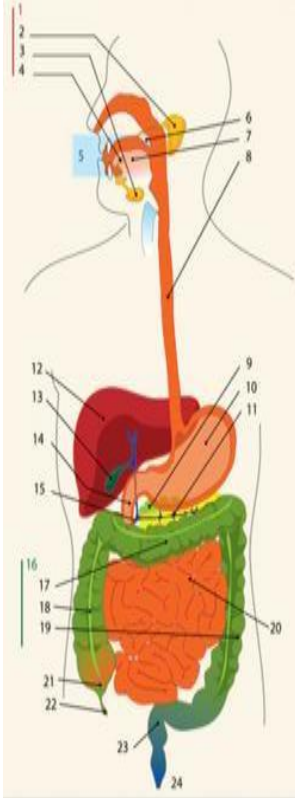
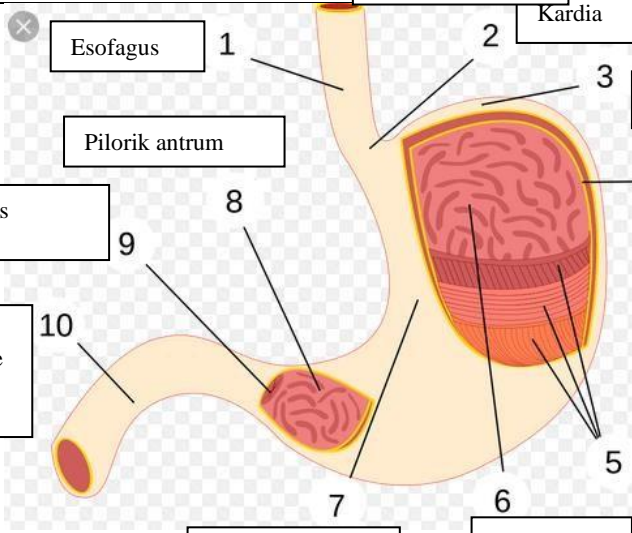
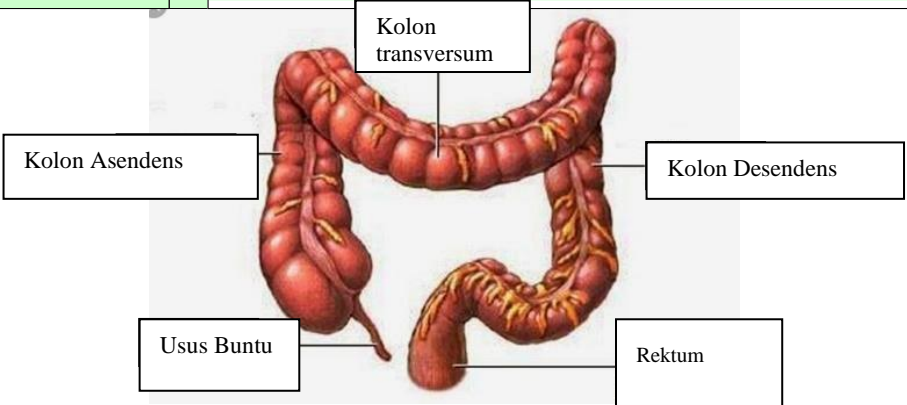


WORKSHEETS (LEMBAR KERJA)

Mata Kuliah	: Anatomi
Materi	: Anatomi Digesti
NIM>Nama Mahasiswa	: 2110101124/nurul sabillah

No	Keterangan	Pembahasan																								
1		<table border="0"> <tr> <td>1.Kelenjar Ludah</td> <td>13.Kantun Empedu</td> </tr> <tr> <td>2.Parotis</td> <td>14.Duodenum</td> </tr> <tr> <td>3.Submandibularis (bawah rahang)</td> <td>15.Saluran Empedu</td> </tr> <tr> <td>4.Sublingualis (bawah lidah)</td> <td>16.Kolon</td> </tr> <tr> <td>5.Rongga mulut</td> <td>17.Kolon transversum</td> </tr> <tr> <td>6.Amandel</td> <td>18.Kolon Aacenden</td> </tr> <tr> <td>7.Lidah</td> <td>19.Kolon Descenden</td> </tr> <tr> <td>8.Esofagus</td> <td>20.Ileum</td> </tr> <tr> <td>9.Pankreas</td> <td>21.Sekum</td> </tr> <tr> <td>10.Lambng</td> <td>22.Appendiks/Umbai cacing</td> </tr> <tr> <td>11.Saluran pankreas</td> <td>23.Rektum/Poros usus</td> </tr> <tr> <td>12.Hati</td> <td>24.Anus</td> </tr> </table>	1.Kelenjar Ludah	13.Kantun Empedu	2.Parotis	14.Duodenum	3.Submandibularis (bawah rahang)	15.Saluran Empedu	4.Sublingualis (bawah lidah)	16.Kolon	5.Rongga mulut	17.Kolon transversum	6.Amandel	18.Kolon Aacenden	7.Lidah	19.Kolon Descenden	8.Esofagus	20.Ileum	9.Pankreas	21.Sekum	10.Lambng	22.Appendiks/Umbai cacing	11.Saluran pankreas	23.Rektum/Poros usus	12.Hati	24.Anus
1.Kelenjar Ludah	13.Kantun Empedu																									
2.Parotis	14.Duodenum																									
3.Submandibularis (bawah rahang)	15.Saluran Empedu																									
4.Sublingualis (bawah lidah)	16.Kolon																									
5.Rongga mulut	17.Kolon transversum																									
6.Amandel	18.Kolon Aacenden																									
7.Lidah	19.Kolon Descenden																									
8.Esofagus	20.Ileum																									
9.Pankreas	21.Sekum																									
10.Lambng	22.Appendiks/Umbai cacing																									
11.Saluran pankreas	23.Rektum/Poros usus																									
12.Hati	24.Anus																									
		<table border="0"> <tr> <td>1. Esofagus</td> <td>2. Kardia</td> </tr> <tr> <td>3. Fundus</td> <td>4. Selaput Lender</td> </tr> <tr> <td>5. Otot Lapisan</td> <td>6. Lambung Mukosa</td> </tr> <tr> <td>7. Tumbuh perut</td> <td>8. Pankreas</td> </tr> <tr> <td>9. Pylorus</td> <td>10. Usus 12 jari (duodenum)</td> </tr> <tr> <td>11. Pylorik antrum</td> <td></td> </tr> </table>	1. Esofagus	2. Kardia	3. Fundus	4. Selaput Lender	5. Otot Lapisan	6. Lambung Mukosa	7. Tumbuh perut	8. Pankreas	9. Pylorus	10. Usus 12 jari (duodenum)	11. Pylorik antrum													
1. Esofagus	2. Kardia																									
3. Fundus	4. Selaput Lender																									
5. Otot Lapisan	6. Lambung Mukosa																									
7. Tumbuh perut	8. Pankreas																									
9. Pylorus	10. Usus 12 jari (duodenum)																									
11. Pylorik antrum																										

No	Keterangan	Pembahasan
		 <p>The diagram illustrates the large intestine (colon) and its associated structures. The main components are labeled as follows:</p> <ul style="list-style-type: none"> Kolon Asendens: The ascending colon, located on the right side of the abdomen. Kolon transversum: The transverse colon, located across the upper abdomen. Kolon Desendens: The descending colon, located on the left side of the abdomen. Usus Buntu: The cecum, a pouch-like structure at the junction of the ascending and transverse colons. Rektum: The rectum, the terminal part of the large intestine leading to the anus.