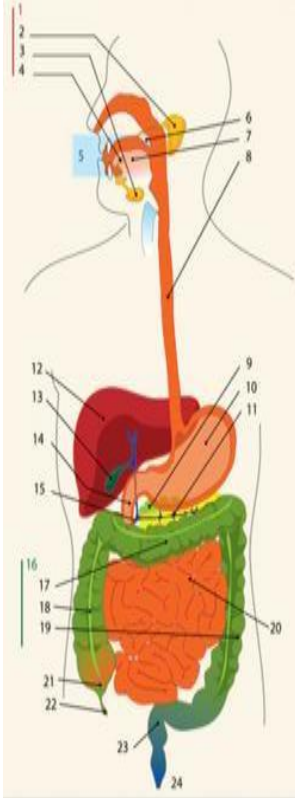
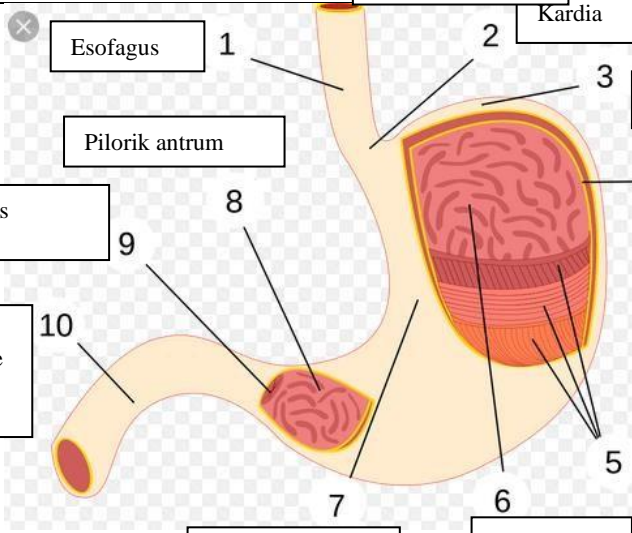
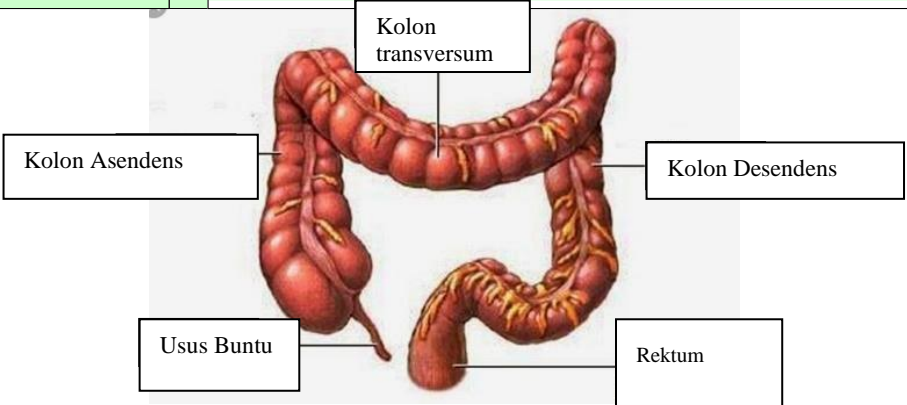


WORKSHEETS (LEMBAR KERJA)

Mata Kuliah	: Anatomi
Materi	: Anatomi Digesti
NIM>Nama Mahasiswa	: 2110101125/sari ismi harsih

No	Keterangan	Pembahasan																								
1		<table border="0"> <tr> <td>1.Kelenjar Ludah</td> <td>13.Kantun Empedu</td> </tr> <tr> <td>2.Parotis</td> <td>14.Duodenum</td> </tr> <tr> <td>3.Submandibularis (bawah rahang)</td> <td>15.Saluran Empedu</td> </tr> <tr> <td>4.Sublingualis (bawah lidah)</td> <td>16.Kolon</td> </tr> <tr> <td>5.Rongga mulut</td> <td>17.Kolon transversum</td> </tr> <tr> <td>6.Amandel</td> <td>18.Kolon Aacenden</td> </tr> <tr> <td>7.Lidah</td> <td>19.Kolon Descenden</td> </tr> <tr> <td>8.Esofagus</td> <td>20.Ileum</td> </tr> <tr> <td>9.Pankreas</td> <td>21.Sekum</td> </tr> <tr> <td>10.Lambng</td> <td>22.Appendiks/Umbai cacing</td> </tr> <tr> <td>11.Saluran pankreas</td> <td>23.Rektum/Poros usus</td> </tr> <tr> <td>12.Hati</td> <td>24.Anus</td> </tr> </table>	1.Kelenjar Ludah	13.Kantun Empedu	2.Parotis	14.Duodenum	3.Submandibularis (bawah rahang)	15.Saluran Empedu	4.Sublingualis (bawah lidah)	16.Kolon	5.Rongga mulut	17.Kolon transversum	6.Amandel	18.Kolon Aacenden	7.Lidah	19.Kolon Descenden	8.Esofagus	20.Ileum	9.Pankreas	21.Sekum	10.Lambng	22.Appendiks/Umbai cacing	11.Saluran pankreas	23.Rektum/Poros usus	12.Hati	24.Anus
1.Kelenjar Ludah	13.Kantun Empedu																									
2.Parotis	14.Duodenum																									
3.Submandibularis (bawah rahang)	15.Saluran Empedu																									
4.Sublingualis (bawah lidah)	16.Kolon																									
5.Rongga mulut	17.Kolon transversum																									
6.Amandel	18.Kolon Aacenden																									
7.Lidah	19.Kolon Descenden																									
8.Esofagus	20.Ileum																									
9.Pankreas	21.Sekum																									
10.Lambng	22.Appendiks/Umbai cacing																									
11.Saluran pankreas	23.Rektum/Poros usus																									
12.Hati	24.Anus																									
		<table border="0"> <tr> <td>1. Esofagus</td> <td>2. Kardia</td> </tr> <tr> <td>3. Fundus</td> <td>4. Selaput Lender</td> </tr> <tr> <td>5. Otot Lapisan</td> <td>6. Lambung Mukosa</td> </tr> <tr> <td>7. Tumbuh perut</td> <td>8. Pankreas</td> </tr> <tr> <td>9. Pylorus</td> <td>10. Usus 12 jari (duodenum)</td> </tr> <tr> <td>11. Pyloric antrum</td> <td></td> </tr> </table>	1. Esofagus	2. Kardia	3. Fundus	4. Selaput Lender	5. Otot Lapisan	6. Lambung Mukosa	7. Tumbuh perut	8. Pankreas	9. Pylorus	10. Usus 12 jari (duodenum)	11. Pyloric antrum													
1. Esofagus	2. Kardia																									
3. Fundus	4. Selaput Lender																									
5. Otot Lapisan	6. Lambung Mukosa																									
7. Tumbuh perut	8. Pankreas																									
9. Pylorus	10. Usus 12 jari (duodenum)																									
11. Pyloric antrum																										

No	Keterangan	Pembahasan
		 <p>The diagram illustrates the large intestine (colon) in a human body. It is a long, muscular tube that is wider than the small intestine. The large intestine is divided into several parts: the cecum (Usus Buntu) at the bottom left, the ascending colon (Kolon Asendens) on the right side, the transverse colon (Kolon transversum) at the top, the descending colon (Kolon Desendens) on the left side, and the rectum (Rektum) at the bottom right. The large intestine is shown in a reddish-brown color with visible blood vessels and a network of nerves.</p>