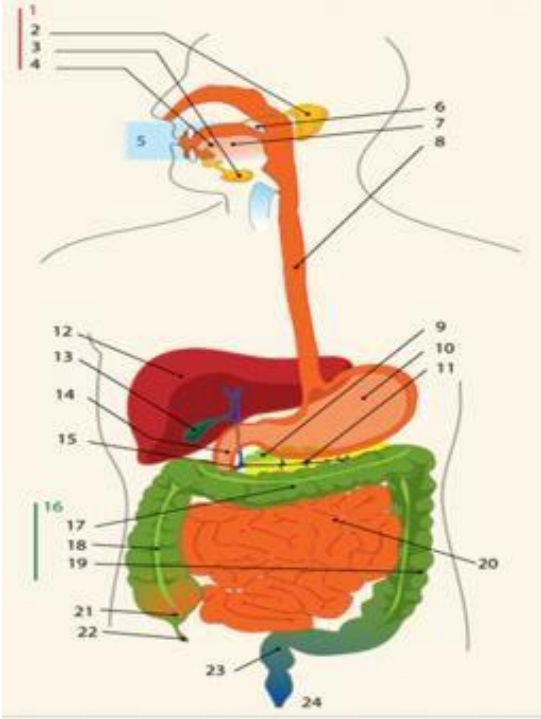
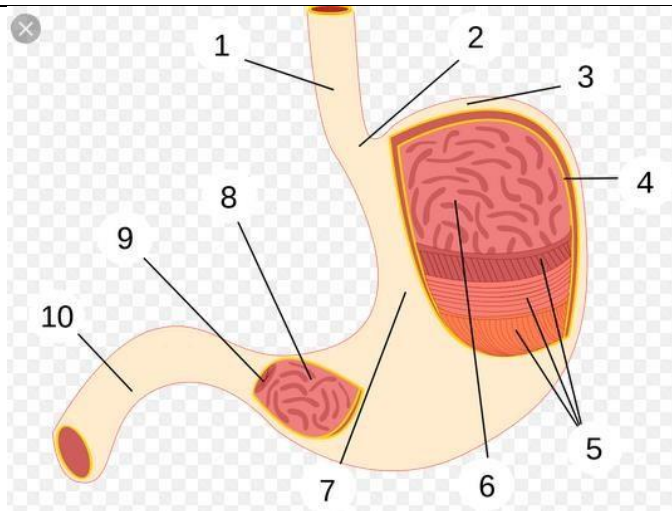


WORKSHEETS (LEMBAR KERJA)

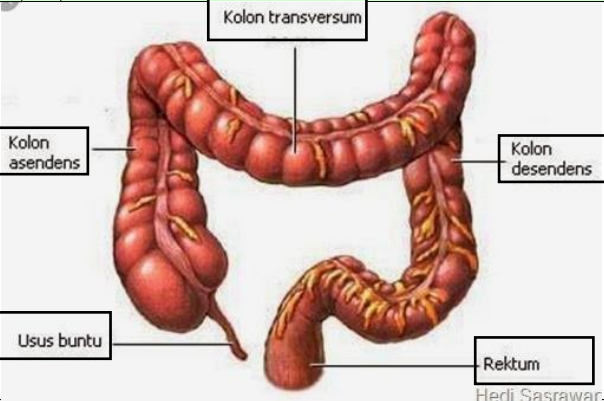
Mata Kuliah	: Anatomi
Materi	: Anatomi Digesti
NIM>Nama Mahasiswa	: 2110101100_ SILMI FUJI LESTARI

No	Keterangan	Pembahasan
1		<p>DIAGRAM SISTEM PENCERNAAN</p> <ol style="list-style-type: none">1. kelenjar ludah2. Parotis3. Submandibularis (bawah rahang)4. Sublingualis (bawah lidah)5. Rongga mulut6. Amandel7. Lidah8. Esofagus9. Pangkreas10. Lambung11. Saluran pankreas12. Hati13. Kantung empedu14. Duodenum15. Saluran empedu16. Kolon17. Kolon trasversum18. Kolon ascenden19. Kolon descenden20. Ileum21. Sekum22. Appendiks / umbai cacing23. Rektum / poros usus24. anus



BAGIAN LAMBUNG

1. Esofagus
2. Kardia
3. Fundus
4. Selaput lender
5. Otot lapisan
6. Lambung mukosa
7. Tubuh perut
8. Pilorik antrum
9. Pylorus
10. Usus dua belas jari (duodenum)

No	Keterangan	Pembahasan
		 <p>An anatomical illustration of the human large intestine (colon) and rectum. The diagram shows the characteristic S-shaped structure of the large intestine. Labels with leader lines point to the following parts: Kolon transversum (the upper horizontal part), Kolon asendens (the right vertical part), Kolon desendens (the left vertical part), Usus buntu (the cecum, a pouch at the start of the large intestine), and Rektum (the final straight part of the large intestine). The illustration is credited to Hedi Sasrawar.</p>