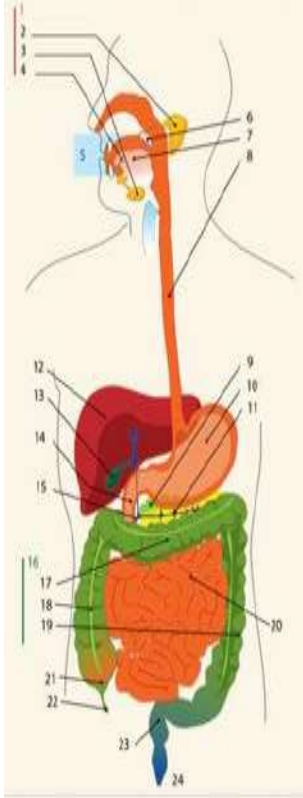
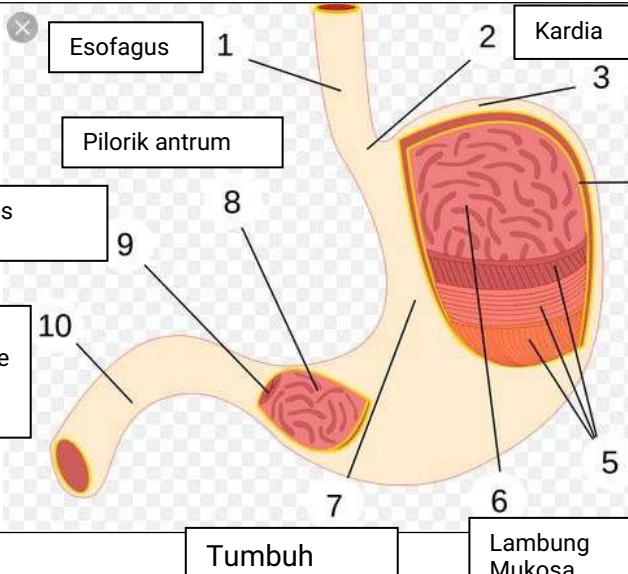
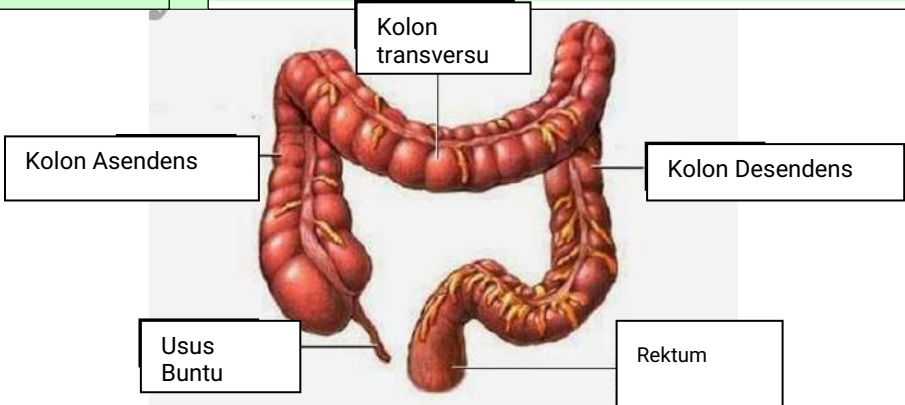


WORKSHEETS (LEMBAR KERJA)

Mata Kuliah	: Anatomi
Materi	: Anatomi Digesti
NIM>Nama Mahasiswa	: 2110101083/Riska Arinanda

No	Keterangan	Pembahasan
1		<div style="display: flex; flex-wrap: wrap;"> <div style="width: 50%;"> <p>1.Kelenjar Ludah</p> <p>2.Parotis</p> <p>3.Submandibular is(bawah</p> <p>4.Sublingualis (bawah lidah)</p> <p>5.Rongga mulut</p> <p>6.Amandel</p> <p>7.Lidah</p> <p>8.Esofagus</p> <p>9.Pankreas</p> <p>10.Lambng</p> <p>11.Saluran pangkreas</p> </div> <div style="width: 50%;"> <p>12.Hati</p> <p>13.Kantun Empedu</p> <p>14.Duodenum</p> <p>15.Saluran</p> <p>16.Kolon</p> <p>17.Kolon transversum</p> <p>18.Kolon Aacenden</p> <p>19.Kolon Descenden</p> <p>20.Ileum</p> <p>21.Sekum</p> <p>22.Appendiks/Umbai cacing</p> <p>23.Rektum/Poros usus</p> <p>24.Anus</p> </div> </div>
		<div style="display: flex; flex-wrap: wrap;"> <div style="width: 50%;"> <p>1 Esofagus</p> <p>2 Kardia</p> <p>3 Fundus</p> <p>4 Selaput I ender</p> <p>5 Otot Lapisan</p> <p>6 Lambung Mukosa</p> <p>7 Tumbuh</p> <p>8 Pilonik antrum</p> <p>9 Pilonus</p> <p>10 Usus 12 jari(duodenum)</p> </div> <div style="width: 50%;"> </div> </div>



No	Keterangan	Pembahasan
		 <p>The diagram illustrates the large intestine (colon) and its associated structures. The main components are labeled as follows:</p> <ul style="list-style-type: none"> Kolon Asendens: The ascending colon, located on the right side of the abdomen. Kolon transversu: The transverse colon, located across the upper abdomen. Kolon Desendens: The descending colon, located on the left side of the abdomen. Usus Buntu: The cecum, the large pouch at the beginning of the large intestine. Rektum: The rectum, the final part of the large intestine that leads to the anus.