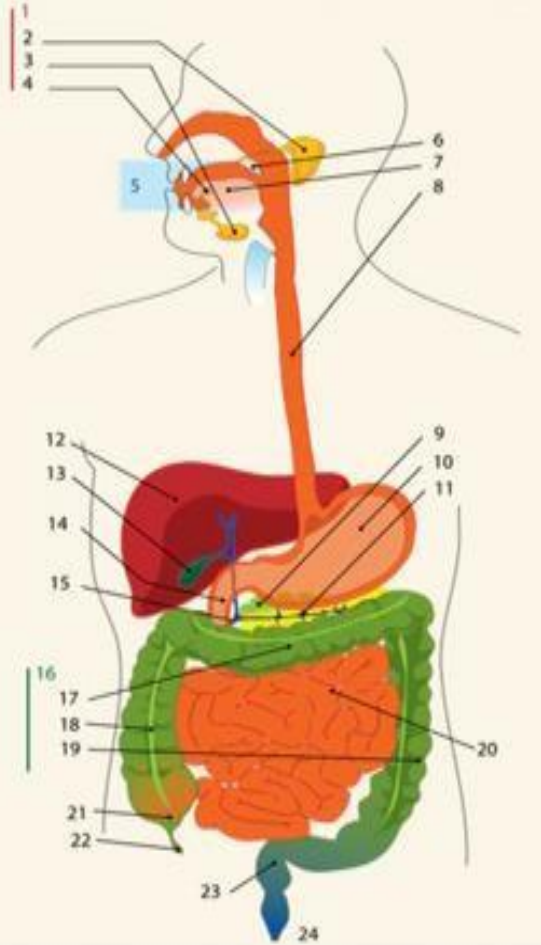
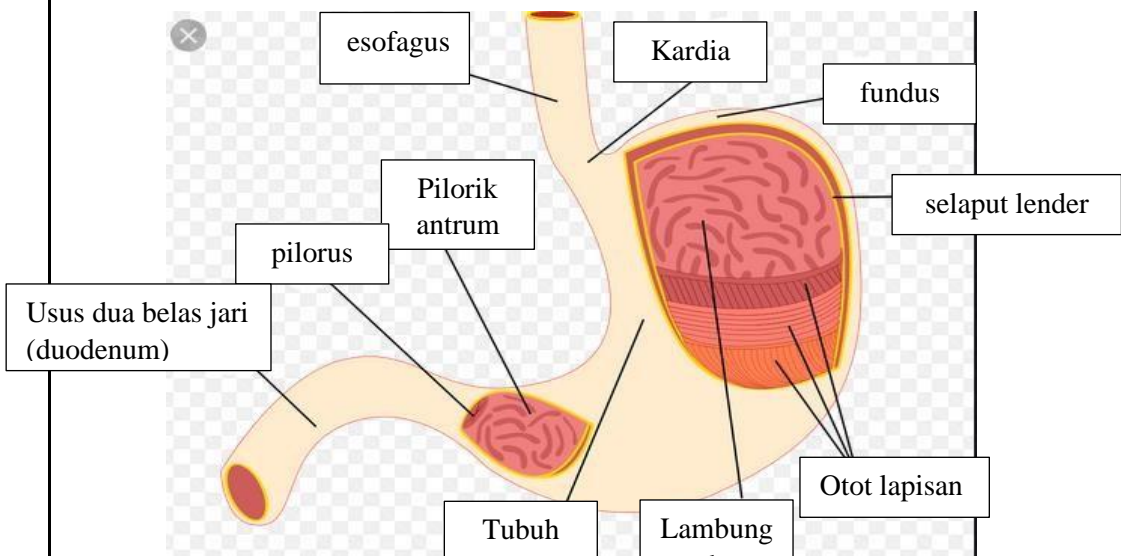


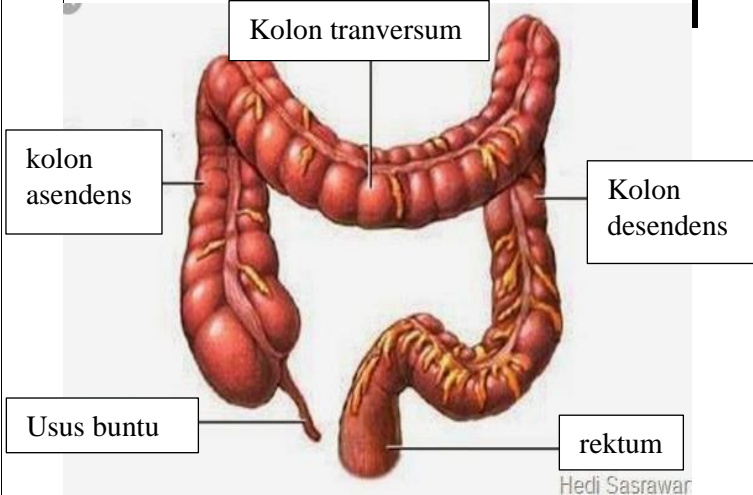
WORKSHEETS (LEMBAR KERJA)

Mata Kuliah : Anatomi
Materi : Anatomi Digesti
NIM>Nama Mahasiswa : Lyla aleyda lasawedi

No	Keterangan	Pembahasan
1		<ol style="list-style-type: none"> 1.Kelenjar ludah 2.kelenjar parotis 3.Kelenjar submandibularis (bawah rahang) 4.kelenjar sublingualis(bawah lidah) 5.mulut 6.amandel 7.lidah 8.esophagus 9.pankreas 10.lambung 11. saluran pankreas 12.hati 13.kantung empedu 14.doudenum 15.saluran empedu 16. colon 17.transverse colon 18.colon asendens 19.colon descendens 20.ileum (usus halus) 21.cecum 22.usus buntu 23.rektum 24.anus
		

WORKSHEETS (LEMBAR KERJA)

Mata Kuliah : Anatomi
Materi : Anatomi Digesti
NIM>Nama Mahasiswa : Lyla aleyda lasawedi

No	Keterangan	Pembahasan
	 <p>The diagram illustrates the large intestine (colon) and its associated structures. The main components are labeled as follows:</p> <ul style="list-style-type: none">Kolon transversum: The upper horizontal part of the large intestine.kolon asendens: The ascending part of the large intestine on the right side.Usus buntu: The vermiform appendix, a small pouch at the end of the cecum.rektum: The rectum, the terminal part of the large intestine.Kolon desendens: The descending part of the large intestine on the left side. <p><small>Hedi Sasrawar</small></p>	