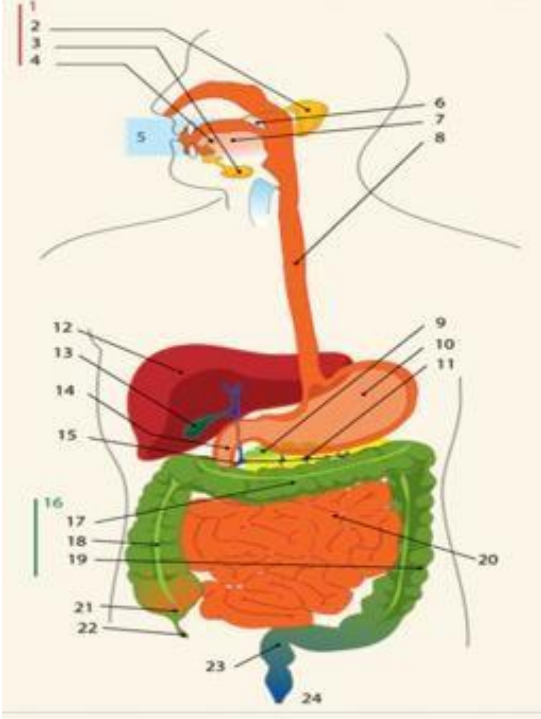
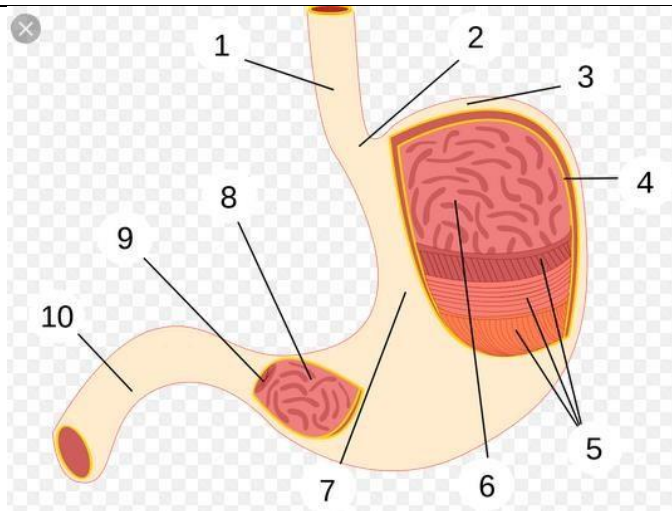


**WORKSHEETS (LEMBAR KERJA)**

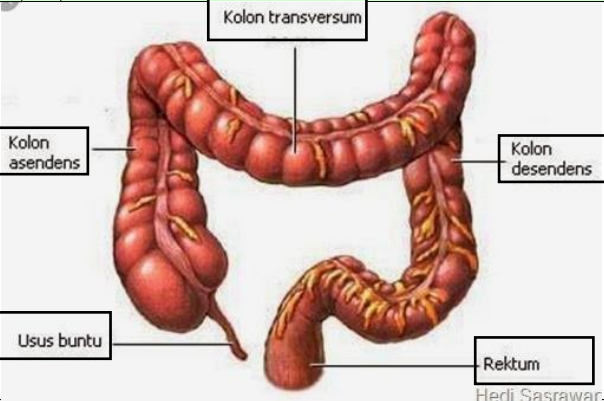
<b>Mata Kuliah</b>	<b>: Anatomi</b>
<b>Materi</b>	<b>: Anatomi Digesti</b>
<b>NIM&gt;Nama Mahasiswa</b>	<b>: 210101068_ IRNA RARA JUNIKA</b>

No	Keterangan	Pembahasan
1		<p><b>DIAGRAM SISTEM PENCERNAAN</b></p> <ol style="list-style-type: none"><li>1. kelenjar ludah</li><li>2. Parotis</li><li>3. Submandibularis ( bawah rahang )</li><li>4. Sublingualis ( bawah lidah )</li><li>5. Rongga mulut</li><li>6. Amandel</li><li>7. Lidah</li><li>8. Esofagus</li><li>9. Pangkreas</li><li>10. Lambung</li><li>11. Saluran pankreas</li><li>12. Hati</li><li>13. Kantung empedu</li><li>14. Duodenum</li><li>15. Saluran empedu</li><li>16. Kolon</li><li>17. Kolon trasversum</li><li>18. Kolon ascenden</li><li>19. Kolon descenden</li><li>20. Ileum</li><li>21. Sekum</li><li>22. Appendiks / umbai cacing</li><li>23. Rektum / poros usus</li><li>24. anus</li></ol>



### BAGIAN LAMBUNG

1. Esofagus
2. Kardia
3. Fundus
4. Selaput lender
5. Otot lapisan
6. Lambung mukosa
7. Tubuh perut
8. Pilorik antrum
9. Pylorus
10. Usus dua belas jari ( duodenum )

No	Keterangan	Pembahasan
		 <p data-bbox="1029 645 1161 672">Hedi Sasrawar</p>