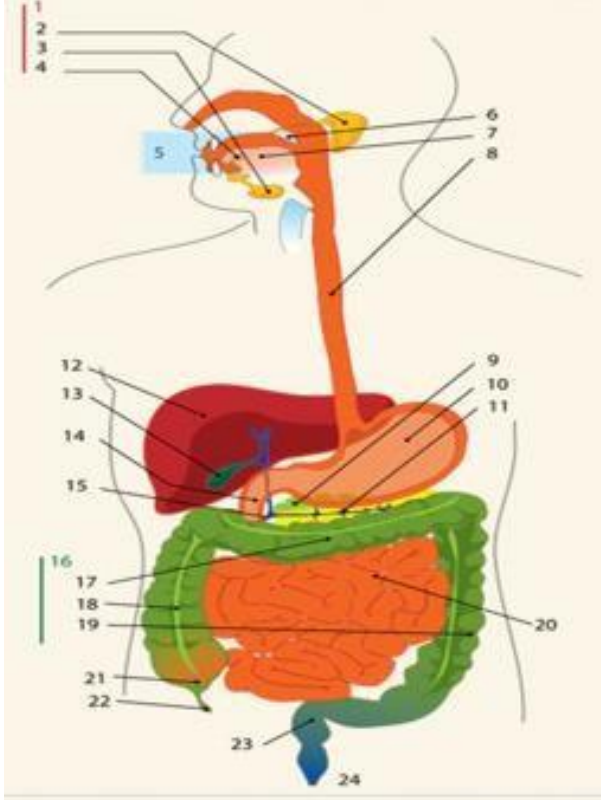
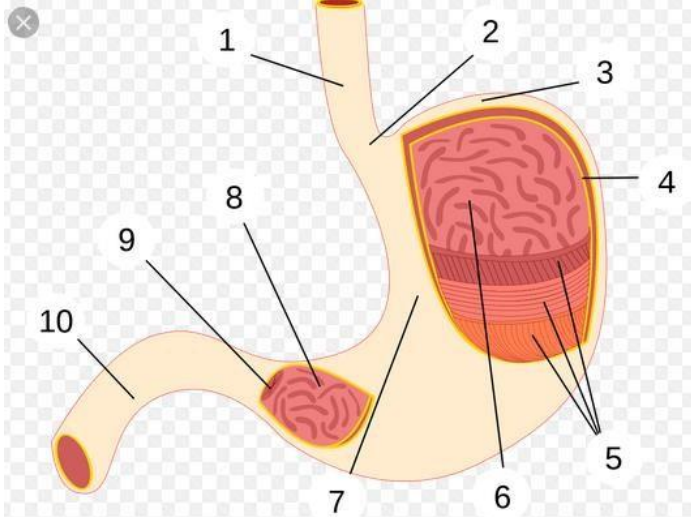


**WORKSHEETS (LEMBAR KERJA)**

<b>Mata Kuliah</b>	<b>: Anatomi</b>
<b>Materi</b>	<b>: Anatomi Digesti</b>
<b>NIM&gt;Nama Mahasiswa</b>	<b>: 2110101098/Renita Pramesti Ardita Putri</b>

No	Keterangan	Pembahasan
1		<ol style="list-style-type: none"> <li>1. Kelenjer Ludah</li> <li>2. Parotid Gland</li> <li>3. Submandibular Gland</li> <li>4. Sublingual Gland</li> <li>5. Rongga Mulut</li> <li>6. Amandel</li> <li>7. Tongue</li> <li>8. Esophagus</li> <li>9. Pankreas</li> <li>10. Stomach</li> <li>11. Saluran Pankreas</li> <li>12. Liver</li> <li>13. Gallbladder</li> <li>14. Duodenum</li> <li>15. Saluran Empedu</li> <li>16. Colon</li> <li>17. Transverse Colon</li> <li>18. Ascending Colon</li> <li>19. Descending Colon</li> <li>20. Ileum</li> <li>21. Cecum</li> <li>22. Vermiform Appendix</li> <li>23. Rectum</li> <li>24. Anus</li> </ol>
		<ol style="list-style-type: none"> <li>1. Esofagus</li> <li>2. Cardia</li> <li>3. Fundus</li> <li>4. Serosa</li> <li>5. Otot lapisan</li> <li>6. Rugae</li> <li>7. Tubuh perut</li> <li>8. Pilorik antrum</li> <li>9. Pylorus</li> <li>10. Duodenum</li> </ol>

No	Keterangan	Pembahasan
	<div data-bbox="304 376 644 443">Ascending Colon</div> <div data-bbox="320 562 667 629">Vermiform Appendix</div>	<div data-bbox="699 241 995 309">Transverse Colon</div> <div data-bbox="1043 383 1382 450">Descending Colon</div> <div data-bbox="1018 584 1299 651">Rectum</div> 