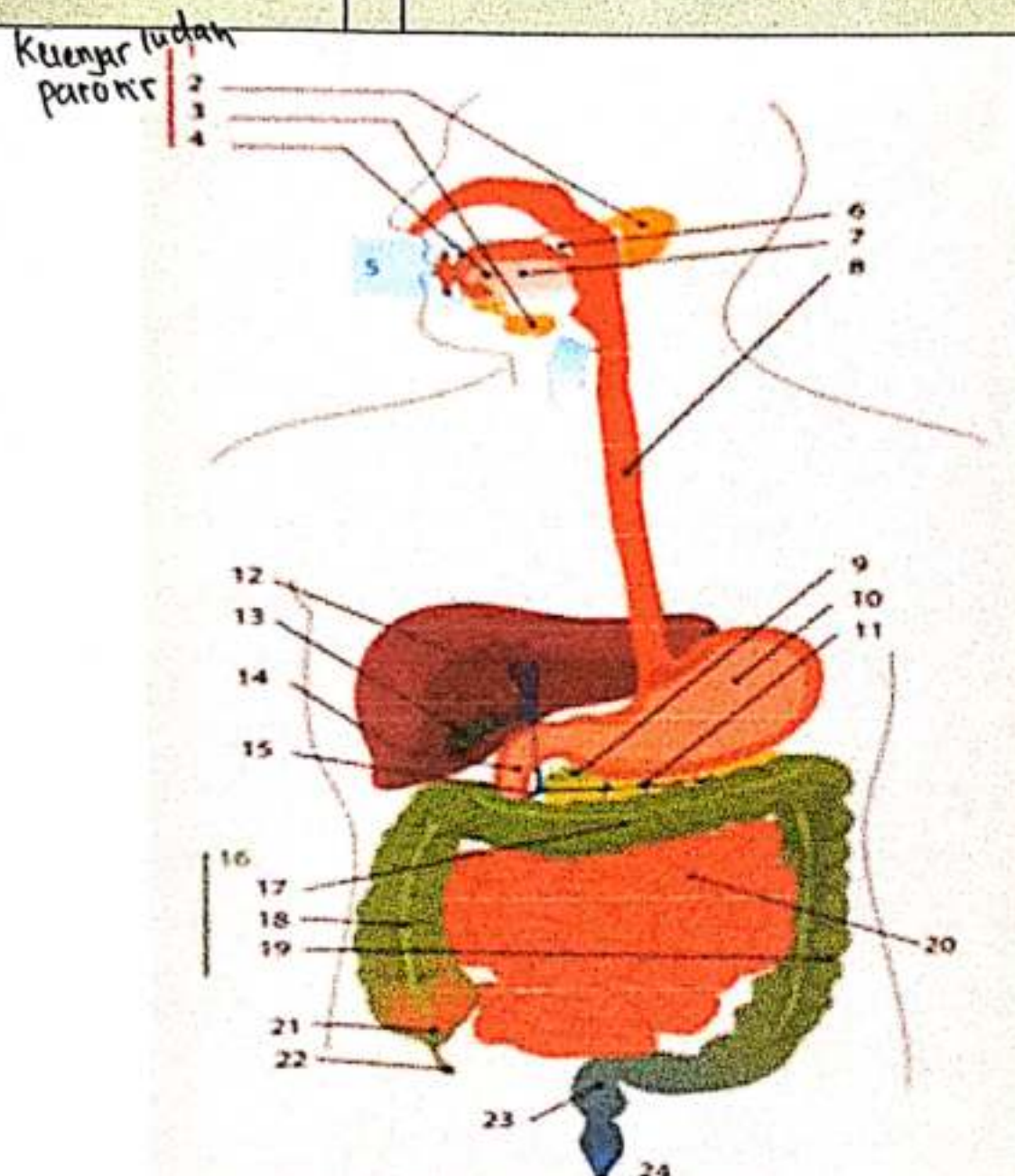
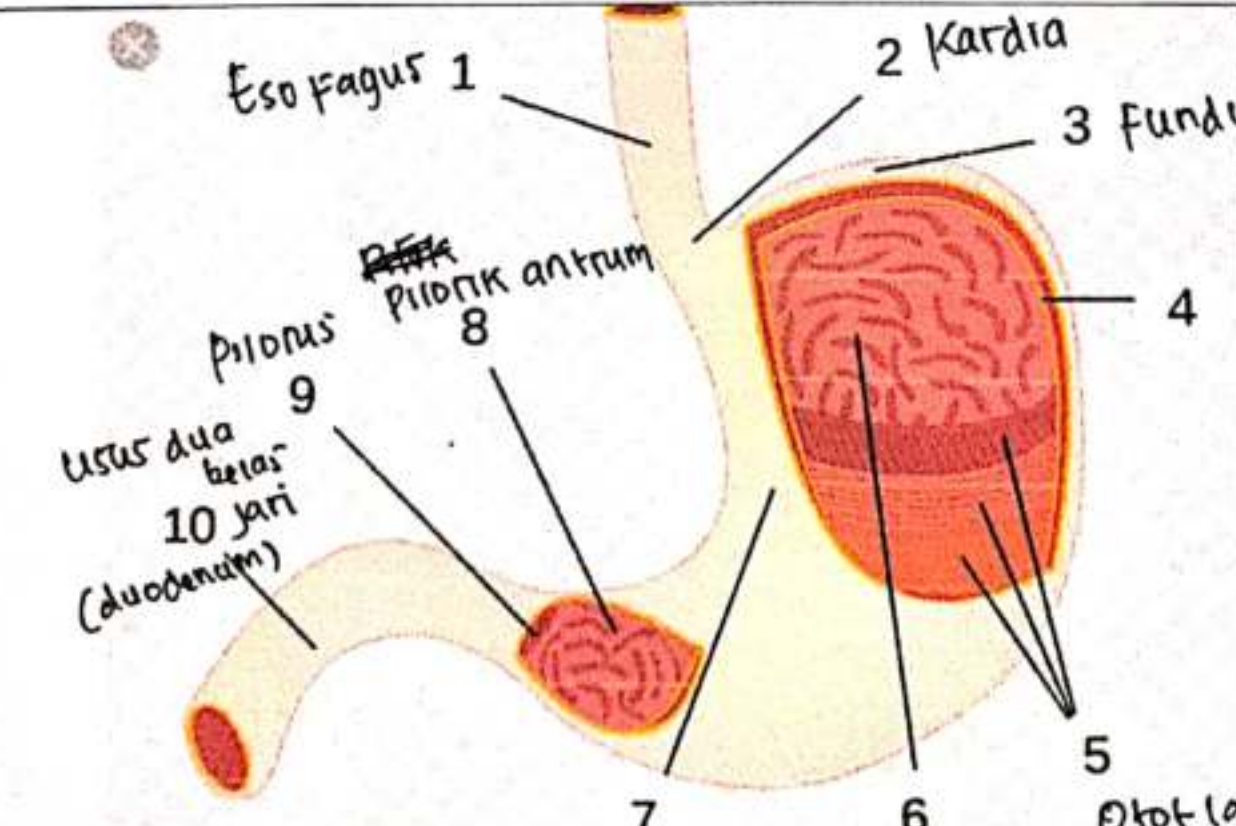
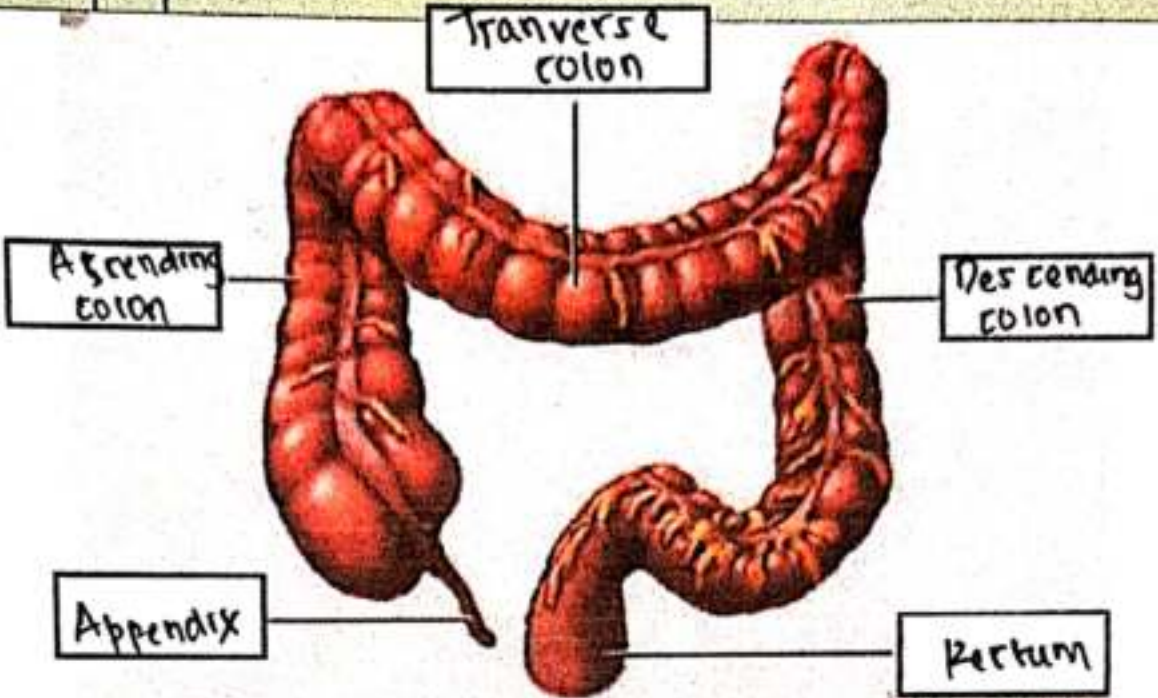


WORKSHEETS (LEMBAR KERJA)

Mata Kuliah	: Anatomi
Materi	: Anatomi Digesti
NIM>Nama Mahasiswa	: 2110101105 Shivani Nurrahmah Durnady

No	Keterangan	Pembahasan
1	 <p style="margin-left: 20px;">Kelenjar ludah parotid</p>	<ol style="list-style-type: none"> 1. Kelenjar ludah 2. Parotid 3. submandibular 4. sublingualis 5. Rongga mulut 6. Amandel 7. Lidah 8. Esofagus 9. pankreas 10. Lambung 11. saluran pankreas 12. Hati 13. Kantung empedu 14. duodenum 15. saluran empedu 16. Kolon 17. Kolon transversum 18. Kolon ascendens 19. Kolon descendens 20. Ileum 21. sekum 22. Appendix / Umbai raring 23. Rektum 24. Anus
	 <p style="margin-left: 20px;">Esofagus 1</p> <p style="margin-left: 20px;">2 Kardial</p> <p style="margin-left: 20px;">3 Fundus</p> <p style="margin-left: 20px;">4 Salaput lendir</p> <p style="margin-left: 20px;">5 Otot lapis</p> <p style="margin-left: 20px;">6 mukosa</p> <p style="margin-left: 20px;">7 lambung</p> <p style="margin-left: 20px;">8 Pilonik antrum</p> <p style="margin-left: 20px;">9 Pilonus</p> <p style="margin-left: 20px;">10 Usus dua belas jari (duodenum)</p> <p style="margin-left: 20px;">Tubuh perut</p>	

No	Keterangan	Pembahasan
		 <p>The diagram illustrates the large intestine (colon) and its associated structures. The main components are labeled as follows:</p> <ul style="list-style-type: none"> Transverse colon: The upper horizontal part of the large intestine. Ascending colon: The vertical part on the right side that carries material from the cecum up to the transverse colon. Descending colon: The vertical part on the left side that carries material from the transverse colon down to the sigmoid colon. Appendix: A small, finger-like projection from the bottom of the cecum (the large sac at the junction of the ascending and transverse colons). Pertum: The sigmoid colon, which is the lower, S-shaped part of the large intestine.