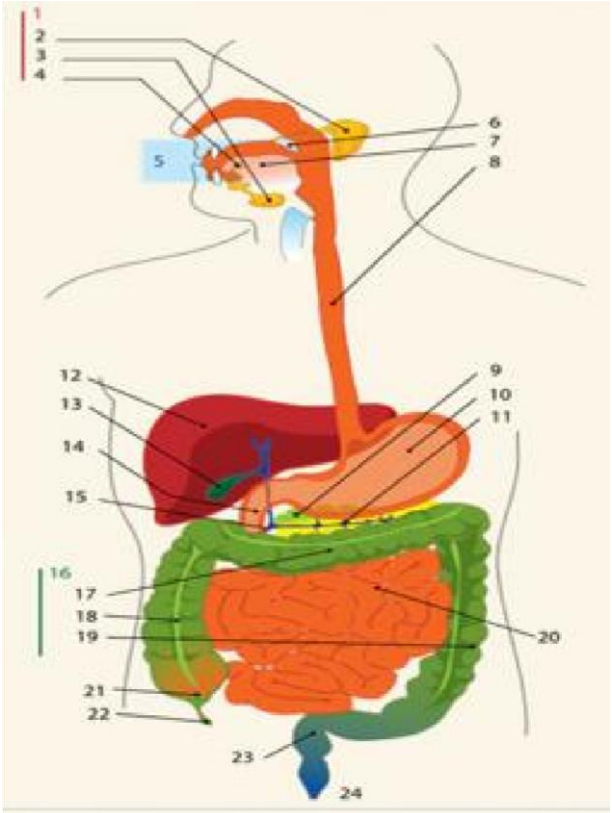
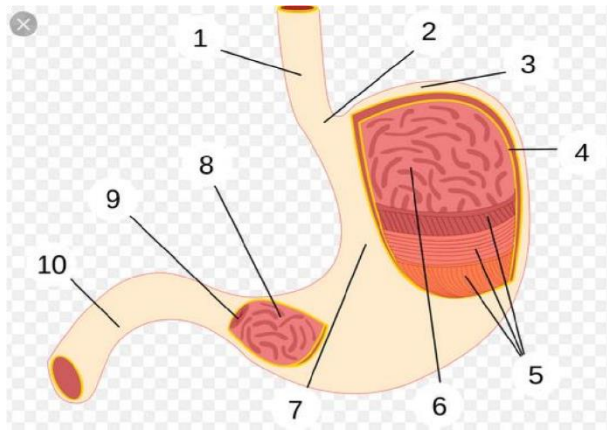


## WORKSHEETS (LEMBAR KERJA)

**Mata Kuliah** : Anatomi  
**Materi** : Anatomi Digesti  
**NIM>Nama Mahasiswa** : 2110101101/SHINTA ELMANORA

No	Keterangan	Pembahasan
1	<ol style="list-style-type: none"><li>1. Kelenjar ludah</li><li>2. Parotis</li><li>3. Submandibularis(bawah rahang)</li><li>4. Sublingus (bawah lidah)</li><li>5. Rongga mulut</li><li>6. Amandel</li><li>7. Lidah</li><li>8. Esodafagus</li><li>9. Pankreas</li><li>10. Lambung</li><li>11. Saluran pankreas</li><li>12. Hati</li><li>13. Kantung empedu</li><li>14. Duodenum</li><li>15. Saluran empedu</li><li>16. Kalon</li><li>17. Kalon transversum</li><li>18. Kalon ascenden</li><li>19. Kalon descenden</li><li>20. Ileum</li><li>21. Sekum</li><li>22. Appendiks/umbai cacing</li><li>23. Rektum / poros usus</li><li>24. Anus</li></ol>	 An anatomical diagram of the human digestive system. The diagram shows the oral cavity, salivary glands, esophagus, stomach, liver, gallbladder, pancreas, and the large and small intestines. The organs are color-coded: the mouth and esophagus are orange, the stomach is red, the liver is dark red, the gallbladder is yellow, the pancreas is light green, the large intestine is green, and the small intestine is orange. The diagram is labeled with numbers 1 through 24, corresponding to the list in the 'Keterangan' column.



1. Esofagus
2. Kardia
3. Fundus
4. Selaput lender
5. Otot lapisan
6. Lambung mukosa
7. Tubuh perut
8. Pilorik antrum
9. Pilorus
10. Usus dua belas jari (duodenum)

No	Keterangan	Pembahasan
		<div style="border: 1px solid black; padding: 5px; display: inline-block; margin-bottom: 10px;"><b>Kolon transversum</b></div>
	<b>Kolon asendens</b>	<b>Kolon desendens</b>
	<b>Usus buntu</b>	<b>Rektum</b>