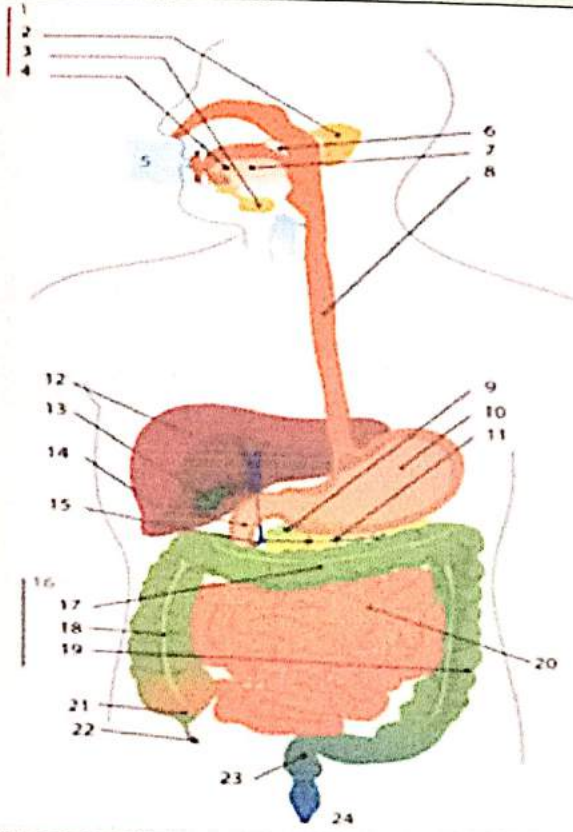
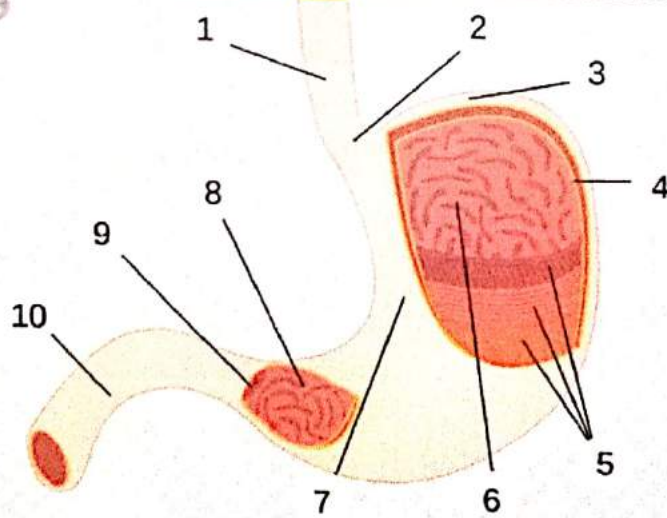
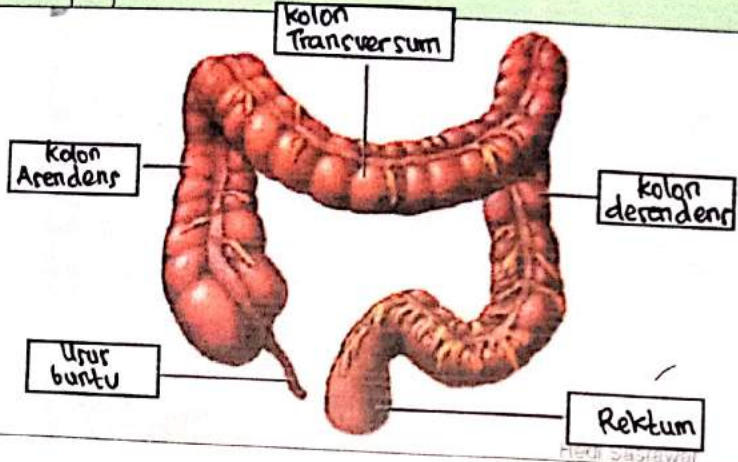


WORKSHEETS (LEMBAR KERJA)

Mata Kuliah	: Anatomi
Materi	: Anatomi Digesti
NIM>Nama Mahasiswa	: 2110101095 / Raisa Dwi Nur Vika .

No	Keterangan	Pembahasan
1		<ol style="list-style-type: none"> 1. Kelenjer ludah 2. Parotis 3. submandibularis (bawah rahang) 4. sublingualis (bawah lidah) 5. Rongga mulut 6. Amanbel 7. Lidah 8. Esofagus 9. Pankreas 10. Lambung 11. Saluran pankreas 12. Hati 13. Kantung Empedu 14. duodenum 15. Saluran empedu 16. Kolon 17. Kolon transversum 18. Kolon ascenden 19. Kolon 20. Ileum 21. Sekum 22. Appendiks / umbai cacing 23. Rektum / poros usur 24. Anus
		<ol style="list-style-type: none"> 1. Esofagus 2. Kardia 3. Fundus 4. Selaput lender 5. otot lapisan 6. Lambung mukosa 7. Tubuh Penut 8. Pilonik antrum 9. Pilonus 10- Usur dua belas jari (duo denum)

No	Keterangan	Pembahasan
		 <p>The diagram illustrates the large intestine (colon) and its associated structures. The main components are labeled as follows:</p> <ul style="list-style-type: none"> Kolon Transversum: The horizontal part of the large intestine at the top. Kolon Ascendens: The vertical part of the large intestine on the right side. Kolon Desendens: The vertical part of the large intestine on the left side. Uter buntu: The vermiform appendix, a small projection from the bottom of the cecum. Rektum: The final part of the large intestine, leading to the rectum.