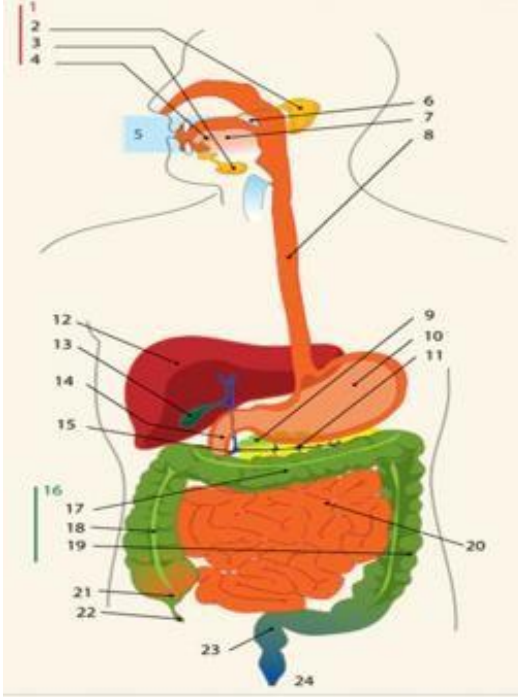
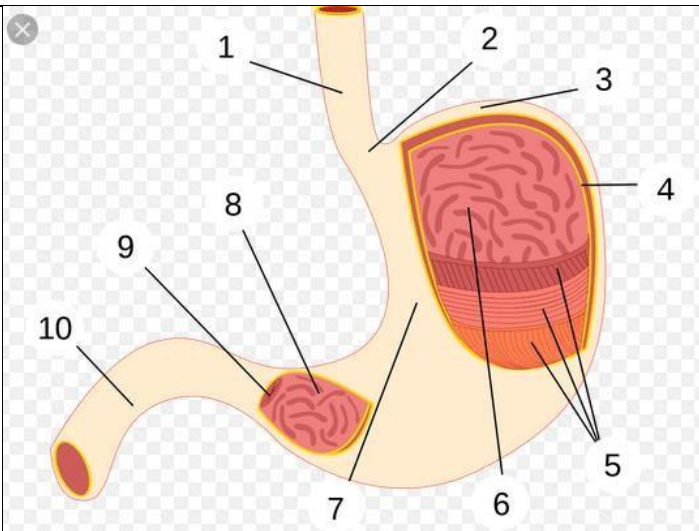


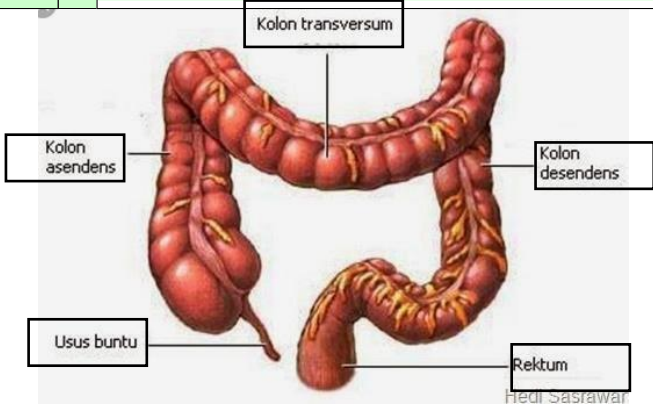
**WORKSHEETS (LEMBAR KERJA)**

<b>Mata Kuliah</b>	: <b>Anatomi</b>
<b>Materi</b>	: <b>Anatomi Digesti</b>
<b>NIM&gt;Nama Mahasiswa</b>	: <b>2110101075/IIS WAHYUNINGSIH</b>

No	Keterangan	Pembahasan
1	<ol style="list-style-type: none"> <li>1. Kelenjar ludah</li> <li>2. Parotis</li> <li>3. Submansibularis (Bawah Rahang)</li> <li>4. Sublingus (bawah lidah)</li> <li>5. Rongga mulut</li> <li>6. Amandel</li> <li>7. Lidah</li> <li>8. Esodafagus</li> <li>9. Pankreas</li> <li>10. Lambung</li> <li>11. Saluran pankreas</li> <li>12. Hati</li> <li>13. Kantung empedu</li> <li>14. Duodenum</li> <li>15. Saluran empedu</li> <li>16. Kalon</li> <li>17. Kalon transversum</li> <li>18. Kalon ascenden</li> <li>19. Kalon descenden</li> <li>20. Ileum</li> <li>21. Sekum</li> <li>22. Appendiks/umbai cacing</li> <li>23. Rektum / poros usus</li> <li>24. Anus</li> </ol>	



1. Esofagus
2. Kardia
3. Fundus
4. Selaput lender
5. Otot lapisan
6. Lambung mukosa
7. Tubuh perut
8. Pilorik antrum
9. Pilorus
10. Usus dua belas jari (duodenum)

No	Keterangan	Pembahasan
		 <p>The diagram illustrates the large intestine (colon) and its associated structures. The main components are labeled as follows:</p> <ul style="list-style-type: none"> <li><b>Kolon transversum</b>: The transverse colon, which runs horizontally across the upper abdomen.</li> <li><b>Kolon asendens</b>: The ascending colon, which runs vertically up the right side of the abdomen.</li> <li><b>Kolon desendens</b>: The descending colon, which runs vertically down the left side of the abdomen.</li> <li><b>Usus buntu</b>: The cecum, a large pouch at the junction of the ascending and transverse colons.</li> <li><b>Rektum</b>: The rectum, the terminal part of the large intestine that leads to the anus.</li> </ul> <p><small>Hedi Sasrawati</small></p>