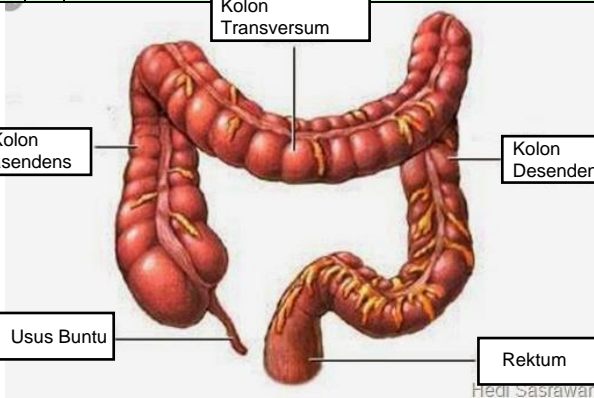


WORKSHEETS (LEMBAR KERJA)

Mata Kuliah	: Anatomi
Materi	: Anatomi Digesti
NIM>Nama Mahasiswa	: 2110101092/ Dinanda Dwi Setyorini

No	Keterangan	Pembahasan
1	<ol style="list-style-type: none"> 1. kelenjar ludah 2. patoris 3. submandibularis (rahang bawah) 4. sublingualis (bawah lidah) 	

No	Keterangan	Pembahasan
		 <p>The diagram illustrates the large intestine (colon) and its associated structures. The main components are labeled as follows:</p> <ul style="list-style-type: none"> Kolon Transversum: The horizontal part of the large intestine at the top. Kolon asendens: The vertical part of the large intestine on the right side. Kolon Desendens: The vertical part of the large intestine on the left side. Usus Buntu: The vermiform appendix, a small finger-like projection from the bottom of the cecum. Rektum: The final straight part of the large intestine, leading to the rectum. <p><small>Hedi Sasawari</small></p>