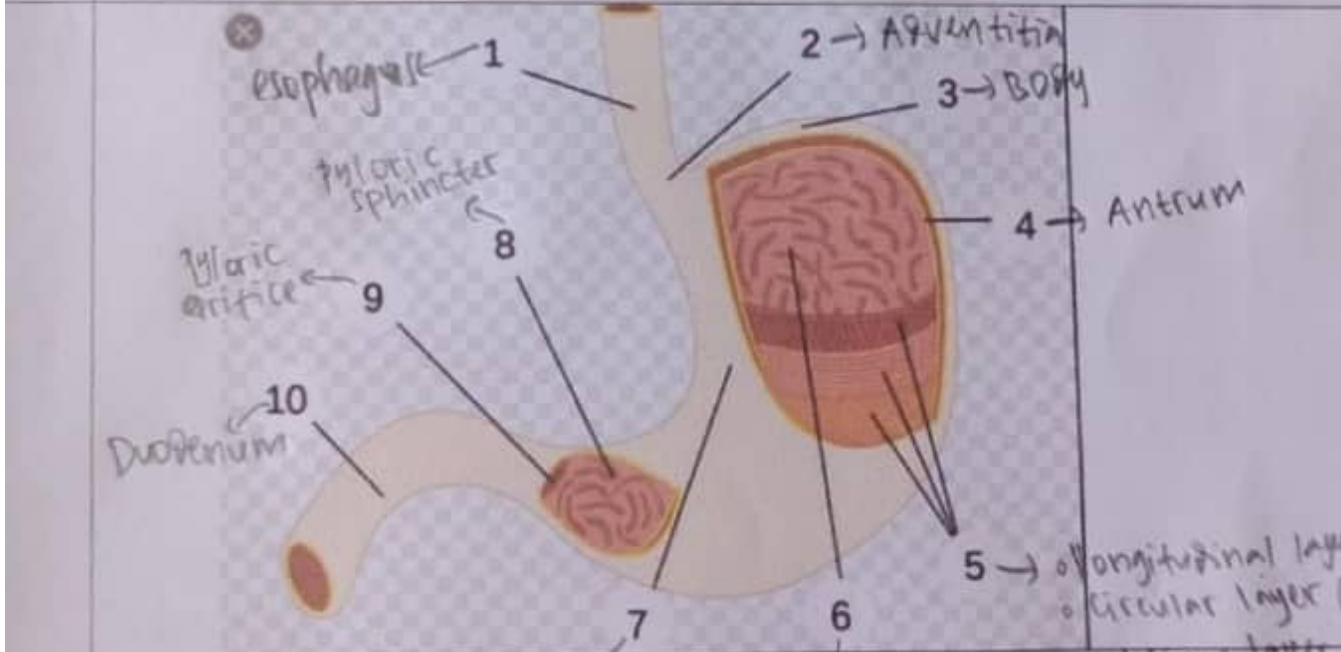
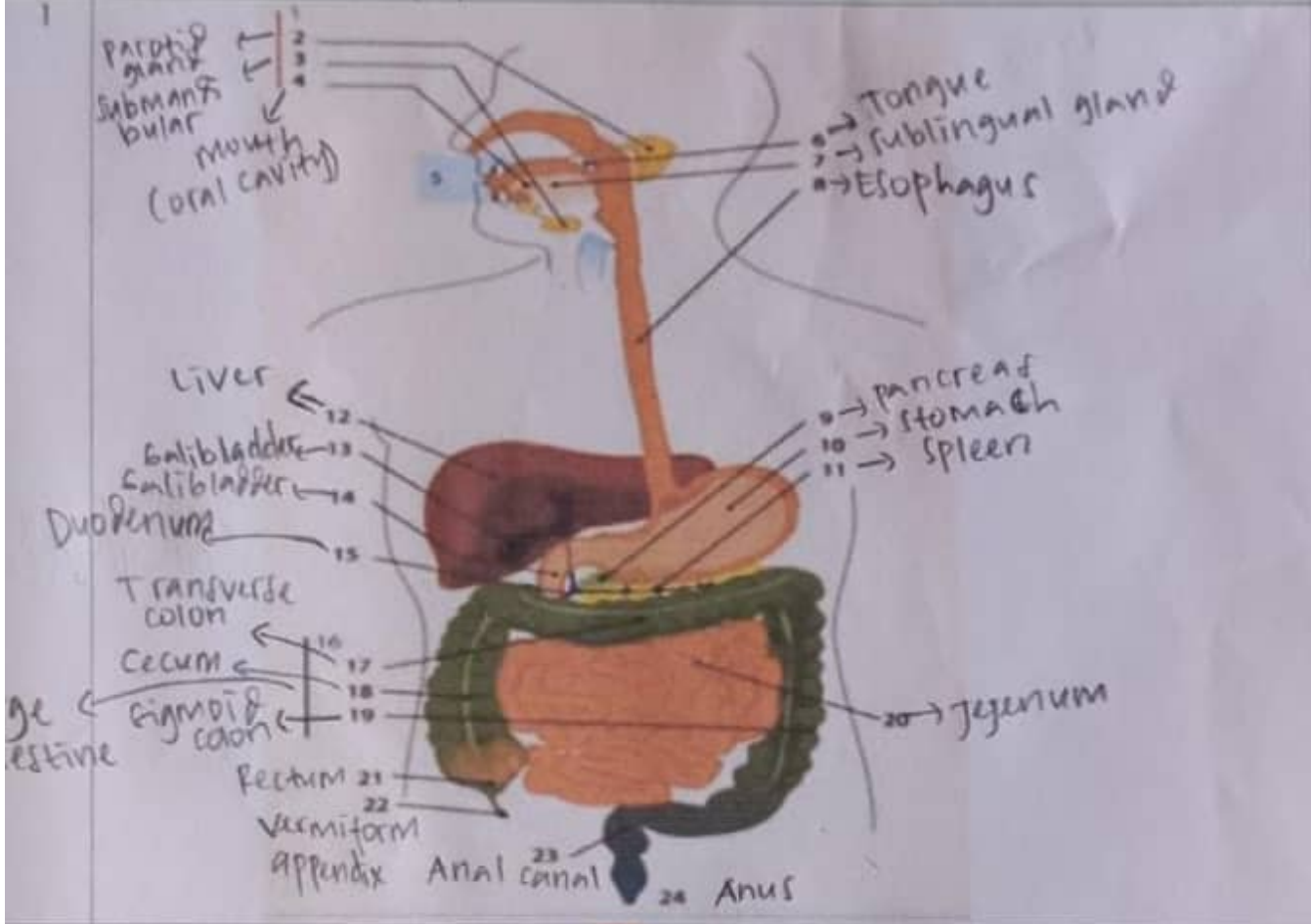
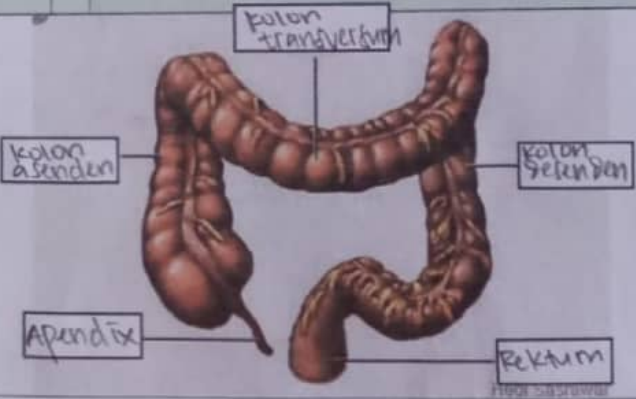


WORKSHEETS (LEMBAR KERJA)

Mata Kuliah	: Anatomi
Materi	: Anatomi Digesti
NIM>Nama Mahasiswa	: 2110101074 / Syifa Fauziah

No	Keterangan	Pembahasan
----	------------	------------



No	Keterangan	Pembahasan
		 <p>A hand-drawn anatomical diagram of the human large intestine (colon) and rectum. The diagram is colored in shades of brown and tan. It shows the characteristic shape of the large intestine, including the transverse colon at the top, the ascending colon on the right, the descending colon on the left, and the sigmoid colon at the bottom. A small appendix is shown extending from the junction of the ascending and transverse colons. The rectum is shown at the bottom right. Five labels in Indonesian are connected to the corresponding parts of the diagram by thin lines: 'Kolon transversum' at the top, 'Kolon asenden' on the right side, 'Apendix' at the bottom left, 'Kolon desenden' on the left side, and 'Rektum' at the bottom right.</p>