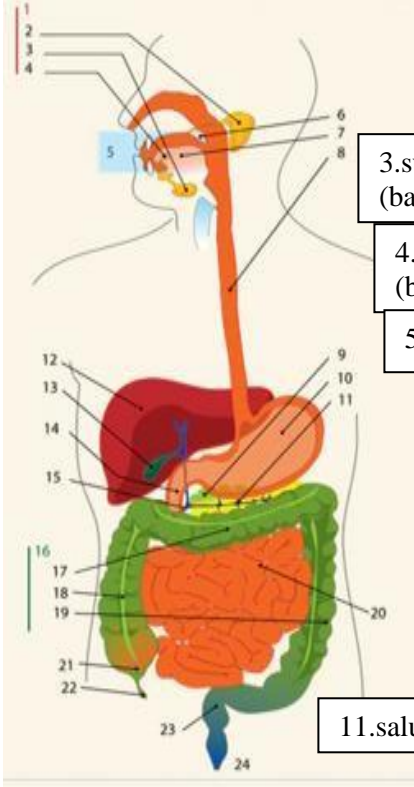
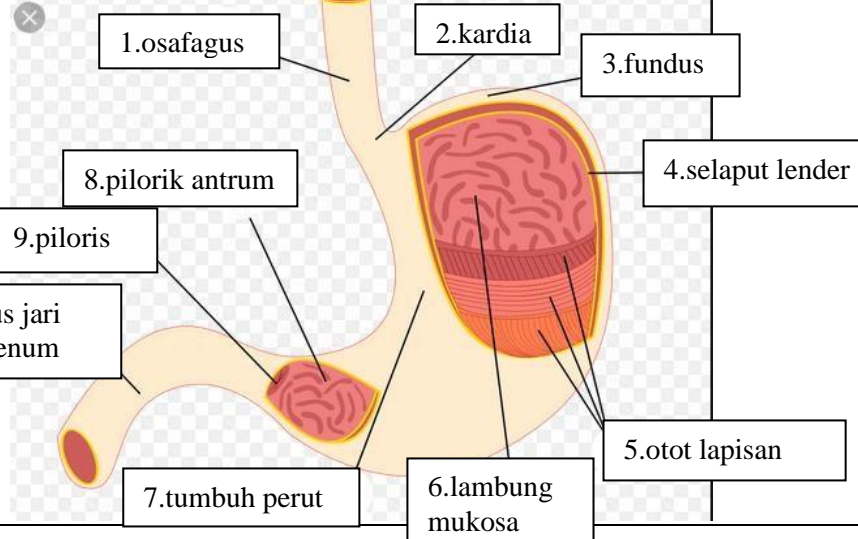


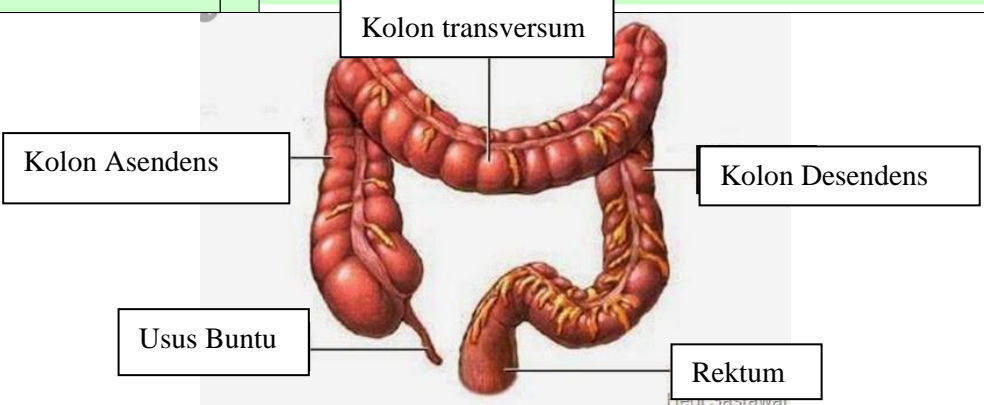
WORKSHEETS (LEMBAR KERJA)

Mata Kuliah	: Anatomi
Materi	: Anatomi Digesti
NIM>Nama Mahasiswa	: 2110101073/ Anjeli Sauri

No	Keterangan	Pembahasan
----	------------	------------

1		<div style="display: flex; flex-wrap: wrap;"> <div style="width: 33%; border: 1px solid black; padding: 2px; margin-bottom: 5px;">1.kelenjar</div> <div style="width: 33%; border: 1px solid black; padding: 2px; margin-bottom: 5px;">13.kantung empedu</div> <div style="width: 33%; border: 1px solid black; padding: 2px; margin-bottom: 5px;">2.parotis</div> <div style="width: 33%; border: 1px solid black; padding: 2px; margin-bottom: 5px;">14.duodenum</div> <div style="width: 33%; border: 1px solid black; padding: 2px; margin-bottom: 5px;">3.submandibularis (bawah rahang)</div> <div style="width: 33%; border: 1px solid black; padding: 2px; margin-bottom: 5px;">15.saluran empedu</div> <div style="width: 33%; border: 1px solid black; padding: 2px; margin-bottom: 5px;">4.sublingualis (bawah lidah)</div> <div style="width: 33%; border: 1px solid black; padding: 2px; margin-bottom: 5px;">16.kolon</div> <div style="width: 33%; border: 1px solid black; padding: 2px; margin-bottom: 5px;">5.rongga mulut</div> <div style="width: 33%; border: 1px solid black; padding: 2px; margin-bottom: 5px;">17.kolon transversum</div> <div style="width: 33%; border: 1px solid black; padding: 2px; margin-bottom: 5px;">6.amandel</div> <div style="width: 33%; border: 1px solid black; padding: 2px; margin-bottom: 5px;">18.kolon aacenden</div> <div style="width: 33%; border: 1px solid black; padding: 2px; margin-bottom: 5px;">7.lidah</div> <div style="width: 33%; border: 1px solid black; padding: 2px; margin-bottom: 5px;">19.kolon descendun</div> <div style="width: 33%; border: 1px solid black; padding: 2px; margin-bottom: 5px;">8.esofagus</div> <div style="width: 33%; border: 1px solid black; padding: 2px; margin-bottom: 5px;">20.ileum</div> <div style="width: 33%; border: 1px solid black; padding: 2px; margin-bottom: 5px;">9.pankreas</div> <div style="width: 33%; border: 1px solid black; padding: 2px; margin-bottom: 5px;">21.sekum</div> <div style="width: 33%; border: 1px solid black; padding: 2px; margin-bottom: 5px;">10.lambung</div> <div style="width: 33%; border: 1px solid black; padding: 2px; margin-bottom: 5px;">22.appendiks/poros usus</div> <div style="width: 33%; border: 1px solid black; padding: 2px; margin-bottom: 5px;">11.saluran pankreas</div> <div style="width: 33%; border: 1px solid black; padding: 2px; margin-bottom: 5px;">23.rektum/poros usus</div> <div style="width: 33%; border: 1px solid black; padding: 2px; margin-bottom: 5px;">12.hati</div> <div style="width: 33%; border: 1px solid black; padding: 2px; margin-bottom: 5px;">24.anus</div> </div>
---	--	---

	<div style="display: flex; flex-wrap: wrap;"> <div style="width: 33%; border: 1px solid black; padding: 2px; margin-bottom: 5px;">1.osafagus</div> <div style="width: 33%; border: 1px solid black; padding: 2px; margin-bottom: 5px;">2.kardia</div> <div style="width: 33%; border: 1px solid black; padding: 2px; margin-bottom: 5px;">3.fundus</div> <div style="width: 33%; border: 1px solid black; padding: 2px; margin-bottom: 5px;">4.selaput lender</div> <div style="width: 33%; border: 1px solid black; padding: 2px; margin-bottom: 5px;">5.otot lapisan</div> <div style="width: 33%; border: 1px solid black; padding: 2px; margin-bottom: 5px;">6.lambung mukosa</div> <div style="width: 33%; border: 1px solid black; padding: 2px; margin-bottom: 5px;">7.tumbuh perut</div> <div style="width: 33%; border: 1px solid black; padding: 2px; margin-bottom: 5px;">8.pilorik antrum</div> <div style="width: 33%; border: 1px solid black; padding: 2px; margin-bottom: 5px;">9.piloris</div> <div style="width: 33%; border: 1px solid black; padding: 2px; margin-bottom: 5px;">10.usus jari (duodenum)</div> </div>
--	--

No	Keterangan	Pembahasan
		 <p>The diagram illustrates the large intestine (colon) and its associated structures. The main components are labeled as follows:</p> <ul style="list-style-type: none"> Kolon transversum: The transverse colon, which is the upper horizontal part of the large intestine. Kolon Asendens: The ascending colon, the vertical part on the right side of the abdomen. Kolon Desendens: The descending colon, the vertical part on the left side of the abdomen. Usus Buntu: The vermiform appendix, a small finger-like projection from the junction of the ascending and transverse colons. Rektum: The rectum, the terminal part of the large intestine that leads to the anus.