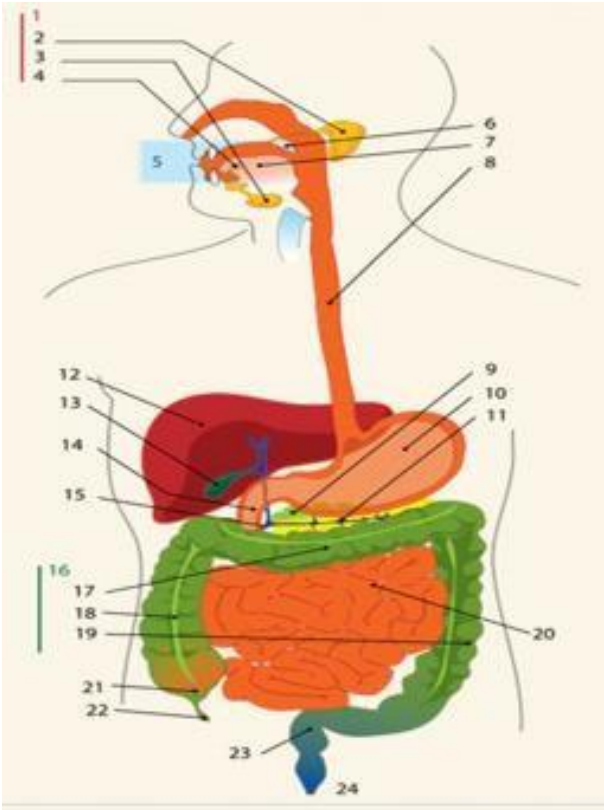
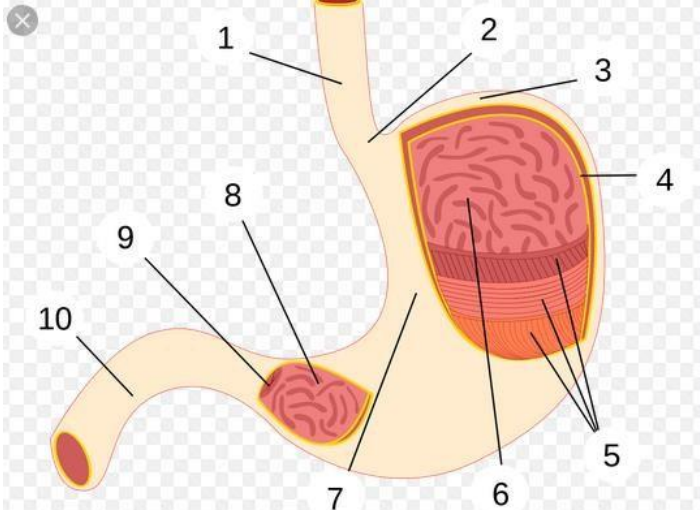


**WORKSHEETS (LEMBAR KERJA)**

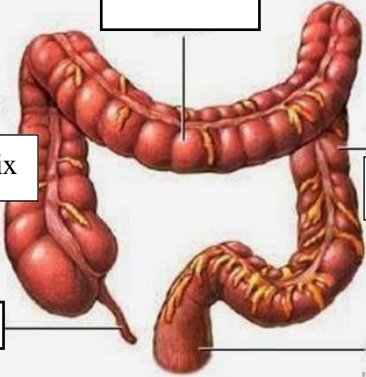
<b>Mata Kuliah</b>	: <b>Anatomi</b>
<b>Materi</b>	: <b>Anatomi Digesti</b>
<b>NIM&gt;Nama Mahasiswa</b>	: 2110101076/ Deya Devi Noventa Anggraini

No	Keterangan	Pembahasan
----	------------	------------

1		<ol style="list-style-type: none"> <li>1. Kelenjar ludah</li> <li>2. Parotis</li> <li>3. Submandibulasi (bawah rahang)</li> <li>4. Sublinguatis (bawah lidah)</li> <li>5. Rongga mulut</li> <li>6. Tekak/faring</li> <li>7. Lidah</li> <li>8. Kerongkongan esofagus</li> <li>9. Pancreas</li> <li>10. Lambung</li> <li>11. Saluran pancreas</li> <li>12. Hati</li> <li>13. Kantung empedu</li> <li>14. Usus dua belas jari</li> <li>15. Saluran empedu</li> <li>16. Usus tebal/kolon</li> <li>17. Kolon datar (tranverse)</li> <li>18. Kolon naik</li> <li>19. Kolon tuurun (descending)</li> <li>20. Usus penyerapan (ileum)</li> <li>21. Sekum</li> <li>22. Umbai cacing</li> <li>23. Poros usus/rectum</li> <li>24. anus</li> </ol>
---	--	--

	<ol style="list-style-type: none"> <li>1. Esofagus</li> <li>2. Kardia</li> <li>3. Fundus</li> <li>4. Selaput lendir</li> <li>5. Otot lapisan</li> <li>6. Lambung mukosa</li> <li>7. Tubuh perut</li> <li>8. Pilorik antrum</li> <li>9. Pylorus</li> <li>10. Usus dua belas jari</li> </ol>
--	--

Transverse  
colon

No	Keterangan	Pembahasan
	<p data-bbox="405 394 639 454">Kolon asendens</p> <p data-bbox="517 546 695 629">Appendix</p> <p data-bbox="541 725 663 775"></p>	<p data-bbox="759 409 922 459"></p>  <p data-bbox="1050 394 1299 454">Kolon desendens</p> <p data-bbox="1027 551 1203 645">Rectum</p> <p data-bbox="1027 752 1147 801"></p> <p data-bbox="1018 792 1150 815">Hedi Sasrawar</p>