

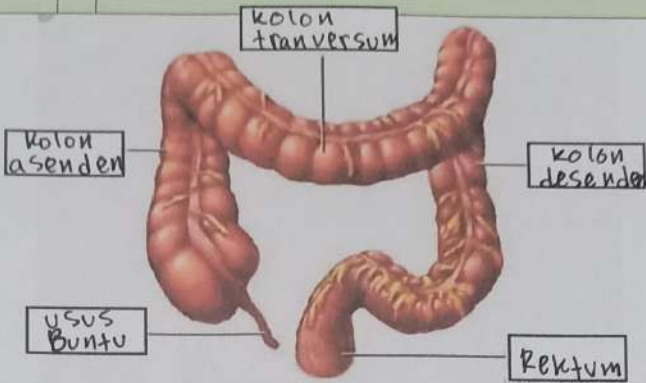
WORKSHEETS (LEMBAR KERJA)

Mata Kuliah	: Anatomi
Materi	: Anatomi Digesti
NIM>Nama Mahasiswa	: 2110101094 Annisa Adzakyyatul

No	Keterangan	Pembahasan
----	------------	------------

<p>1</p> <p>kelenjar ludah</p> <p>3 Submandibularis</p> <p>4. sublingualis</p> <p>17. kolon transversum</p> <p>18. kolon asenden</p> <p>19. kolon desenden</p> <p>21 sekum</p> <p>22. Appendix</p>		<p>6 Amandel</p> <p>7 lidah</p> <p>8 kerongkongan (esotagus)</p> <p>9 Pancreas</p> <p>10 gaster</p> <p>11 saluran pankreas</p> <p>20 usus halus (ileum)</p> <p>23 Rektum</p> <p>24 Anus</p>
--	--	---

<p>10 usus 12 jari (duodenum)</p> <p>Tubuh perut</p> <p>7</p>		<p>2 cardia</p> <p>3 Fundus</p> <p>4 selaput lendir</p> <p>5 three layers of smooth muscle</p> <p>6 lambung mukosa</p>
---	--	--

No	Keterangan	Pembahasan
		 <p>The diagram illustrates the large intestine (colon) and its associated structures. It is divided into five main sections, each labeled with a box and a line pointing to the corresponding part of the organ:</p> <ul style="list-style-type: none"><li><b>Kolon asenden</b>: The ascending colon, located on the right side of the abdomen.</li><li><b>Kolon transversum</b>: The transverse colon, located across the upper abdomen.</li><li><b>Kolon desenden</b>: The descending colon, located on the left side of the abdomen.</li><li><b>Usus Buntu</b>: The vermiform appendix, a small finger-like projection at the end of the cecum.</li><li><b>Rektum</b>: The rectum, the final part of the large intestine that leads to the anus.</li></ul>