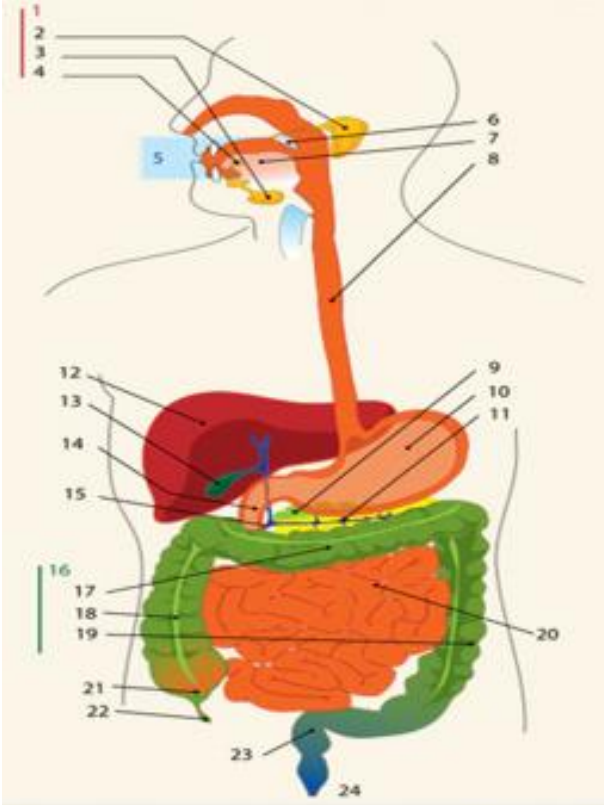
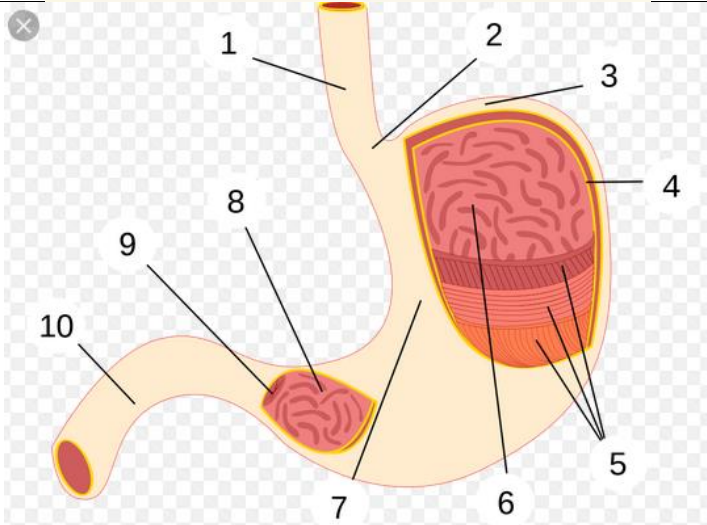
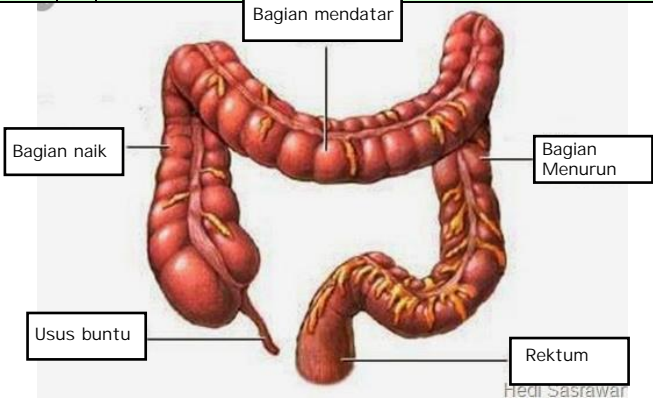


WORKSHEETS (LEMBAR KERJA)

Mata Kuliah	: Anatomi
Materi	: Anatomi Digesti
NIM>Nama Mahasiswa	: 2110101087/Nabila Dela Alifa

No	Keterangan	Pembahasan
1		<p>Sistem pencernaan</p> <ol style="list-style-type: none"> 1. Kelenjar ludah 2. Parotis 3. submandibularis(bawah rahang) 4. sublingualis(bawah lidah) 5. Rongga mulut 6. Amandel 7. Lidah 8. Esofagus 9. Pankreas 10. Lambung 11. Saluran pankreas 12. Hati 13. Kantung empedu 14. Duodenum 15. Saluran empedu 16. Kolon 17. Kolon transversum 18. Kolon ascenden 19. Kolon descenden 20. Ileum 21. Sekum 22. Appendiks/ umbai cacing 23. Rektum/ poros usus 24. Anus
		<p>Lambung</p> <ol style="list-style-type: none"> 1. Esofagus 2. Kardia 3. Fundus 4. Selaput lendir 5. Otot lapisan 6. Lambung mukosa 7. Tubuh perut 8

No	Keterangan	Pembahasan
		 <p>The diagram illustrates the large intestine (colon) with the following labeled parts:</p> <ul style="list-style-type: none"> Bagian mendatar: The transverse colon, the upper horizontal part. Bagian naik: The ascending colon, the right vertical part. Bagian Menurun: The descending colon, the left vertical part. Usus buntu: The cecum, the large pouch at the start of the large intestine. Rektum: The rectum, the lower part of the large intestine leading to the anus. <p><small>Hedi Sasawari</small></p>