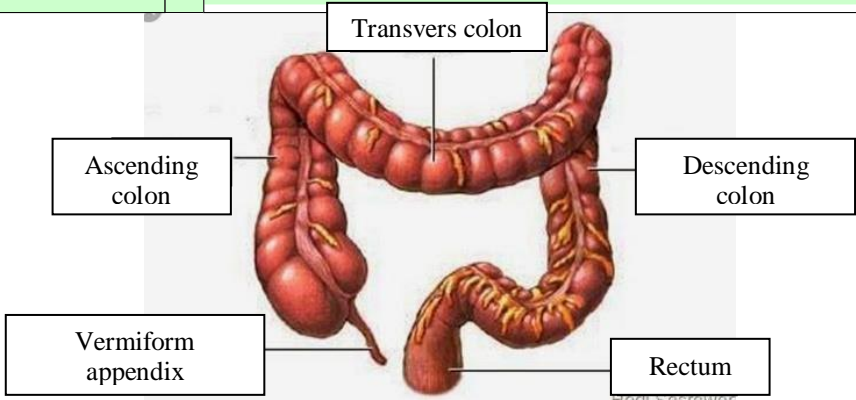


WORKSHEETS (LEMBAR KERJA)

Mata Kuliah	: Anatomi
Materi	: Anatomi Digesti
NIM>Nama Mahasiswa	: 2110101110/Cici Liara Septi

No	Keterangan	Pembahasan
	1. salivari glands	
	2. Parotid	
	3. Sublingual	
	4. submandibular	
	5. oral cavity	6. soft palate 7. tongue 8. Esophagus
	12. Liver	9. pancreas
	13. Gallbladder	10. Stomach
	14. Duodenum	11. pancreatic duct
	15. common bile duct	
	17. transvers colon	Small intestine
	18. taenia coli	
	19. sigmoid colon	
	21. cecum	
	22. Appendix	
	16. usus besar	Rectum 24. Anus

No	Keterangan	Pembahasan
		 <p>The diagram illustrates the large intestine (colon) and its associated structures. The main components are labeled as follows:</p> <ul style="list-style-type: none"> Ascending colon: The upper right portion of the large intestine. Transvers colon: The horizontal upper portion of the large intestine. Descending colon: The lower right portion of the large intestine. Vermiform appendix: A small, finger-like projection from the junction of the ascending and transverse colons. Rectum: The terminal part of the large intestine, leading to the anus. <p><small>Hedi Sasrawar</small></p>