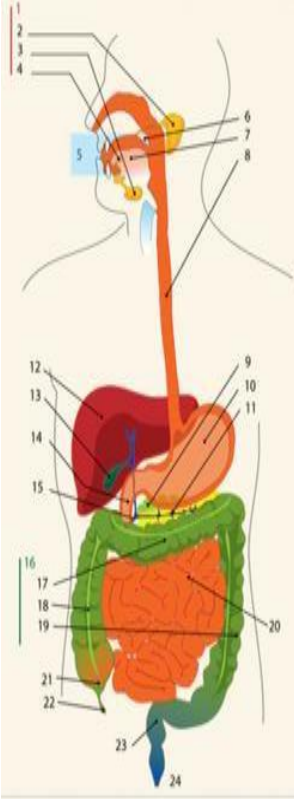
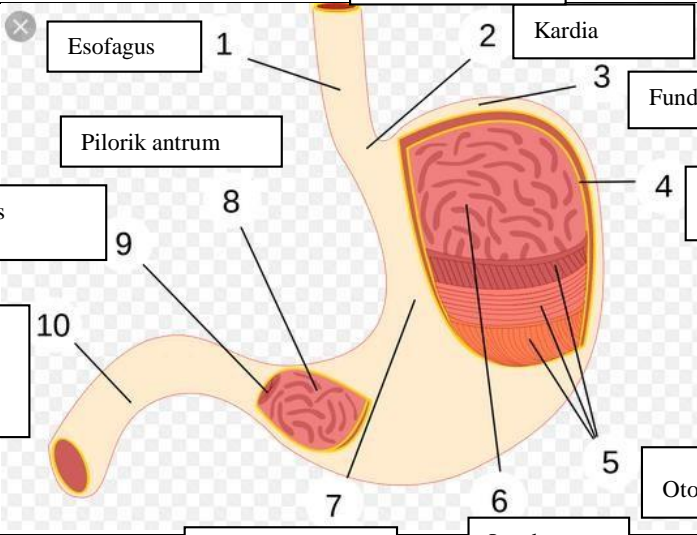
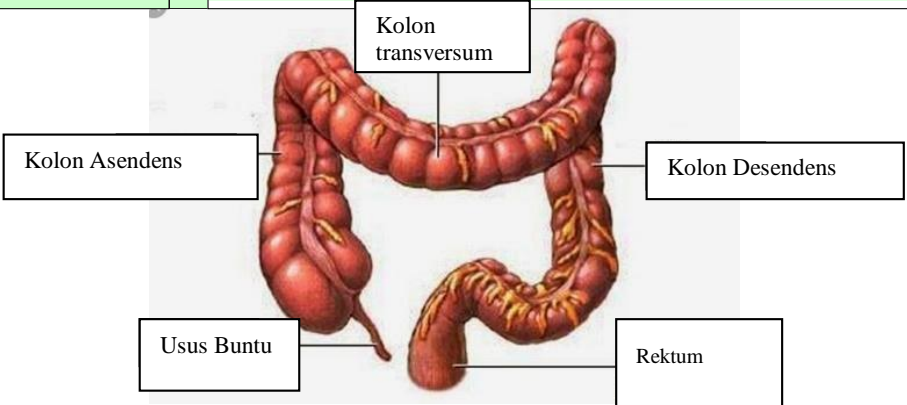


**WORKSHEETS (LEMBAR KERJA)**

|                              |  |
|------------------------------|--|
| <b>Mata Kuliah</b>           | : <b>Anatomi</b>                           |
| <b>Materi</b>                | : <b>Anatomi Digesti</b>                   |
| <b>NIM&gt;Nama Mahasiswa</b> | : <b>2110101121/Adinda Helminiya Putri</b> |

| No                               | Keterangan   | Pembahasan   |                  |                  |           |                  |                                  |                   |                              |          |                |                            |                   |                   |         |                    |            |          |            |          |           |                           |                     |                      |         |         |
|----------------------------------|--|--|------------------|------------------|-----------|------------------|----------------------------------|-------------------|------------------------------|----------|----------------|----------------------------|-------------------|-------------------|---------|--------------------|------------|----------|------------|----------|-----------|---------------------------|---------------------|----------------------|---------|---------|
| 1                                |    | <table border="0"> <tr> <td>1.Kelenjar Ludah</td> <td>13.Kantun Empedu</td> </tr> <tr> <td>2.Parotis</td> <td>14.Duodenum</td> </tr> <tr> <td>3.Submandibularis (bawah rahang)</td> <td>15.Saluran Empedu</td> </tr> <tr> <td>4.Sublingualis (bawah lidah)</td> <td>16.Kolon</td> </tr> <tr> <td>5.Rongga mulut</td> <td>17.Kolon transversum</td> </tr> <tr> <td>6.Amandel</td> <td>18.Kolon Aacenden</td> </tr> <tr> <td>7.Lidah</td> <td>19.Kolon Descenden</td> </tr> <tr> <td>8.Esofagus</td> <td>20.Ileum</td> </tr> <tr> <td>9.Pankreas</td> <td>21.Sekum</td> </tr> <tr> <td>10.Lambng</td> <td>22.Appendiks/Umbai cacing</td> </tr> <tr> <td>11.Saluran pankreas</td> <td>23.Rektum/Poros usus</td> </tr> <tr> <td>12.Hati</td> <td>24.Anus</td> </tr> </table> | 1.Kelenjar Ludah | 13.Kantun Empedu | 2.Parotis | 14.Duodenum      | 3.Submandibularis (bawah rahang) | 15.Saluran Empedu | 4.Sublingualis (bawah lidah) | 16.Kolon | 5.Rongga mulut | 17.Kolon transversum       | 6.Amandel         | 18.Kolon Aacenden | 7.Lidah | 19.Kolon Descenden | 8.Esofagus | 20.Ileum | 9.Pankreas | 21.Sekum | 10.Lambng | 22.Appendiks/Umbai cacing | 11.Saluran pankreas | 23.Rektum/Poros usus | 12.Hati | 24.Anus |
| 1.Kelenjar Ludah                 | 13.Kantun Empedu   |  |                  |                  |           |                  |                                  |                   |                              |          |                |                            |                   |                   |         |                    |            |          |            |          |           |                           |                     |                      |         |         |
| 2.Parotis                        | 14.Duodenum  |  |                  |                  |           |                  |                                  |                   |                              |          |                |                            |                   |                   |         |                    |            |          |            |          |           |                           |                     |                      |         |         |
| 3.Submandibularis (bawah rahang) | 15.Saluran Empedu  |  |                  |                  |           |                  |                                  |                   |                              |          |                |                            |                   |                   |         |                    |            |          |            |          |           |                           |                     |                      |         |         |
| 4.Sublingualis (bawah lidah)     | 16.Kolon   |  |                  |                  |           |                  |                                  |                   |                              |          |                |                            |                   |                   |         |                    |            |          |            |          |           |                           |                     |                      |         |         |
| 5.Rongga mulut                   | 17.Kolon transversum   |  |                  |                  |           |                  |                                  |                   |                              |          |                |                            |                   |                   |         |                    |            |          |            |          |           |                           |                     |                      |         |         |
| 6.Amandel                        | 18.Kolon Aacenden  |  |                  |                  |           |                  |                                  |                   |                              |          |                |                            |                   |                   |         |                    |            |          |            |          |           |                           |                     |                      |         |         |
| 7.Lidah                          | 19.Kolon Descenden   |  |                  |                  |           |                  |                                  |                   |                              |          |                |                            |                   |                   |         |                    |            |          |            |          |           |                           |                     |                      |         |         |
| 8.Esofagus                       | 20.Ileum   |  |                  |                  |           |                  |                                  |                   |                              |          |                |                            |                   |                   |         |                    |            |          |            |          |           |                           |                     |                      |         |         |
| 9.Pankreas                       | 21.Sekum   |  |                  |                  |           |                  |                                  |                   |                              |          |                |                            |                   |                   |         |                    |            |          |            |          |           |                           |                     |                      |         |         |
| 10.Lambng                        | 22.Appendiks/Umbai cacing  |  |                  |                  |           |                  |                                  |                   |                              |          |                |                            |                   |                   |         |                    |            |          |            |          |           |                           |                     |                      |         |         |
| 11.Saluran pankreas              | 23.Rektum/Poros usus   |  |                  |                  |           |                  |                                  |                   |                              |          |                |                            |                   |                   |         |                    |            |          |            |          |           |                           |                     |                      |         |         |
| 12.Hati                          | 24.Anus  |  |                  |                  |           |                  |                                  |                   |                              |          |                |                            |                   |                   |         |                    |            |          |            |          |           |                           |                     |                      |         |         |
|                                  |  | <table border="0"> <tr> <td>1 Esofagus</td> <td>2 Kardia</td> </tr> <tr> <td>3 Fundus</td> <td>4 Selaput Lender</td> </tr> <tr> <td>5 Otot Lapisan</td> <td>6 Lambung Mukosa</td> </tr> <tr> <td>7 Tumbuh perut</td> <td>8</td> </tr> <tr> <td>9 Pylorus</td> <td>10 Usus 12 jari (duodenum)</td> </tr> <tr> <td>11 Pyloric antrum</td> <td></td> </tr> </table>   | 1 Esofagus       | 2 Kardia         | 3 Fundus  | 4 Selaput Lender | 5 Otot Lapisan                   | 6 Lambung Mukosa  | 7 Tumbuh perut               | 8        | 9 Pylorus      | 10 Usus 12 jari (duodenum) | 11 Pyloric antrum |                   |         |                    |            |          |            |          |           |                           |                     |                      |         |         |
| 1 Esofagus                       | 2 Kardia   |  |                  |                  |           |                  |                                  |                   |                              |          |                |                            |                   |                   |         |                    |            |          |            |          |           |                           |                     |                      |         |         |
| 3 Fundus                         | 4 Selaput Lender   |  |                  |                  |           |                  |                                  |                   |                              |          |                |                            |                   |                   |         |                    |            |          |            |          |           |                           |                     |                      |         |         |
| 5 Otot Lapisan                   | 6 Lambung Mukosa   |  |                  |                  |           |                  |                                  |                   |                              |          |                |                            |                   |                   |         |                    |            |          |            |          |           |                           |                     |                      |         |         |
| 7 Tumbuh perut                   | 8  |  |                  |                  |           |                  |                                  |                   |                              |          |                |                            |                   |                   |         |                    |            |          |            |          |           |                           |                     |                      |         |         |
| 9 Pylorus                        | 10 Usus 12 jari (duodenum)   |  |                  |                  |           |                  |                                  |                   |                              |          |                |                            |                   |                   |         |                    |            |          |            |          |           |                           |                     |                      |         |         |
| 11 Pyloric antrum                |  |  |                  |                  |           |                  |                                  |                   |                              |          |                |                            |                   |                   |         |                    |            |          |            |          |           |                           |                     |                      |         |         |

| No | Keterangan | Pembahasan   |
|----|------------|--|
|    |            |  <p>The diagram illustrates the large intestine (colon) and its associated structures. The main components are labeled as follows:</p> <ul style="list-style-type: none"> <li><b>Kolon Asendens</b>: The ascending colon, located on the right side of the abdomen.</li> <li><b>Kolon transversum</b>: The transverse colon, located across the upper abdomen.</li> <li><b>Kolon Desendens</b>: The descending colon, located on the left side of the abdomen.</li> <li><b>Usus Buntu</b>: The cecum, a pouch-like structure at the junction of the ascending and transverse colons.</li> <li><b>Rektum</b>: The rectum, the terminal part of the large intestine that leads to the anus.</li> </ul> |