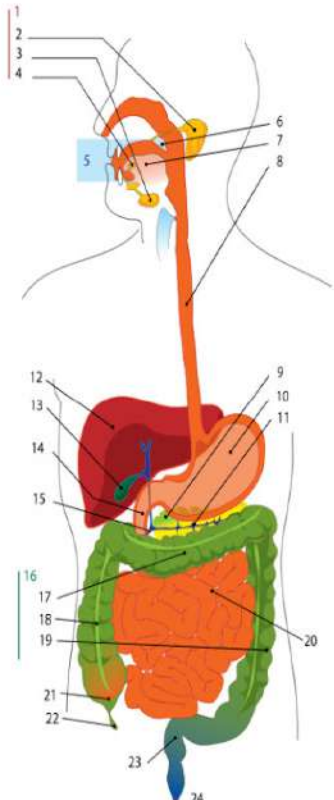
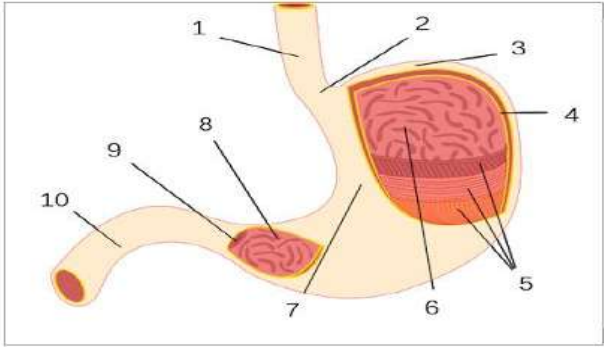
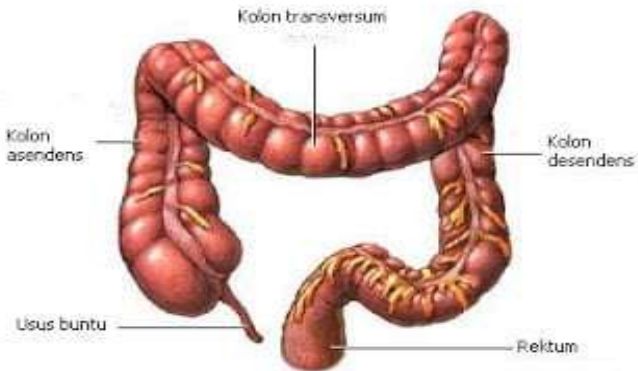


**WORKSHEETS (LEMBAR KERJA)**

<b>Mata Kuliah</b>	<b>: Anatomi</b>
<b>Materi</b>	<b>: Anatomi Digesti</b>
<b>NIM&gt;Nama Mahasiswa</b>	<b>: Sani Ulfa Widiyana 2110101117</b>

No	Keterangan	Pembahasan
1		<p><b>Diagram sistem pencernaan</b></p> <ol style="list-style-type: none"> <li>1. Kelenjar ludah</li> <li>2. Parotis</li> <li>3. Submandibularis (bawah rahang)</li> <li>4. Sublingualis (bawah lidah)</li> <li>5. Rongga mulut</li> <li>6. Amandel</li> <li>7. Lidah</li> <li>8. Esofagus</li> <li>9. Pankreas</li> <li>10. Lambung</li> <li>11. Saluran pankreas</li> <li>12. Hati</li> <li>13. Kantung empedu</li> <li>14. duodenum</li> <li>15. Saluran empedu</li> <li>16. Kolon</li> <li>17. Kolon transversum</li> <li>18. Kolon ascenden</li> <li>19. Kolon descenden</li> <li>20. Ileum</li> <li>21. Sekum</li> <li>22. Appendiks/Umbai cacang</li> <li>23. Rektum/Poros usus</li> <li>24. Anus</li> </ol>
		<ol style="list-style-type: none"> <li>1. Esofagus</li> <li>2. Kardia</li> <li>3. Fundus</li> <li>4. Selaput lender</li> <li>5. Otot lapisan</li> <li>6. Lambung mukosa</li> <li>7. Tubuh perut</li> <li>8. Pilorik antrum</li> <li>9. Pylorus</li> <li>10. Usus dua belas jari</li> </ol>

No	Keterangan	Pembahasan
		 <p>The diagram illustrates the large intestine (colon) and its associated structures. The main components are labeled as follows:</p> <ul style="list-style-type: none"><li><b>Kolon transversum</b>: The horizontal section of the large intestine at the top.</li><li><b>Kolon asendens</b>: The vertical section on the right side that ascends.</li><li><b>Kolon desendens</b>: The vertical section on the left side that descends.</li><li><b>Lisus buntu</b>: The cecum, a pouch-like structure at the bottom left where the large intestine begins.</li><li><b>Rektum</b>: The terminal part of the large intestine at the bottom right.</li></ul>