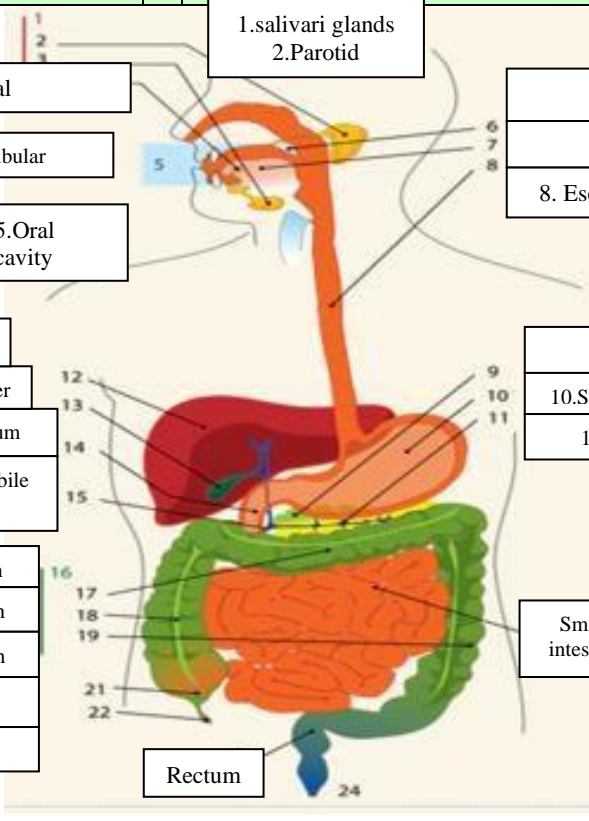
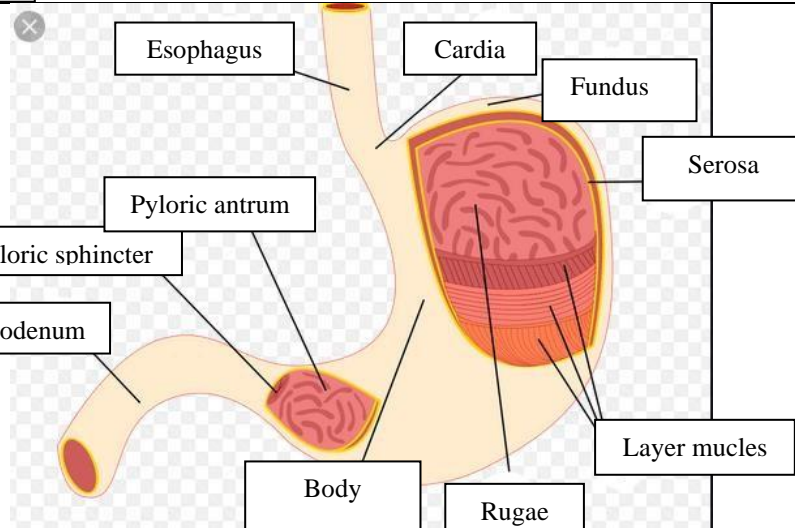
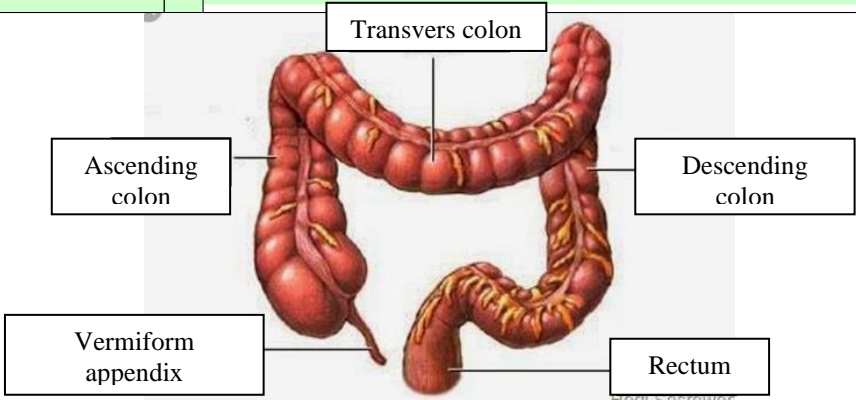


WORKSHEETS (LEMBAR KERJA)

Mata Kuliah	: Anatomi
Materi	: Anatomi Digesti
NIM>Nama Mahasiswa	: 2110101115/SHOFIYATUL AZIZAH

No	Keterangan	Pembahasan
1	 <p>1. salivari glands 2. Parotid 3. sublingual 4. submandibular 5. Oral cavity 12. Liver 13. Gallbladder 14. Duodenum 15. common bile duct 17. transverse colon 18. Ascending colon 19. Descending colon 21. cecum 22. Appendix 16. Colon</p>	<p>6. soft palate 7. tongue 8. Esophagus 9. pancreas 10. Stomach 11. pancreatic duct Small intestine Rectum</p>
	 <p>Esophagus Cardia Fundus Serosa Pyloric antrum Pyloric sphincter Duodenum Body Rugae Layer mucleus</p>	

No	Keterangan	Pembahasan
		 <p>The diagram illustrates the large intestine (colon) and its associated structures. The main components are labeled as follows:</p> <ul style="list-style-type: none"> Transvers colon: The horizontal part of the large intestine at the top. Ascending colon: The part of the large intestine that rises on the right side. Descending colon: The part of the large intestine that descends on the left side. Vermiform appendix: A small, finger-like projection from the junction of the ascending and transverse colons. Rectum: The final straight part of the large intestine, leading to the anus. <p><small>Hedi Sasrawar</small></p>