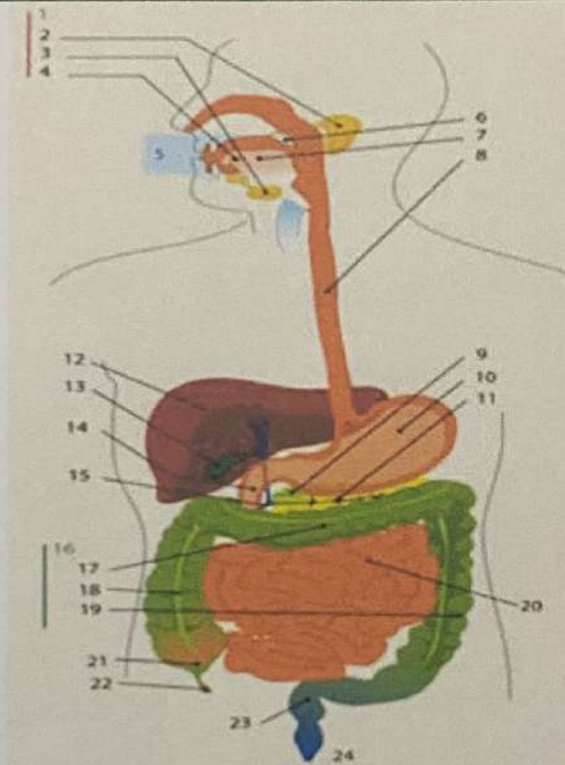
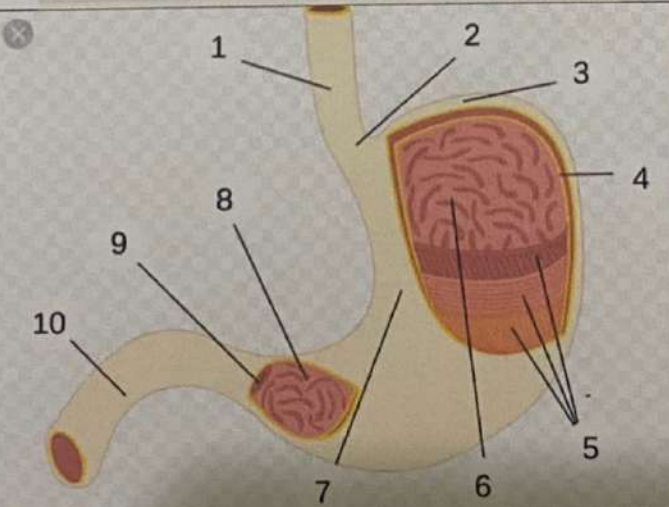
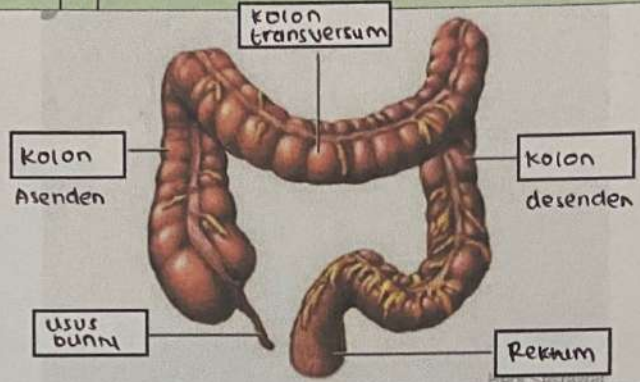


WORKSHEETS (LEMBAR KERJA)

Mata Kuliah	: Anatomi
Materi	: Anatomi Digesti
NIM>Nama Mahasiswa	: 2110101071 / Putri Ratna Sari Dewi

No	Keterangan	Pembahasan
1		<ol style="list-style-type: none"> 1. kelenjar ludah 2. parotis 3. submandibularis (bawah rahang) 4. sublingualis (bawah lidah) 5. rongga mulut 6. amandel 7. lidah 8. esofagus 9. pankreas 10. lambung 11. saluran pankreas 12. hati 13. kantong empedu 14. duodenum 15. saluran empedu 16. kolon 17. kolon transversum 18. kolon ascenden 19. kolon descenden 20. ileum 21. sekum 22. Appendix / umbil cacing 23. Rektum / poros usus 24. Anus
		<ol style="list-style-type: none"> 1. esofagus 2. Kardia 3. Fundus 4. selaput lender 5. Ordi lapisan 6. lambung mukosa 7. tubuh perut 8. Pilonik antrum 9. Pilonus 10. usus dua belas jari (duodenum)

No	Keterangan	Pembahasan
		 <p>The diagram illustrates the large intestine (colon) and its associated parts. The labels are as follows:</p> <ul style="list-style-type: none"> Kolon transversum: The transverse colon, the upper horizontal part of the large intestine. Kolon Asenden: The ascending colon, the vertical part on the right side. Usus buntu: The cecum, the large pouch at the junction of the small and large intestines. Kolon desenden: The descending colon, the vertical part on the left side. Rektum: The rectum, the final part of the large intestine leading to the anus.