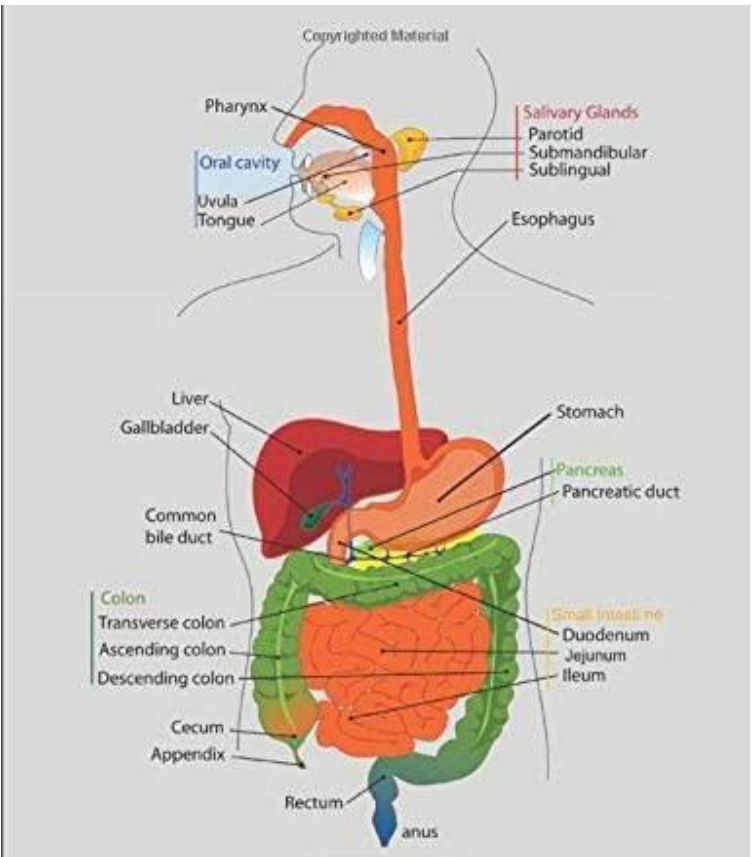
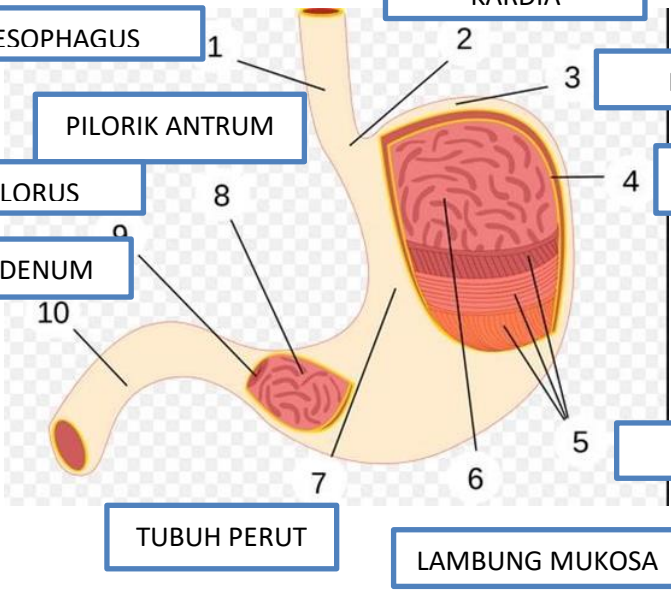
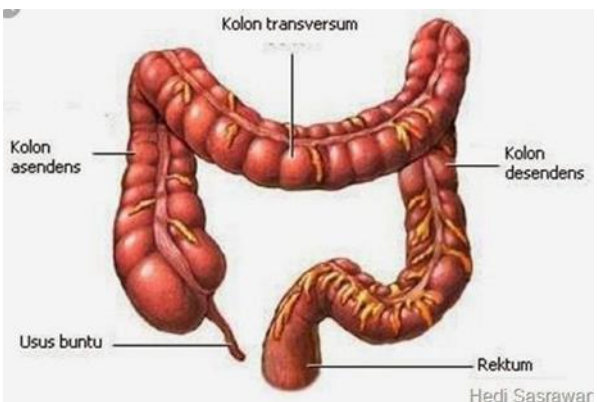


WORKSHEETS (LEMBAR KERJA)

Mata Kuliah : Anatomi
Materi : Anatomi Digesti
NIM>Nama Mahasiswa : 2110101070 / REGITA RIZQIANA RIFANINGTYS
CHABIB

NO	KETERANGAN	PEMBAHASAN
1.	 <p>The diagram illustrates the human digestive system. At the top, the oral cavity is shown with the tongue and uvula. The pharynx leads to the esophagus. Salivary glands (parotid, submandibular, and sublingual) are shown near the mouth. The stomach is connected to the esophagus. The liver and gallbladder are shown with the common bile duct. The pancreas and its duct are also labeled. The small intestine consists of the duodenum, jejunum, and ileum. The large intestine (colon) includes the transverse, ascending, and descending colon, along with the cecum and appendix. The rectum leads to the anus.</p>	

<p>2.</p>	 <p>ESOPHAGUS 1</p> <p>PILORIK ANTRUM</p> <p>PILORUS</p> <p>DUODENUM</p> <p>10</p> <p>8</p> <p>7</p> <p>6</p> <p>5</p> <p>4</p> <p>3</p> <p>2</p> <p>1</p> <p>KARDIA</p> <p>FUNDUS</p> <p>SELAPUT LENDIR</p> <p>OTOT LAPISAN LAMBUNG</p> <p>TUBUH PERUT</p> <p>LAMBUNG MUKOSA</p>	
<p>3.</p>	 <p>Kolon transversum</p> <p>Kolon asendens</p> <p>Kolon desendens</p> <p>Usus buntu</p> <p>Rektum</p> <p>Hedi Sasrawar</p>	