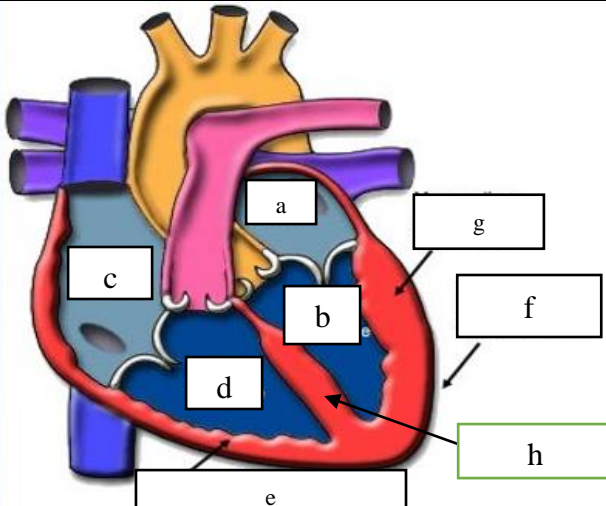
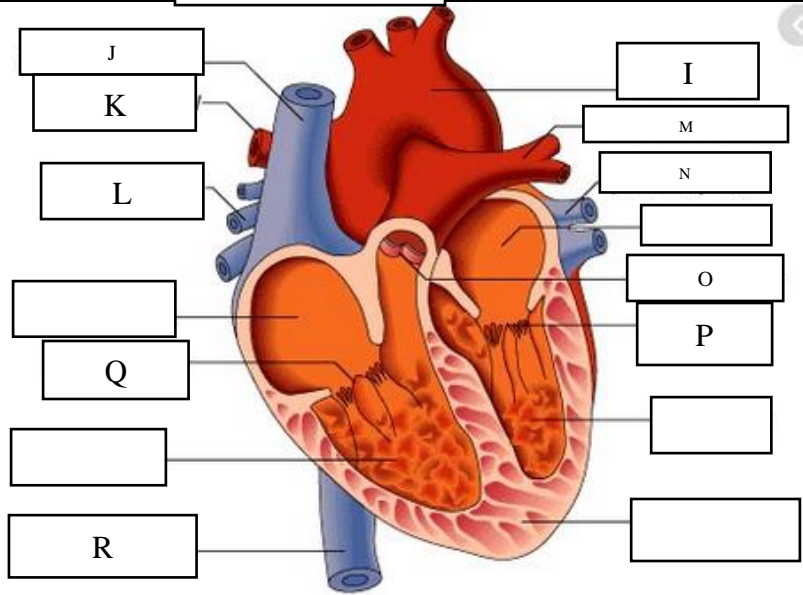
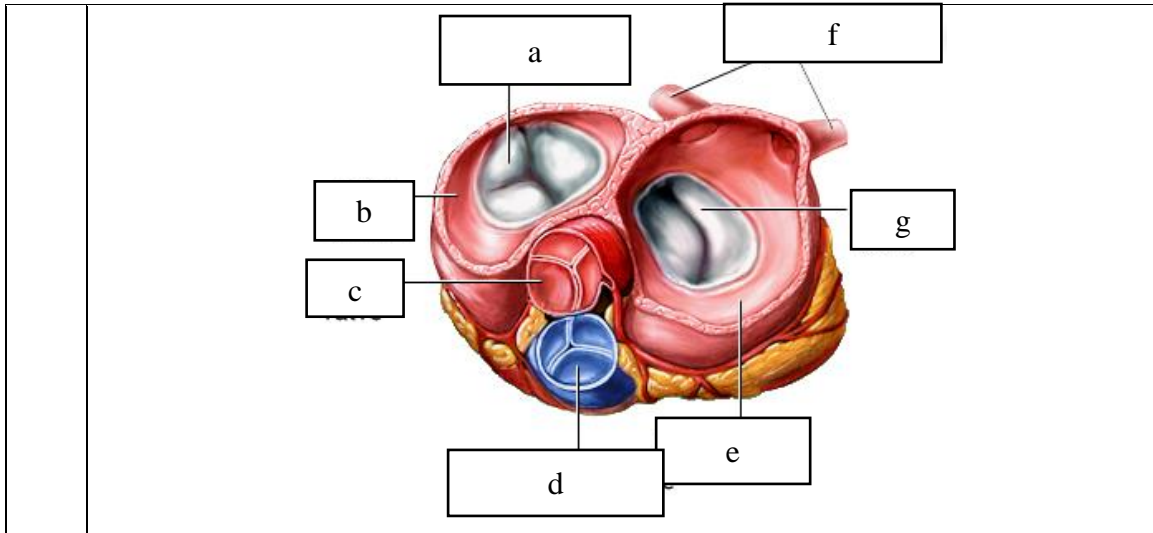


WORKSHEETS (LEMBAR KERJA)

Mata Kuliah	: Anatomi
Materi	: Anatomi Cardiovaskuler
NIM>Nama Mahasiswa	:

No	Keterangan	Pembahasan
1		
		



WORKSHEETS (LEMBAR KERJA)

Mata Kuliah	:	Anatomi
Materi	:	Anatomi Respirasi
NIM>Nama Mahasiswa	:	

No	Keterangan	Pembahasan
1	<p>An anatomical diagram of the human respiratory system. The diagram shows the trachea, bronchi, and lungs. It is labeled with letters a through i in white boxes. 'a' points to the larynx, 'b' to the pharynx, 'c' to the epiglottis, 'd' to the trachea, 'e' to the bronchus, 'f' to the bronchiole, 'g' to the alveolus, 'h' to the pleural cavity, and 'i' to the diaphragm.</p>	

No	Keterangan	Pembahasan
		