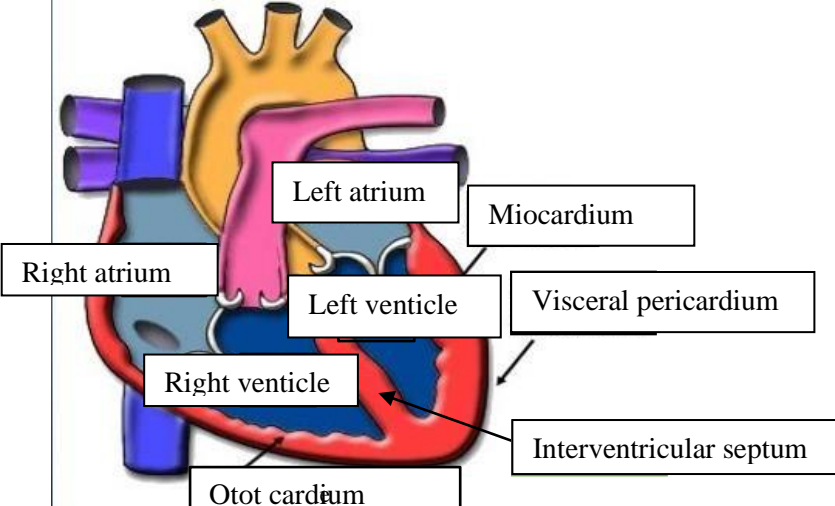
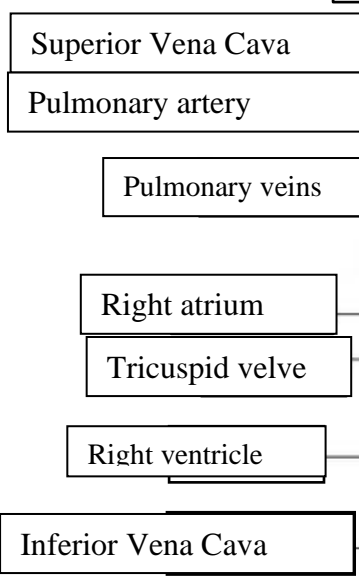
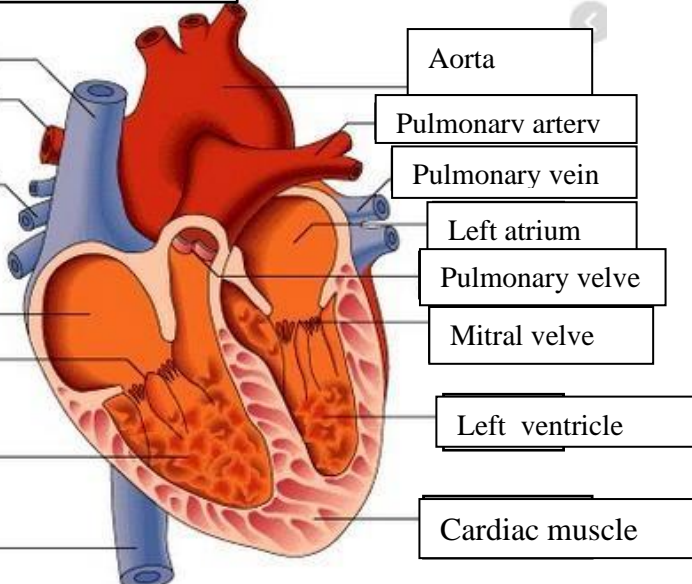
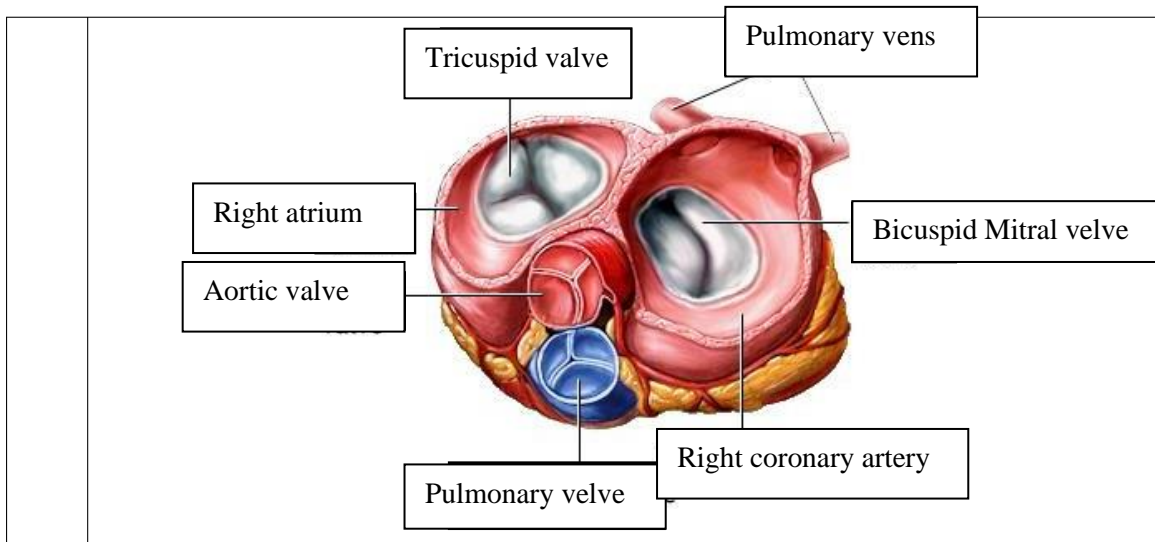


WORKSHEETS (LEMBAR KERJA)

Mata Kuliah	: Anatomi
Materi	: Anatomi Cardiovaskuler
NIM>Nama Mahasiswa	: 2110101031/ Bisyarotul Walidah

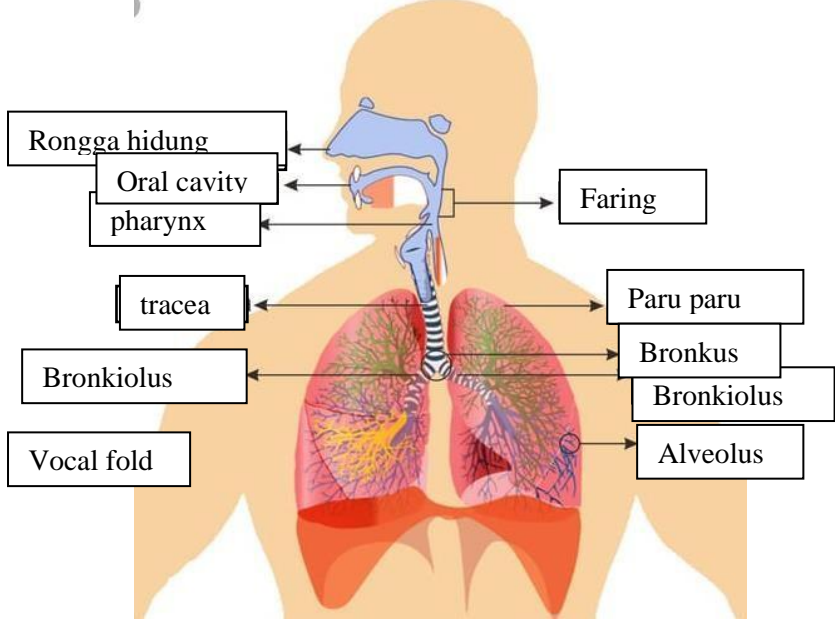
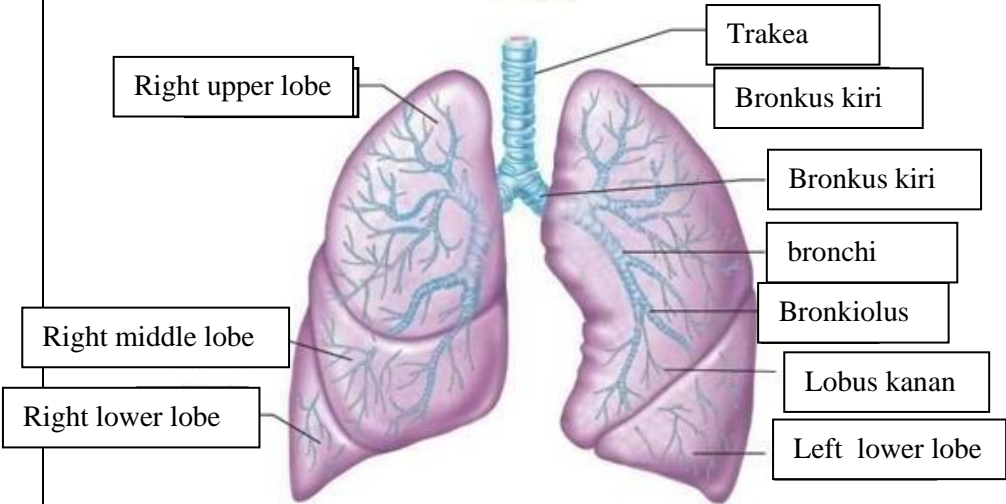
No	Keterangan	Pembahasan
1		
		



WORKSHEETS (LEMBAR KERJA)

Mata Kuliah	: Anatomi
Materi	: Anatomi Respirasi
NIM>Nama Mahasiswa	: 2110101031/ bisyarotul walidah

No	Keterangan	Pembahasan
1		<p>An anatomical diagram of the human respiratory system. The upper respiratory tract includes the nasal cavity (rongga hidung), pharynx (faring), and larynx. The lower respiratory tract includes the trachea (windpipe), bronchi (bronkus), and bronchioles (bronkiolus). The lungs are shown with the right lung (paru paru kanan) and left lung (paru paru kiri), surrounded by the pleura. The diaphragm is shown at the base of the thoracic cavity.</p>

No	Keterangan	Pembahasan
		 <p>Diagram of the human respiratory system with labels:</p> <ul style="list-style-type: none"> Rongga hidung Oral cavity pharynx Faring trachea Paru paru Bronkus Bronkiolus Vocal fold Alveolus
		 <p>Detailed diagram of the lungs with labels:</p> <ul style="list-style-type: none"> Trakea Bronkus kiri Bronkus kiri bronchi Bronkiolus Lobus kanan Left lower lobe Right upper lobe Right middle lobe Right lower lobe

