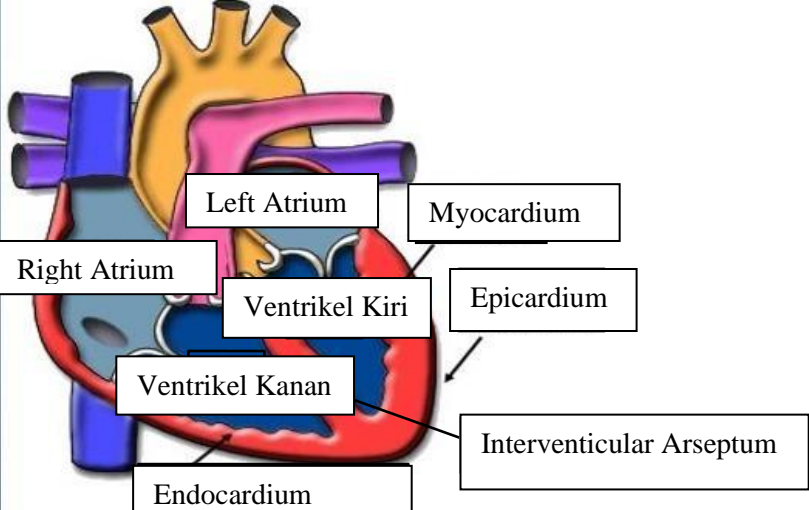
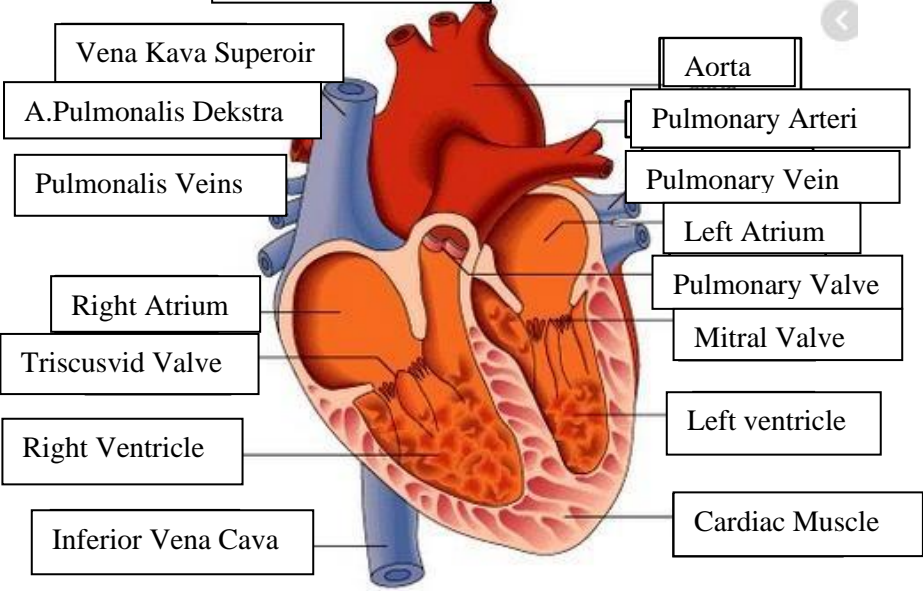
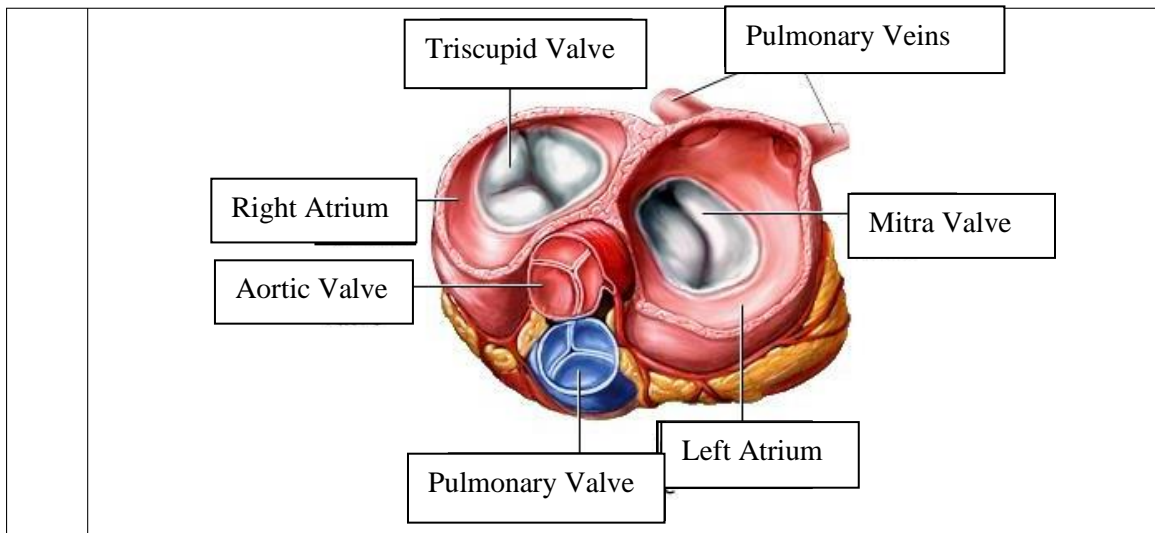


WORKSHEETS (LEMBAR KERJA)

Mata Kuliah	: Anatomi
Materi	: Anatomi Cardiovaskuler
NIM>Nama Mahasiswa	: Aliffah Musfirotun Azzahroh / 2110101020

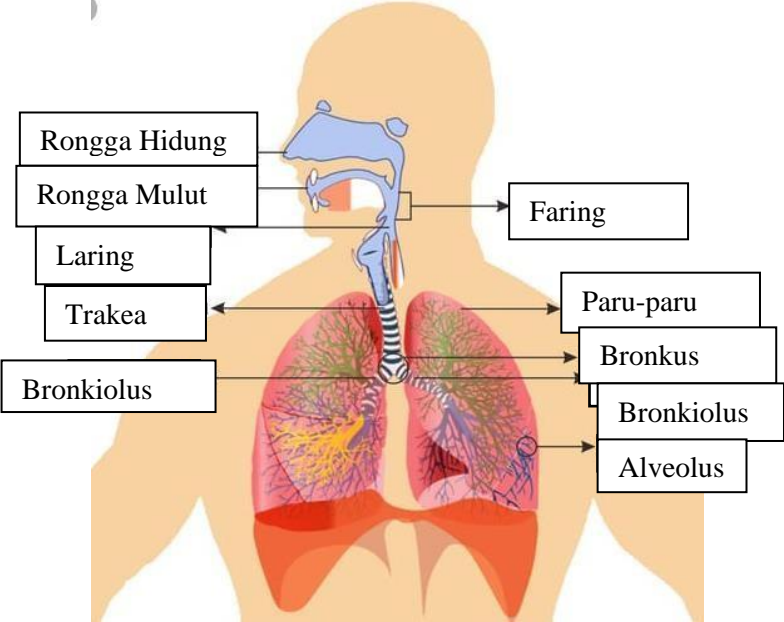
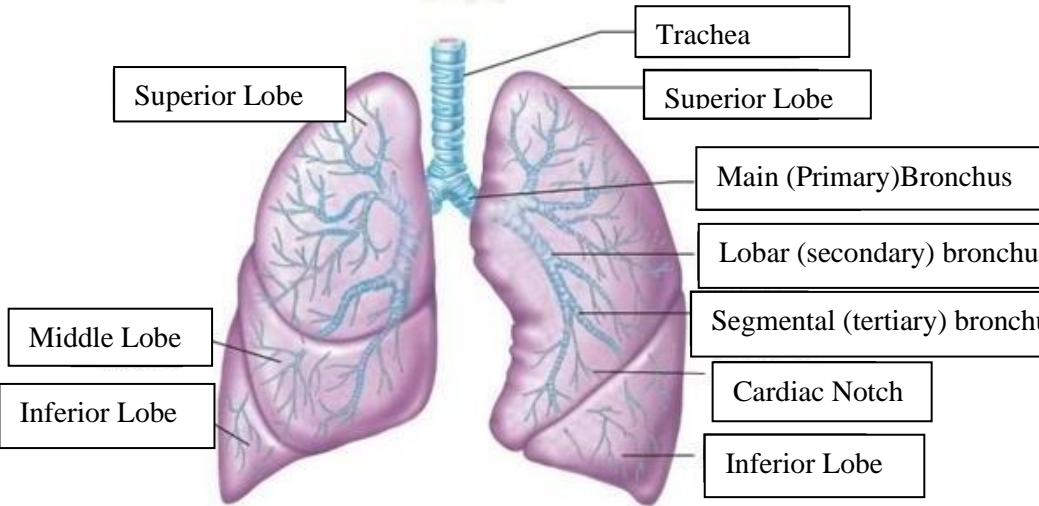
No	Keterangan	Pembahasan
1		
		



WORKSHEETS (LEMBAR KERJA)

Mata Kuliah	: Anatomi
Materi	: Anatomi Respirasi
NIM>Nama Mahasiswa	: Aliffah Musfirotun Azzahroh/2110101020

No	Keterangan	Pembahasan
1		<p>An anatomical diagram of the human respiratory system, showing the airway and lung structures. The diagram is labeled with the following parts:</p> <ul style="list-style-type: none"> Pharynx Nasal Cavity Esophagus Trachea Bronkus Bronkiolus Paru-paru Kanan Bronkus Paru-paru kiri Pleura Diafragma

No	Keterangan	Pembahasan
		 <p>Diagram of the human respiratory system with the following labels:</p> <ul style="list-style-type: none"> Rongga Hidung Rongga Mulut Faring Laring Trakea Paru-paru Bronkus Bronkiolus Alveolus
		 <p>Detailed diagram of the lungs with the following labels:</p> <ul style="list-style-type: none"> Trachea Superior Lobe Superior Lobe Main (Primary) Bronchus Lobar (secondary) bronchus Segmental (tertiary) bronchus Cardiac Notch Inferior Lobe Middle Lobe Inferior Lobe

