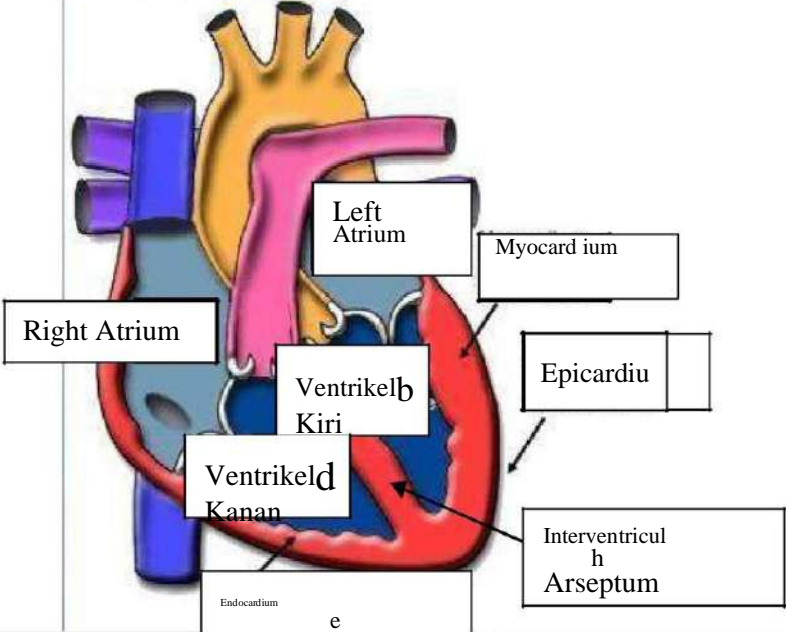
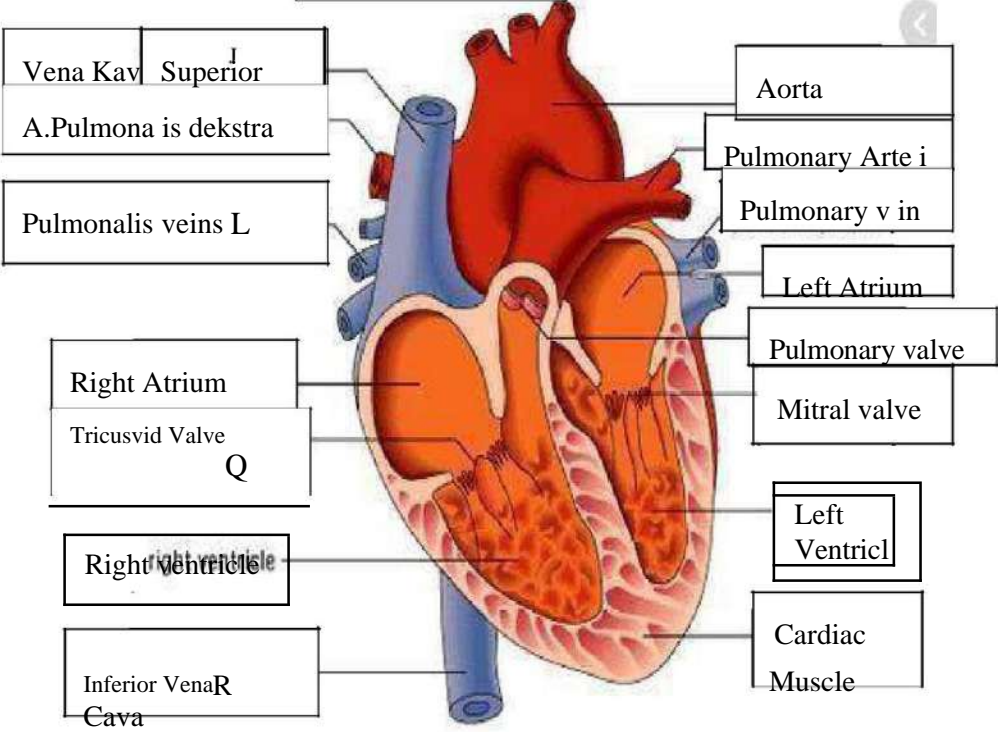


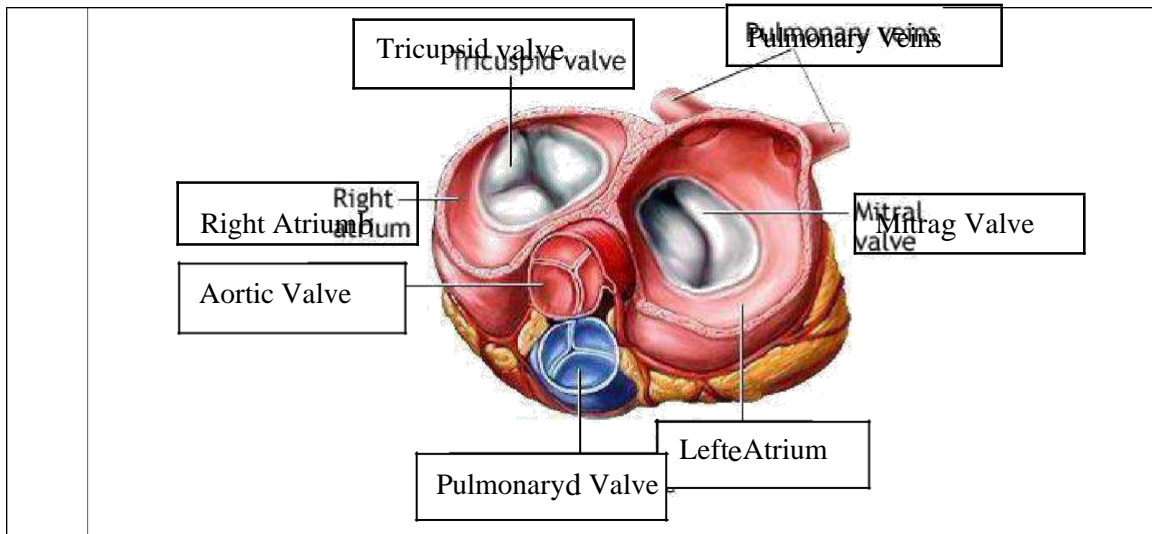
WORKSHEETS (LEMBAR KERJA)

Mata Kuliah	: Anatomi
Materi	: Anatomi Cardiovaskuler
NIM/Nama Mahasiswa	: 2110101019/Aris fatmala

No	Keterangan	Pembahasan
----	------------	------------

1		 <p>This diagram shows a cross-section of the heart wall and its internal chambers. The layers of the heart wall are labeled as follows: Endocardium (innermost), Myocardium (middle), and Epicardium (outermost). The chambers shown are the Right Atrium, Left Atrium, Right Ventricle (labeled 'Ventrikel Kanan'), and Left Ventricle (labeled 'Ventrikel Kiri'). The Interventricular Septum is also indicated.</p>
---	--	--

<p>Vena Cava Superior</p> <p>A. Pulmonalis dekstra</p> <p>Pulmonalis veins L</p> <p>Right Atrium</p> <p>Tricuspid Valve</p> <p>Right ventricle</p> <p>Inferior Vena Cava</p>	 <p>This diagram shows the heart with its major blood vessels and valves. The vessels shown include the Superior Vena Cava, Inferior Vena Cava, Pulmonary Artery, and Pulmonary Veins. The valves shown include the Tricuspid Valve, Pulmonary Valve, and Mitral Valve. The chambers shown include the Right Atrium, Right Ventricle, Left Atrium, and Left Ventricle. The Cardiac Muscle is also labeled.</p>	<p>Aorta</p> <p>Pulmonary Artery</p> <p>Pulmonary vein</p> <p>Left Atrium</p> <p>Pulmonary valve</p> <p>Mitral valve</p> <p>Left Ventricle</p> <p>Cardiac Muscle</p>
--	--	--



WORKSHEETS (LEMBAR KERJA)

Mata Kuliah	: Anatomi
Materi	: Anatomi Respirasi
NIM>Nama Mahasiswa	: 21101019/Aris fatmala

No	Keterangan	Pembahasan
1	<p>Pharynx Faring Esophagus c Bronkus e Paru Paru Kanan Pleura h Diafragma i</p>	<p>Nasal Cavity Traches Trachea Bronkiolus Bronkiolus Bronkus g Paru-Paru Kiri Paru-Paru Kiri</p>

No	Keterangan	Pembahasan
----	------------	------------

