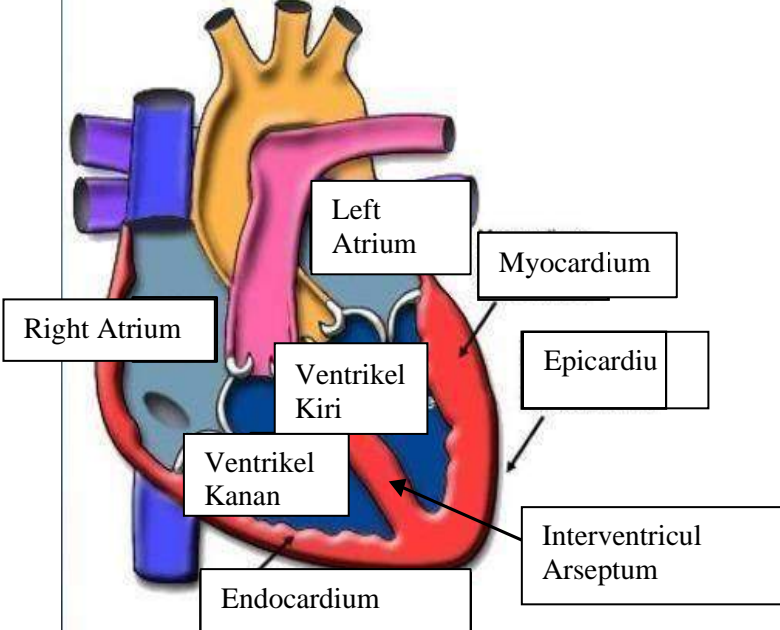
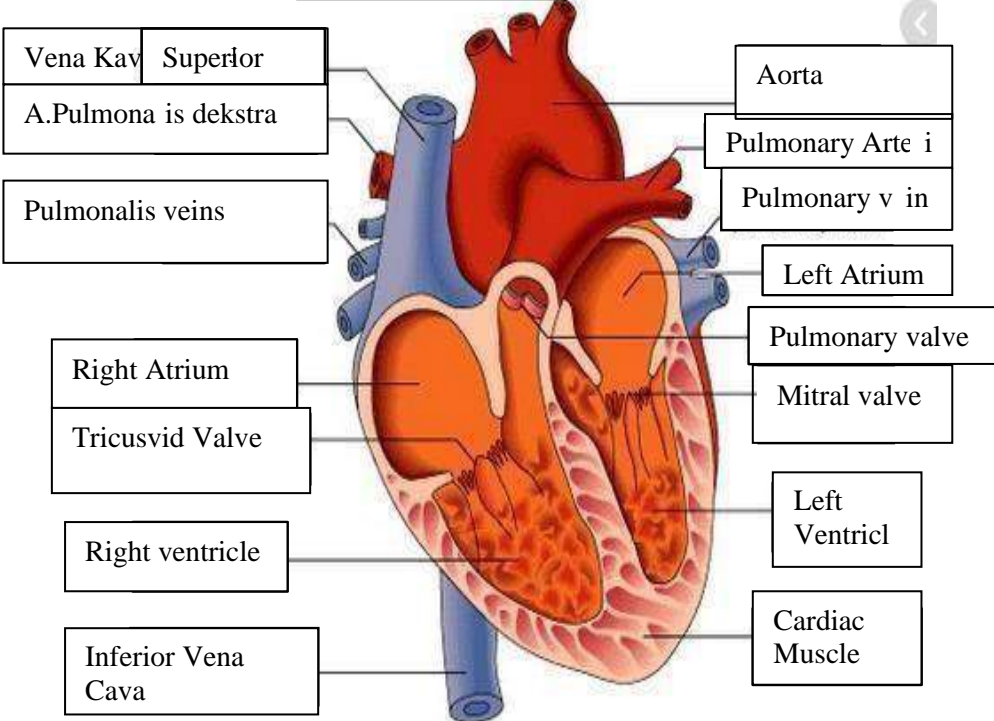
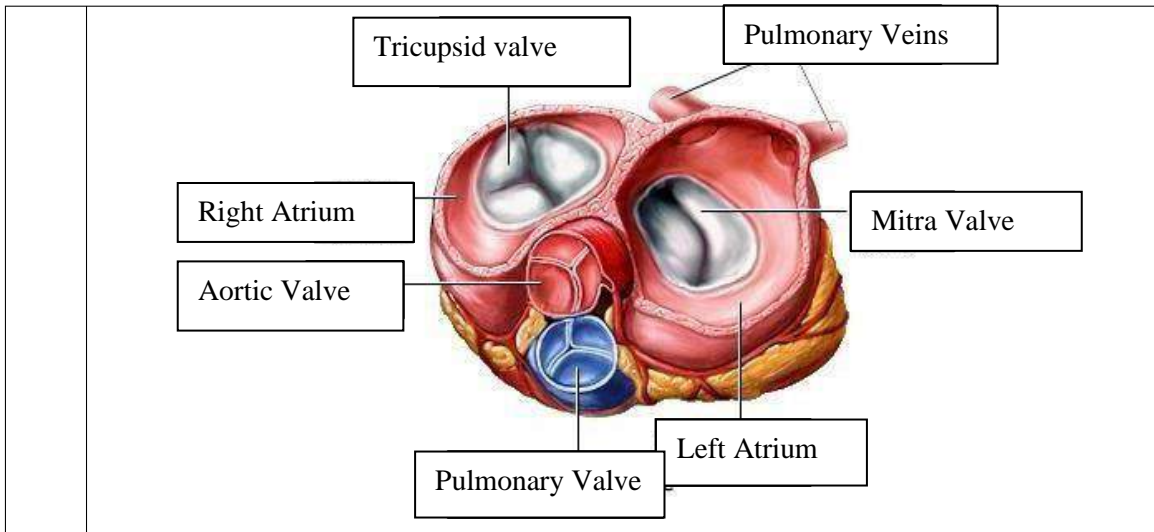


WORKSHEETS (LEMBAR KERJA)

Mata Kuliah	: Anatomi
Materi	: Anatomi Cardiovaskuler
NIM/Nama Mahasiswa	: 2110101002/Jasmin Linadi Yulia Putri

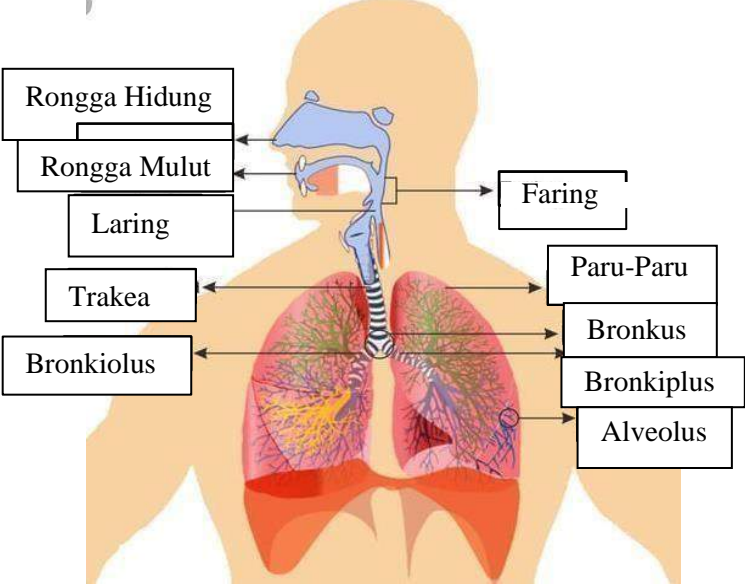
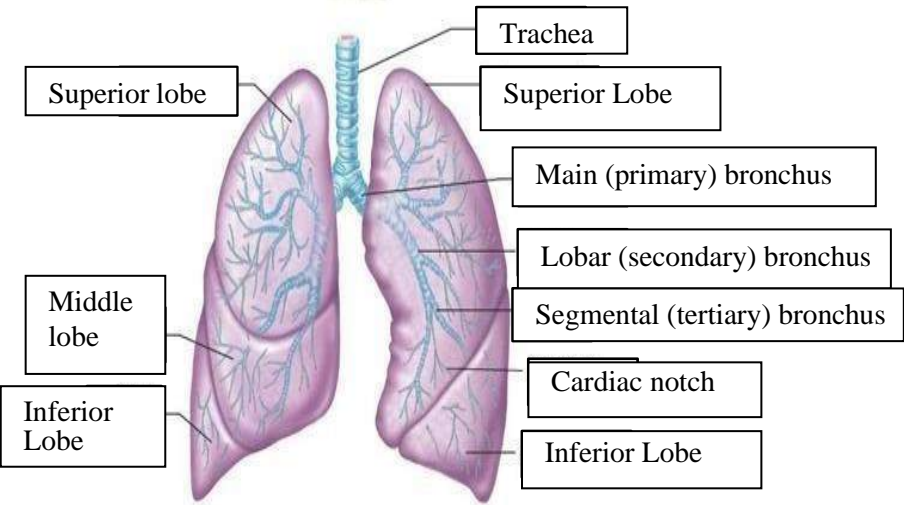
No	Keterangan	Pembahasan
1		 <p>This diagram shows a cross-section of the heart wall and its internal chambers. Labels include: Right Atrium, Left Atrium, Ventrikel Kiri (Left Ventricle), and Ventrikel Kanan (Right Ventricle). The wall layers are labeled as Endocardium (innermost), Myocardium (middle), and Epicardium (outermost). The Interventricular Arseptum (Septum) is also shown separating the ventricles.</p>
	 <p>This diagram shows a more detailed view of the heart with its major vessels and valves. Labels on the left side include: Vena Kav Superior (Superior Vena Cava), A. Pulmonalis dekstra (Right Pulmonary Artery), Pulmonalis veins (Pulmonary Veins), Right Atrium, Tricuspid Valve, Right ventricle, and Inferior Vena Cava (Inferior Vena Cava). Labels on the right side include: Aorta, Pulmonary Arteri (Right Pulmonary Artery), Pulmonary v in (Pulmonary Vein), Left Atrium, Pulmonary valve, Mitral valve, Left Ventricl (Left Ventricle), and Cardiac Muscle.</p>	



WORKSHEETS (LEMBAR KERJA)

Mata Kuliah	: Anatomi
Materi	: Anatomi Respirasi
NIM>Nama Mahasiswa	: 2110101002/Jasmin Lnadi Yulia Putri

No	Keterangan	Pembahasan
1	<p>An anatomical diagram of the human respiratory system. It shows the nasal cavity leading to the pharynx, which branches into the trachea (windpipe) and the esophagus. The trachea leads to the bronchi, which branch into bronchioles and finally reach the lungs (paru-paru kanan and paru-paru kiri). The lungs are surrounded by the pleura, and the diaphragm is shown at the base of the thoracic cavity. Labels with leader lines identify each part.</p>	

No	Keterangan	Pembahasan
		 <p>Diagram of the human respiratory system with labels:</p> <ul style="list-style-type: none"> Rongga Hidung Rongga Mulut Laring Trakea Bronkiolus Faring Paru-Paru Bronkus Bronkiplus Alveolus
		 <p>Detailed diagram of the lungs with labels:</p> <ul style="list-style-type: none"> Trachea Superior lobe Middle lobe Inferior Lobe Superior Lobe Main (primary) bronchus Lobar (secondary) bronchus Segmental (tertiary) bronchus Cardiac notch Inferior Lobe

