

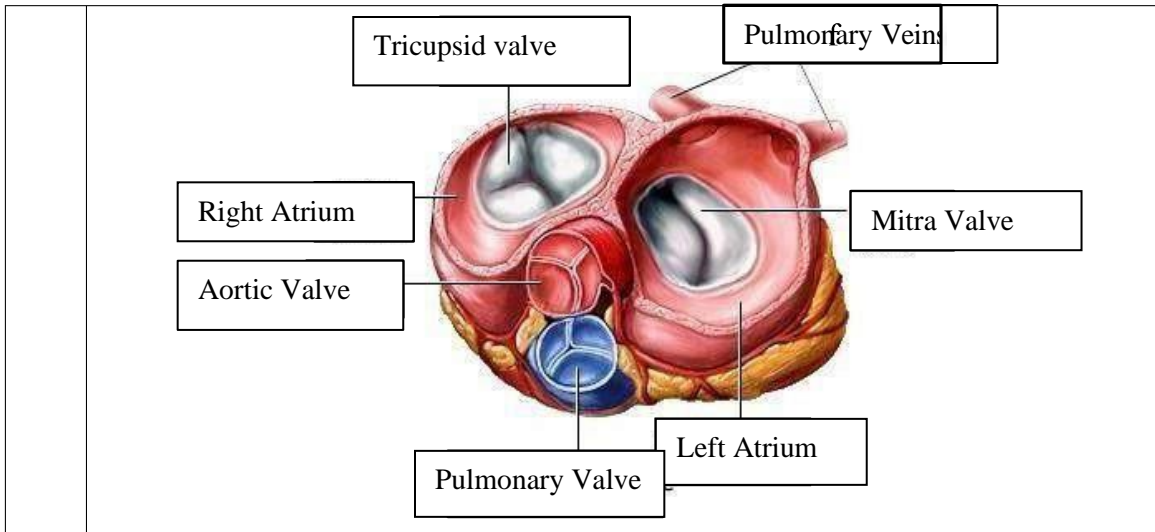
WORKSHEETS (LEMBAR KERJA)

Mata Kuliah	: Anatomi
Materi	: Anatomi Cardiovaskuler
NIM/Nama Mahasiswa	: 211010101/Dea Resita

No	Keterangan	Pembahasan
----	------------	------------

1		
---	--	--

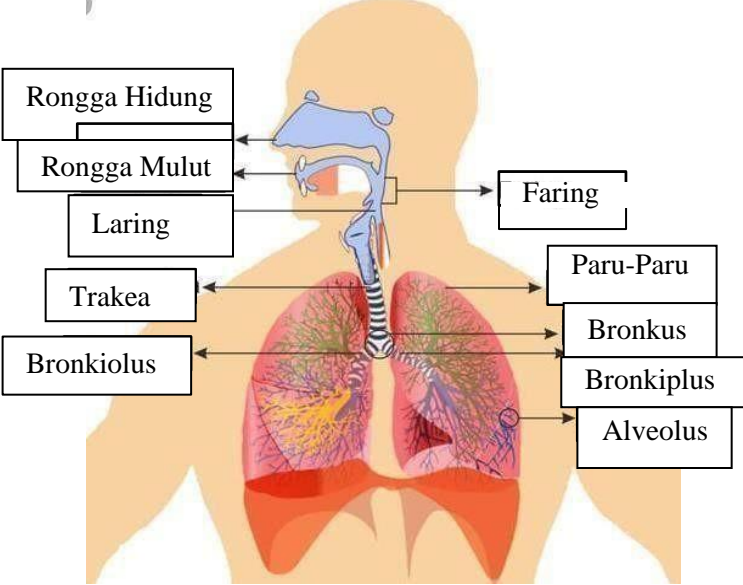
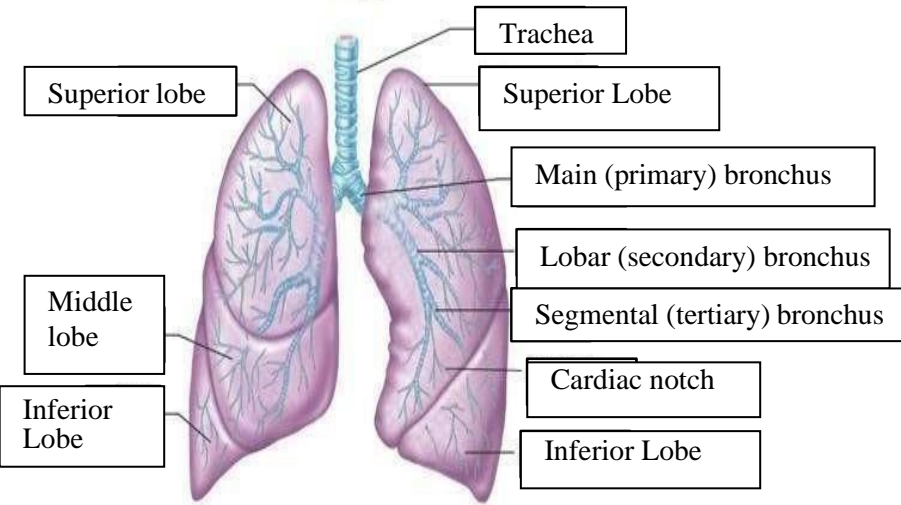
<div data-bbox="331 1171 657 1294" data-label="Text"> <p>Vena Kav Superior A. Pulmonalis dekstra</p> </div> <div data-bbox="331 1323 657 1406" data-label="Text"> <p>Pulmonalis veins</p> </div> <div data-bbox="379 1480 641 1637" data-label="Text"> <p>Right Atrium Tricuspid Valve</p> </div> <div data-bbox="391 1666 619 1733" data-label="Text"> <p>Right ventricle</p> </div> <div data-bbox="391 1771 651 1854" data-label="Text"> <p>Inferior Vena Cava</p> </div>		<div data-bbox="1066 1189 1284 1234" data-label="Text"> <p>Aorta</p> </div> <div data-bbox="1050 1267 1284 1312" data-label="Text"> <p>Pulmonary Arteri</p> </div> <div data-bbox="1050 1323 1284 1368" data-label="Text"> <p>Pulmonary vein</p> </div> <div data-bbox="1098 1402 1284 1447" data-label="Text"> <p>Left Atrium</p> </div> <div data-bbox="1082 1458 1327 1503" data-label="Text"> <p>Pulmonary valve</p> </div> <div data-bbox="1082 1514 1284 1559" data-label="Text"> <p>Mitral valve</p> </div> <div data-bbox="1098 1626 1252 1715" data-label="Text"> <p>Left Ventricl</p> </div> <div data-bbox="1082 1738 1252 1827" data-label="Text"> <p>Cardiac Muscle</p> </div>
--------------------------------------------------------------------------------------------------------------------------------------------------------------------------------------------------------------------------------------------------------------------------------------------------------------------------------------------------------------------------------------------------------------------------------------------------------------------------------------	--	---------------------------------------------------------------------------------------------------------------------------------------------------------------------------------------------------------------------------------------------------------------------------------------------------------------------------------------------------------------------------------------------------------------------------------------------------------------------------------------------------------------------------------------------------------------------------------------------------------------------------------------------------------------------------------------------



WORKSHEETS (LEMBAR KERJA)

Mata Kuliah	: Anatomi
Materi	: Anatomi Respirasi
NIM>Nama Mahasiswa	: 2110101002/Jasmin LInadi Yulia Putri

No	Keterangan	Pembahasan
1	<p>An anatomical diagram of the human respiratory system, showing the nasal cavity, pharynx, trachea, bronchi, bronchioles, lungs, pleura, and diaphragm. The diagram is labeled with the following parts:</p> <ul style="list-style-type: none"> Pharynx Nasal Cavity Esophagus Trachea Bronkus Bronkiolus Paru Paru Kanan Bronkus Pleura Paru-Paru Kiri Diafragma 	

No	Keterangan	Pembahasan
		 <p>Diagram of the human respiratory system with labels:</p> <ul style="list-style-type: none"> Rongga Hidung Rongga Mulut Laring Trakea Bronkiolus Faring Paru-Paru Bronkus Bronkiplus Alveolus
		 <p>Detailed diagram of the lungs with labels:</p> <ul style="list-style-type: none"> Trachea Superior lobe Middle lobe Inferior Lobe Superior Lobe Main (primary) bronchus Lobar (secondary) bronchus Segmental (tertiary) bronchus Cardiac notch Inferior Lobe

