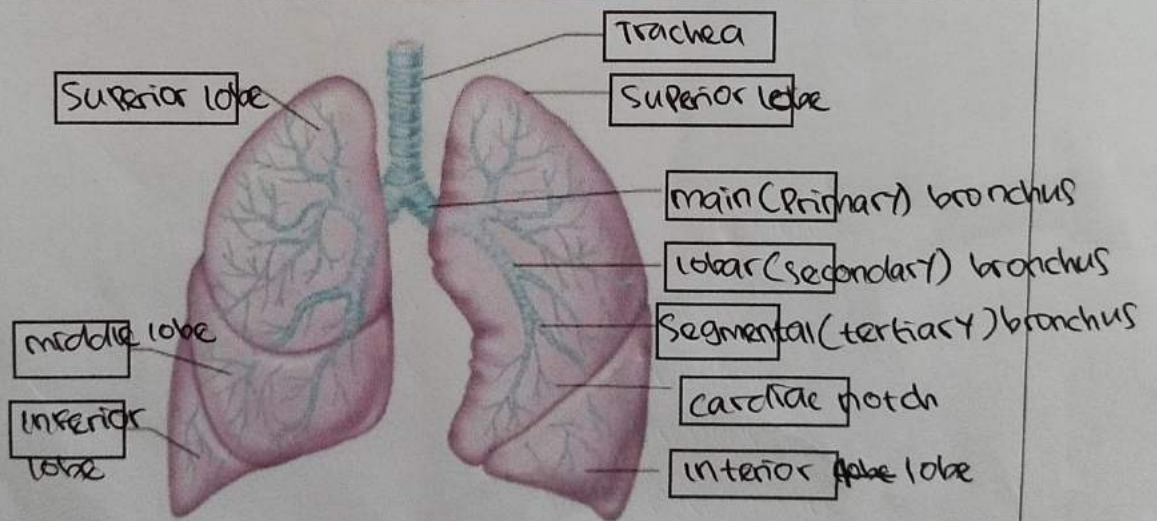
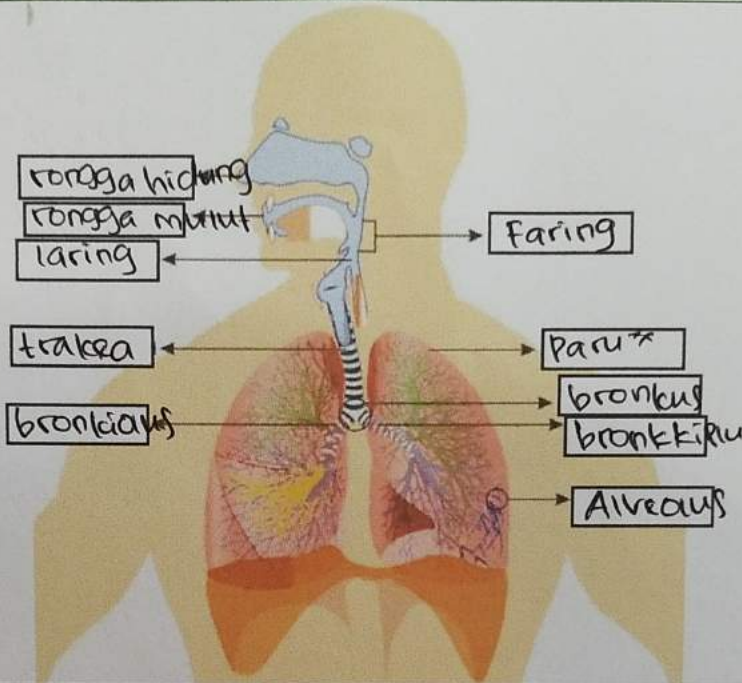
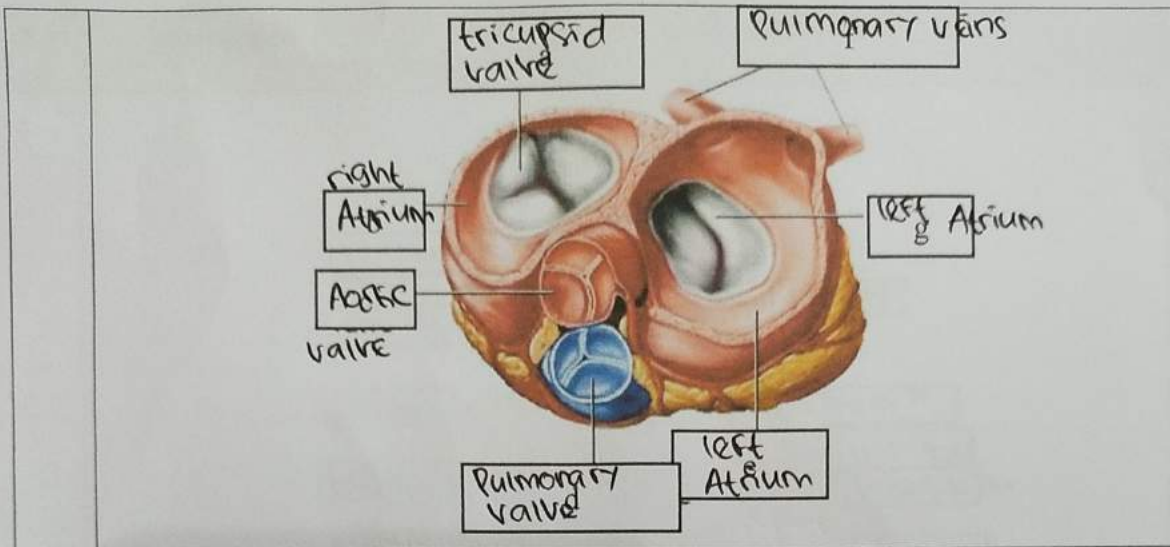


No	Keterangan	Pembahasan
----	------------	------------





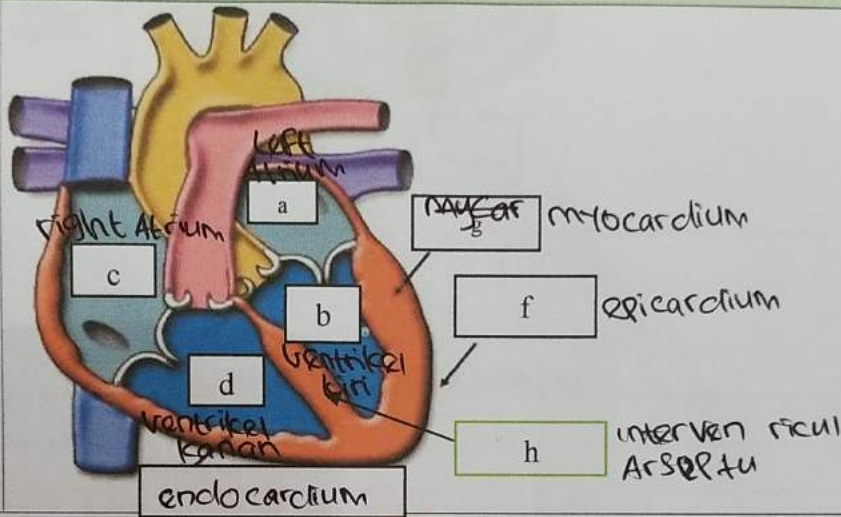
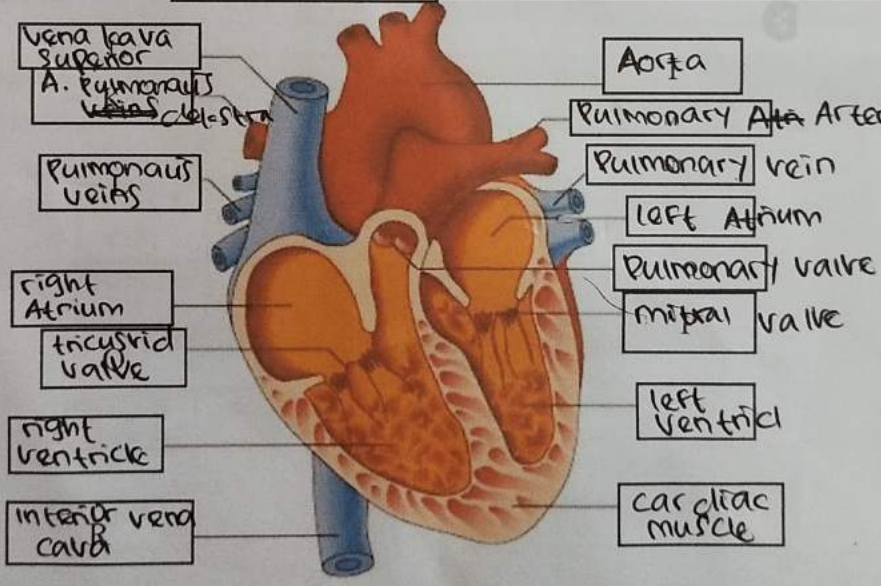
**WORKSHEETS (LEMBAR KERJA)**

Mata Kuliah	: Anatomi
Materi	: Anatomi Respirasi
NIM>Nama Mahasiswa	: 210101034 / Lia Agusmarina

No	Keterangan	Pembahasan
1	<p>Handwritten labels for the respiratory system diagram:</p> <ul style="list-style-type: none"> <li>Pharynx</li> <li>esophagus</li> <li>bronchus</li> <li>paru x kanan</li> <li>pleura</li> <li>nasal cavity</li> <li>trachea</li> <li>bronchiolus</li> <li>bronchus</li> <li>paru x kiri</li> <li>diafragma</li> </ul>	

WORKSHEETS (LEMBAR KERJA)

Mata Kuliah	: Anatomi
Materi	: Anatomi Cardiovaskuler
NIM>Nama Mahasiswa	: 21101034 / Lia Agusmarina

No	Keterangan	Pembahasan
1		 <p>                     Diagram showing the layers of the heart wall and internal structures. Labels include:                     <ul style="list-style-type: none"> <li>Left Atrium</li> <li>Right Atrium</li> <li>ventrikel kiri</li> <li>ventrikel kanan</li> <li>endocardium</li> <li>myocardium</li> <li>epicardium</li> <li>interventricular septum</li> </ul> </p>
		 <p>                     Diagram showing the heart with major vessels and valves. Labels include:                     <ul style="list-style-type: none"> <li>vena kava superior</li> <li>A. pulmonalis</li> <li>pulmonalis veins</li> <li>right Atrium</li> <li>tricuspid valve</li> <li>right ventricle</li> <li>inferior vena cava</li> <li>Aorta</li> <li>Pulmonary Artery</li> <li>Pulmonary vein</li> <li>left Atrium</li> <li>Pulmonary valve</li> <li>mitral valve</li> <li>left ventricle</li> <li>cardiac muscle</li> </ul> </p>