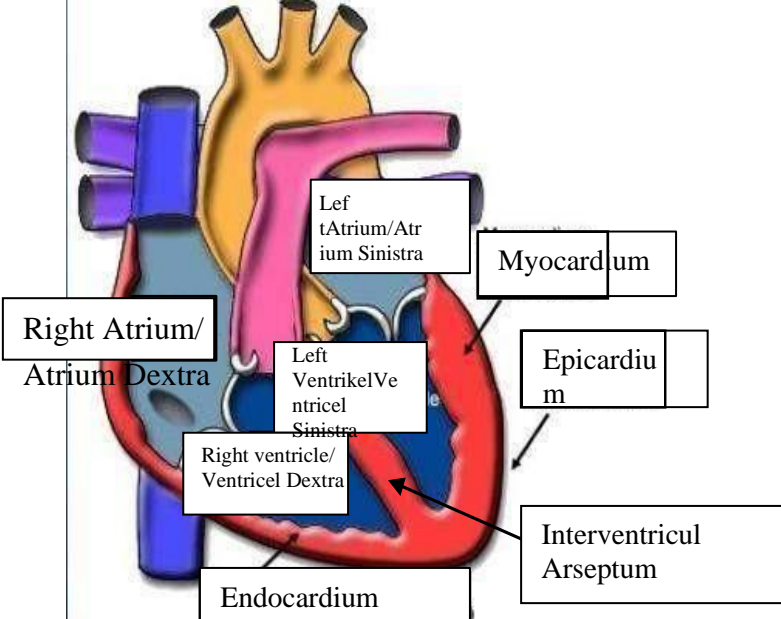
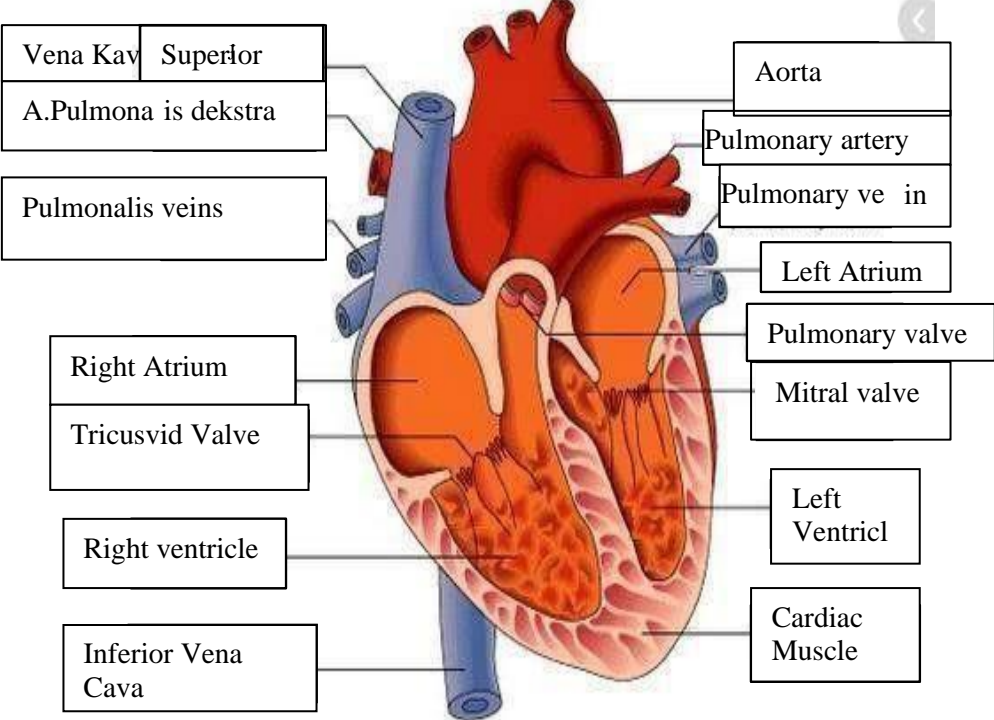


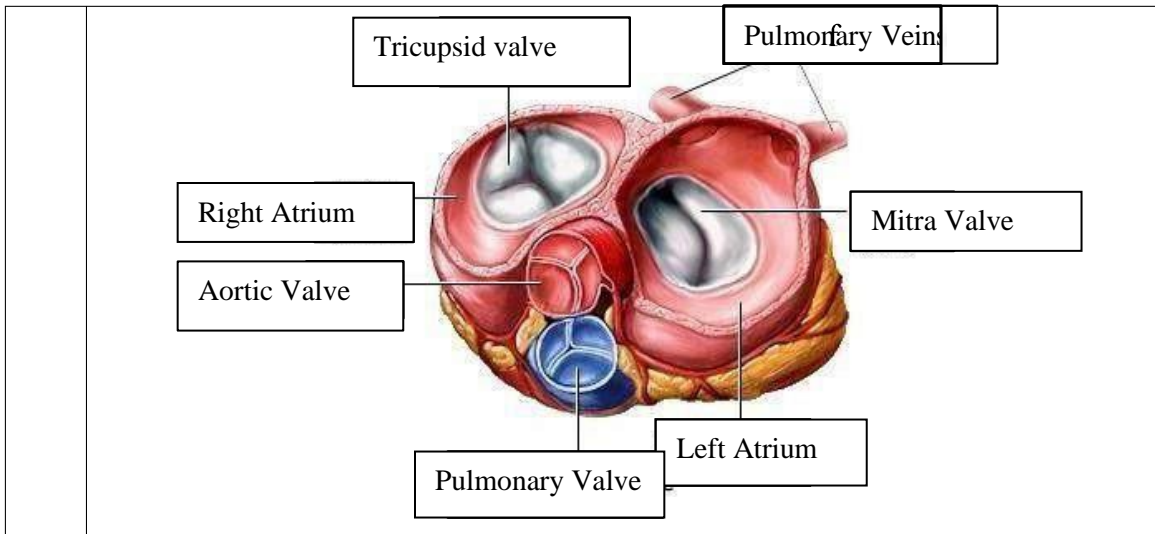
WORKSHEETS (LEMBAR KERJA)

Mata Kuliah	: Anatomi
Materi	: Anatomi Cardiovaskuler
NIM/Nama Mahasiswa	: 2110101015/Fitrilia Rahmawati

No	Keterangan	Pembahasan
----	------------	------------

1		 <p>This diagram shows a cross-section of the heart wall and its internal chambers. Labels include: Right Atrium/Atrium Dextra, Left Atrium/Atrium Sinistra, Left Ventrikel/Ventrikel Sinistra, Right ventricle/Ventrikel Dextra, Myocardium, Epicardium, Endocardium, and Interventricular Arseptum.</p>
---	--	--

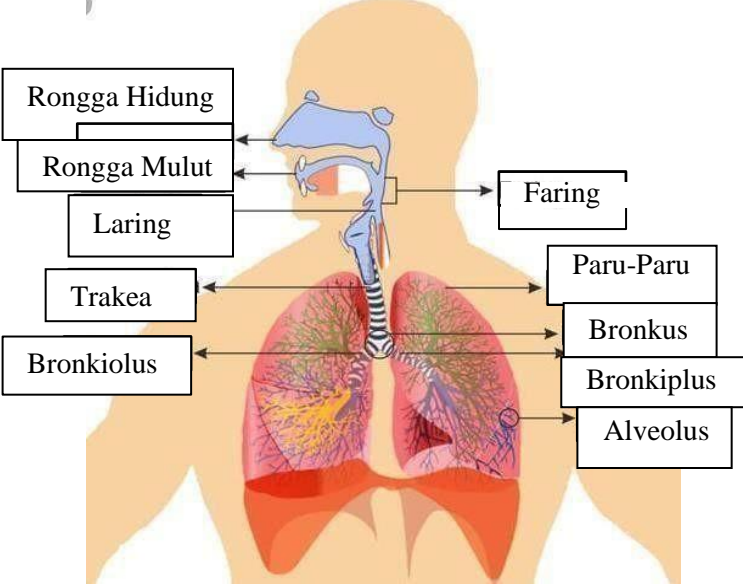
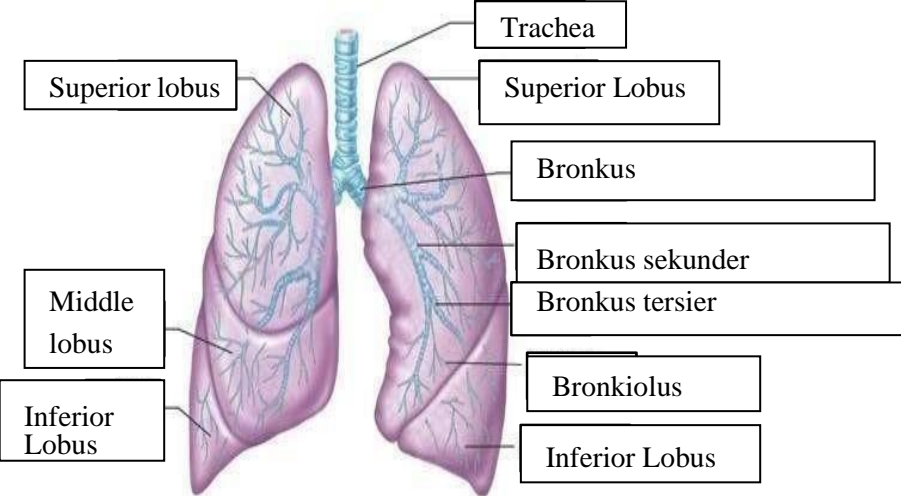
<p>Vena Kav Superior</p> <p>A. Pulmonalis dekstra</p> <p>Pulmonalis veins</p> <p>Right Atrium</p> <p>Tricuspid Valve</p> <p>Right ventricle</p> <p>Inferior Vena Cava</p>	 <p>This diagram shows a detailed cross-section of the heart, highlighting the internal chambers and valves. Labels include: Aorta, Pulmonary artery, Pulmonary vein, Left Atrium, Pulmonary valve, Mitral valve, Left Ventrikel, Cardiac Muscle, Right Atrium, Tricuspid Valve, Right ventricle, and Inferior Vena Cava.</p>	<p>Aorta</p> <p>Pulmonary artery</p> <p>Pulmonary vein</p> <p>Left Atrium</p> <p>Pulmonary valve</p> <p>Mitral valve</p> <p>Left Ventrikel</p> <p>Cardiac Muscle</p>
---	---	--



WORKSHEETS (LEMBAR KERJA)

Mata Kuliah	: Anatomi
Materi	: Anatomi Respirasi
NIM>Nama Mahasiswa	: 2110101015/Fitrilia Rahmawati

No	Keterangan	Pembahasan
1	<p>Pharynx</p> <p>Esophagus</p> <p>Bronkus</p> <p>Paru Paru Kanan</p> <p>Pleura</p> <p>Nasal Cavity</p> <p>Traches</p> <p>Bronkiolus</p> <p>Bronkus</p> <p>Paru-Paru Kiri</p> <p>Diafragma</p> <p>Detailed description: This diagram shows the human respiratory system. The nasal cavity leads to the pharynx. The trachea (windpipe) leads to the bronchi, which branch into bronchioles and finally into the lungs (paru-paru kanan and paru-paru kiri). The diaphragm is shown at the base of the thoracic cavity. The pleura are the membranes surrounding the lungs.</p>	

No	Keterangan	Pembahasan
		 <p>Diagram of the human respiratory system with labels: Rongga Hidung, Rongga Mulut, Laring, Trakea, Bronkiolus, Faring, Paru-Paru, Bronkus, Bronkiplus, Alveolus.</p>
		 <p>Detailed diagram of the lungs with labels: Superior lobus, Middle lobus, Inferior Lobus, Trachea, Superior Lobus, Bronkus, Bronkus sekunder, Bronkus tersier, Bronkiolus, Inferior Lobus.</p>

