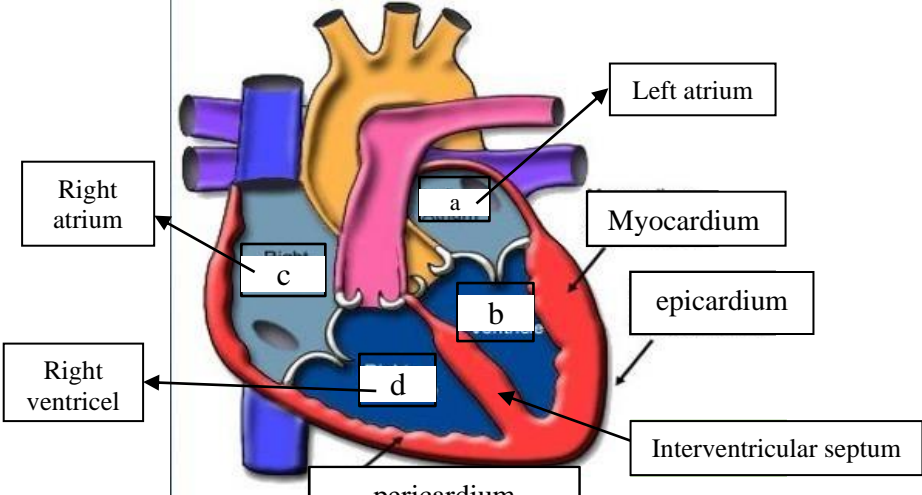
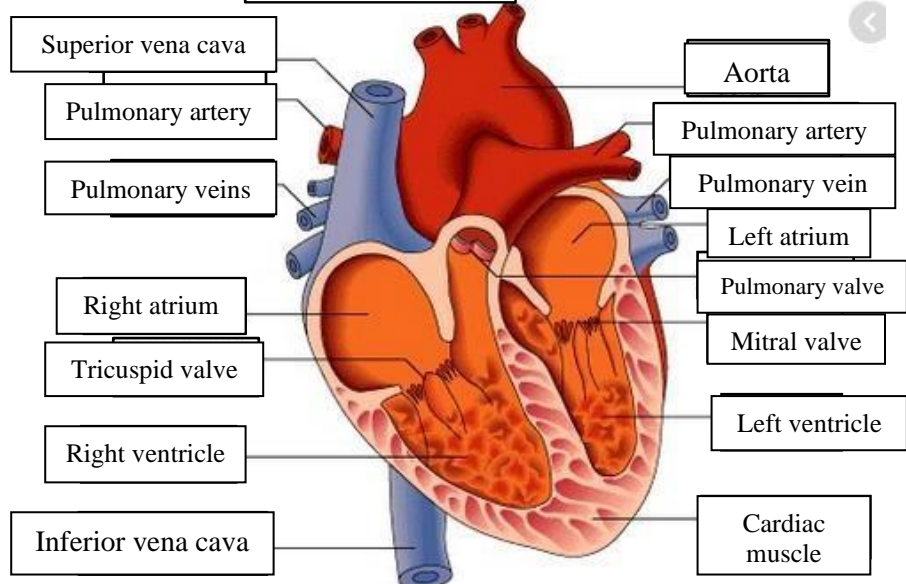
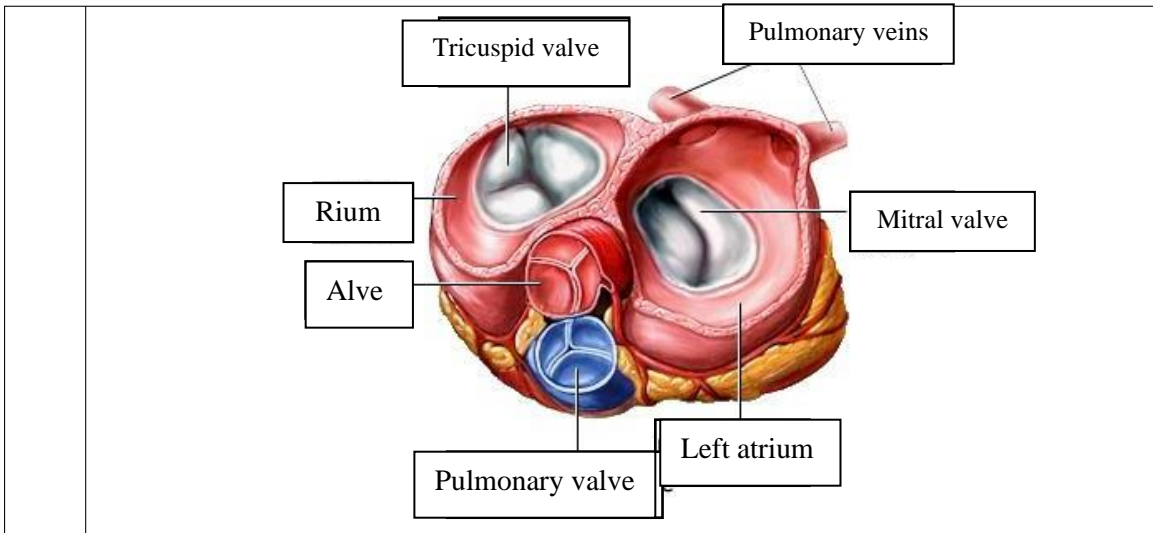


**WORKSHEETS (LEMBAR KERJA)**

<b>Mata Kuliah</b>	: <b>Anatomi</b>
<b>Materi</b>	: <b>Anatomi Cardiovaskuler</b>
<b>NIM&gt;Nama Mahasiswa</b>	: <b>2110101036/Fauzia Alvian Nurkasanah</b>

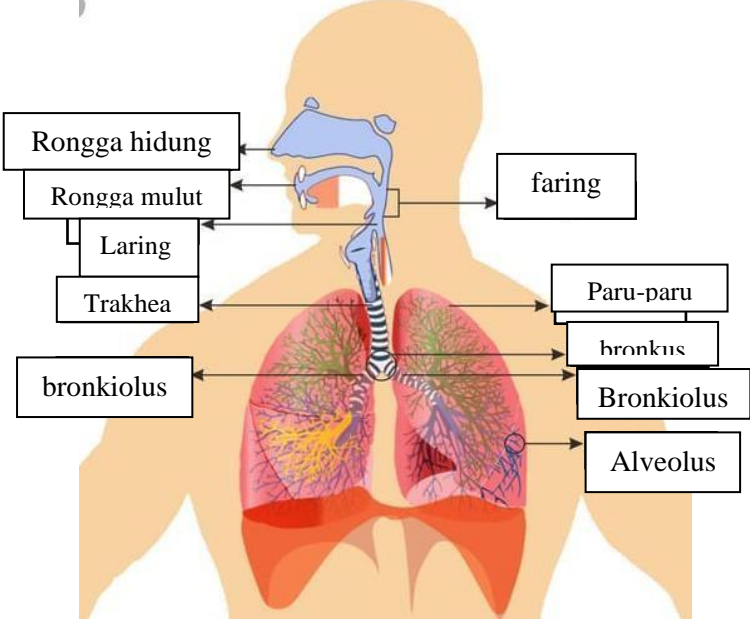
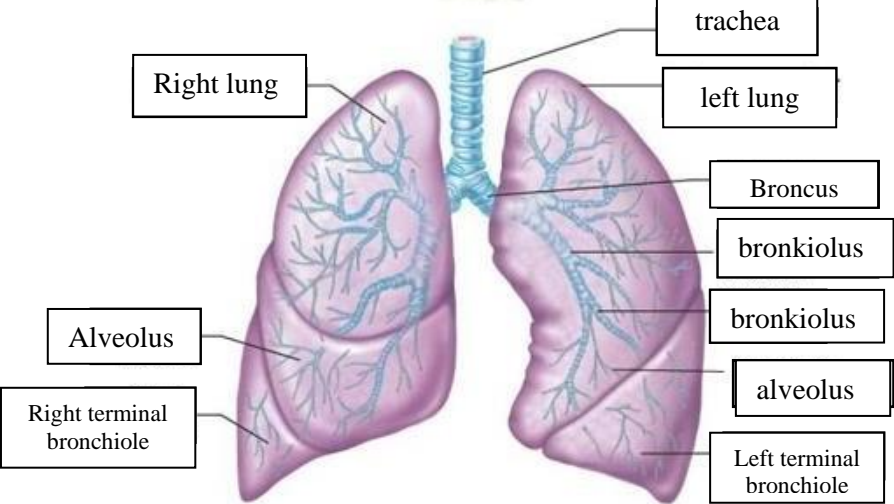
No	Keterangan	Pembahasan
1		



**WORKSHEETS (LEMBAR KERJA)**

<b>Mata Kuliah</b>	: Anatomi
<b>Materi</b>	: Anatomi Respirasi
<b>NIM&gt;Nama Mahasiswa</b>	: 2110101036/Fauzia Alvian Nurkasanah

No	Keterangan	Pembahasan
1	<p>An anatomical diagram of the human respiratory system. Labels include: pharynx, Larynx, Broncus, Right lung, Pleura, Nasal cavity, Trachea, Bronkiolus, Broncus, Left lung, and Diafragma. The diagram shows the airway from the nasal cavity down to the lungs, branching into bronchi and bronchioles, and the diaphragm at the base.</p>	

No	Keterangan	Pembahasan
		 <p>Diagram of the human respiratory system with labels: Rongga hidung, Rongga mulut, Laring, Trakhea, faring, Paru-paru, bronkus, Bronkiolus, Alveolus.</p>
		 <p>Detailed diagram of the lungs with labels: trachea, Right lung, left lung, Broncus, bronkiolus, bronkiolus, Alveolus, Right terminal bronchiole, alveolus, Left terminal bronchiole.</p>

