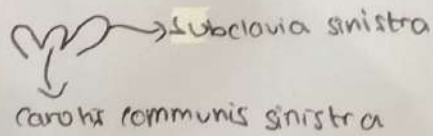


WORKSHEETS (LEMBAR KERJA)

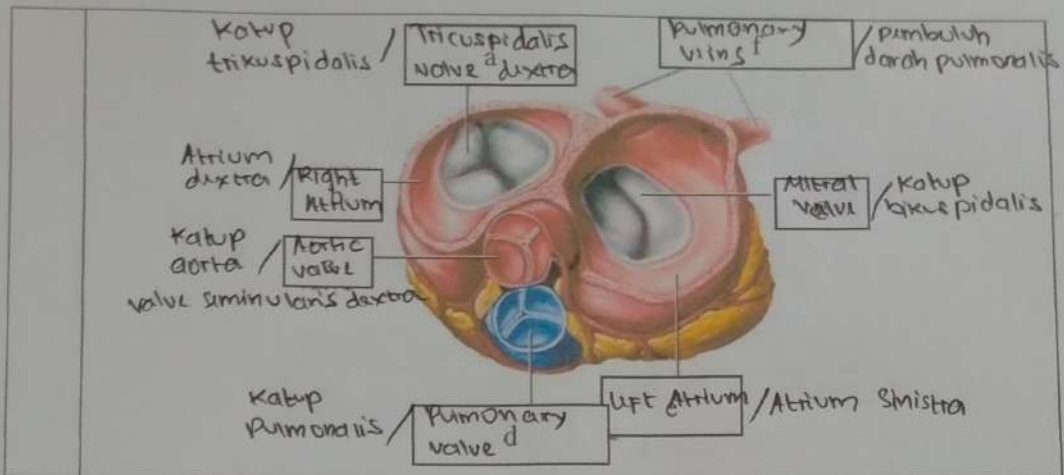
Mata Kuliah	: Anatomi
Materi	: Anatomi Kardiovaskuler dan Limfatis
NIM>Nama Mahasiswa	: MDANIKA SUMARNIS /2110101006

No	Keterangan	Pembahasan
1		<p>The top diagram shows a cross-section of the heart wall layers with labels: Atrium dextra, Right Atrium, Ventricle dextra, Right Ventricle, Atrium sinistra, Left Atrium, Myocardium (heart muscle), Endocardium (inner surface of myocardium), Septum Interventricular (Intra-ventricular), Epicardium (outer surface of myocardium), and Coronary Artery (CA). The bottom diagram shows a more detailed view of the heart with labels: Truncus, Superior vena cava, Pulmonary artery dextra, Pulmonary vein sinistra, Right atrium, Inferior vena cava, Right ventricle, Inferior vena cava, Carotis communis sinistra, Aorta, Pulmonary artery sinistra, Pulmonary vein sinistra, Left Atrium, Pulmonary valve, Mitral Valve, Left ventricle, Cardiac muscle, and subclavia sinistra.</p>

Aorta :



lapisan jantung paling luar : epi
tengah : mio
dalam : endo



WORKSHEETS (LEMBAR KERJA)

Mata Kuliah	: Anatomi
Materi	: Anatomi Respirasi
NIM>Nama Mahasiswa	: 2110101006 / MONIKA LUMARAILIS

No	Keterangan	Pembahasan
1	<p> Kapus Epiglottis / laring Bronkus Lobus superior / paru-paru kanan Lobus inferior / paru-paru Rumbungkus paru-paru - pleura visceral / dalam - pleura parietal / luar </p>	<p> Rongga Hidung / nasal Trakea Bronkiolus Bronkus Paru-paru Kiri / sinistra diafagi Diaphragma </p>

No	Keterangan	Pembahasan
----	------------	------------

