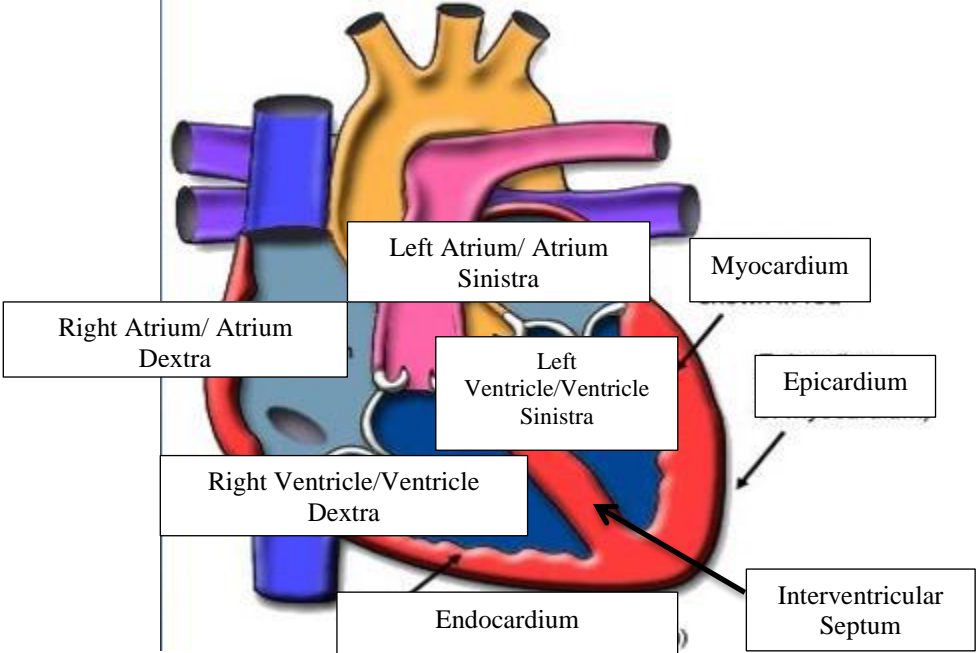
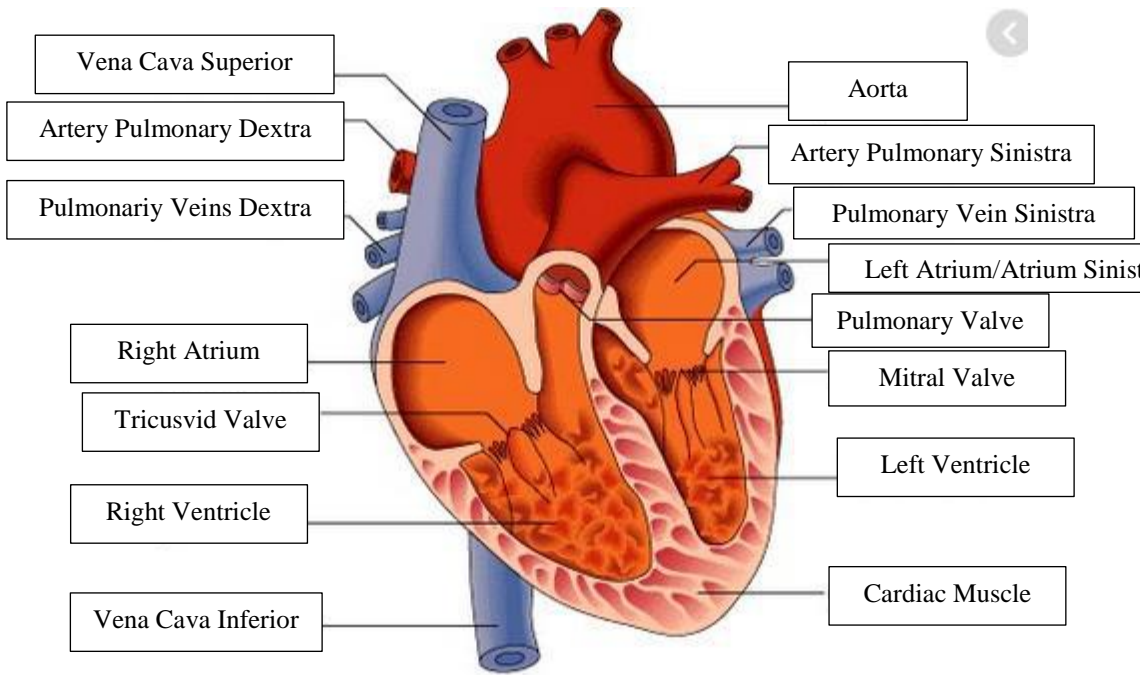
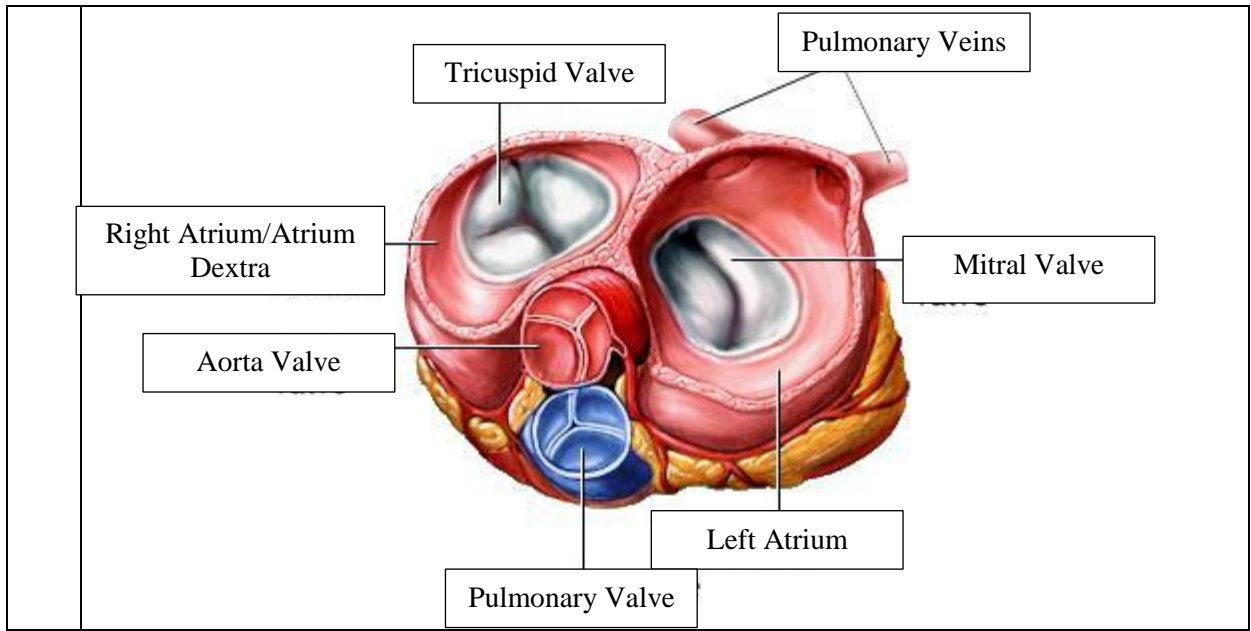


WORKSHEETS (LEMBAR KERJA)

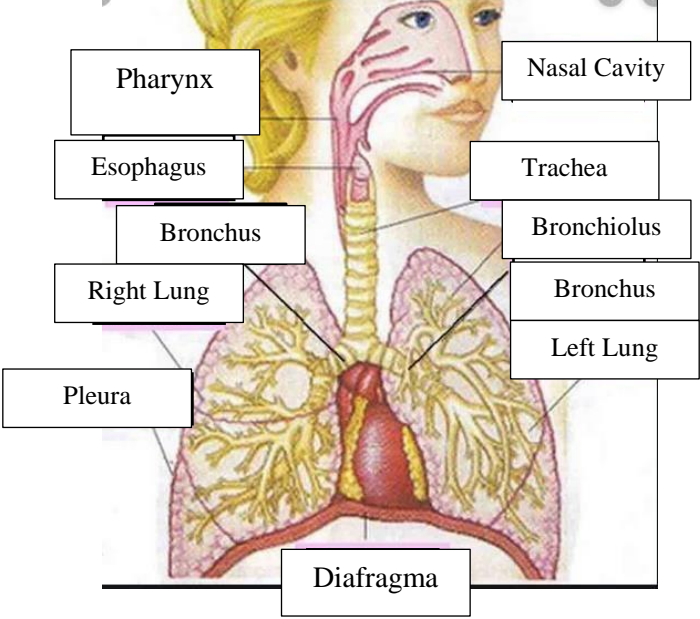
Mata Kuliah	:	Anatomi
Materi	:	Anatomi Cardiovaskuler
NIM>Nama Mahasiswa	:	2110101009/Azira Syiffa Ramadhani

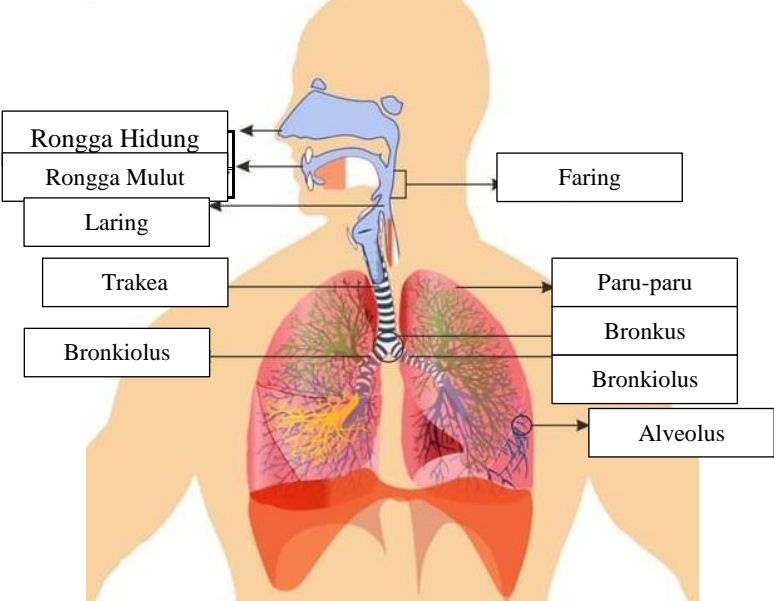
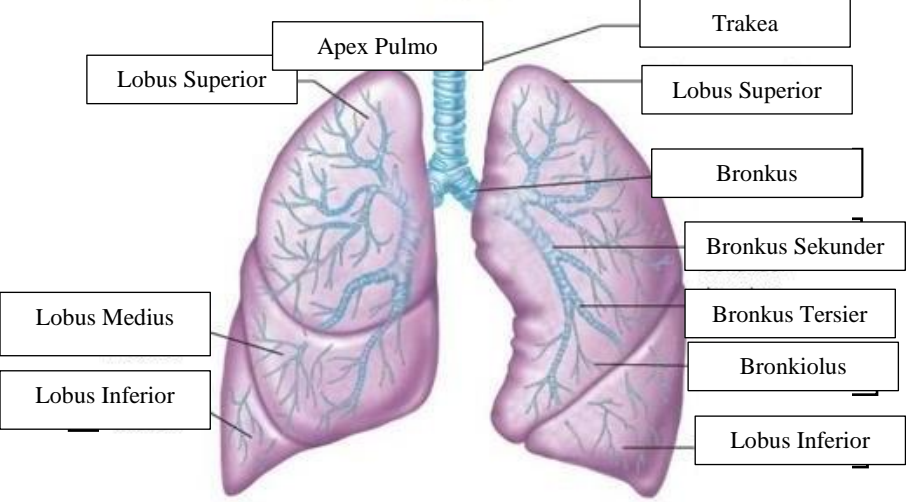
No	Keterangan	Pembahasan
		 <p>This diagram shows a cross-section of the heart wall and its internal chambers. Labels include: Left Atrium/ Atrium Sinistra, Myocardium, Right Atrium/ Atrium Dextra, Left Ventricle/Ventricle Sinistra, Epicardium, Right Ventricle/Ventricle Dextra, Endocardium, and Interventricular Septum. Arrows point from the text labels to the corresponding anatomical structures in the diagram.</p>
		 <p>This diagram shows a more detailed view of the heart, including major blood vessels and valves. Labels include: Vena Cava Superior, Artery Pulmonary Dextra, Pulmonary Veins Dextra, Right Atrium, Tricuspid Valve, Right Ventricle, Vena Cava Inferior, Aorta, Artery Pulmonary Sinistra, Pulmonary Vein Sinistra, Left Atrium/Atrium Sinistra, Pulmonary Valve, Mitral Valve, Left Ventricle, and Cardiac Muscle. Lines connect the text labels to the specific parts of the heart and its associated vessels.</p>



WORKSHEETS (LEMBAR KERJA)

Mata Kuliah	: Anatomi
Materi	: Anatomi Respirasi
NIM>Nama Mahasiswa	: 2110101009/Azira Syiffa Ramadhani

No	Keterangan	Pembahasan
1		 <p>The diagram illustrates the human respiratory system. On the left side, labels point to the Pharynx, Esophagus, Bronchus, Right Lung, and Pleura. On the right side, labels point to the Nasal Cavity, Trachea, Bronchiolus, Bronchus, and Left Lung. At the bottom, a label points to the Diafragma (diaphragm).</p>

No	Keterangan	Pembahasan
		 <p>Diagram of the human respiratory system with the following labels:</p> <ul style="list-style-type: none"> Rongga Hidung Rongga Mulut Laring Trakea Bronkiolus Faring Paru-paru Bronkus Bronkiolus Alveolus
		 <p>Detailed diagram of the lungs with the following labels:</p> <ul style="list-style-type: none"> Lobus Superior Apex Pulmo Lobus Superior Lobus Medius Lobus Inferior Trakea Bronkus Bronkus Sekunder Bronkus Tersier Bronkiolus Lobus Inferior