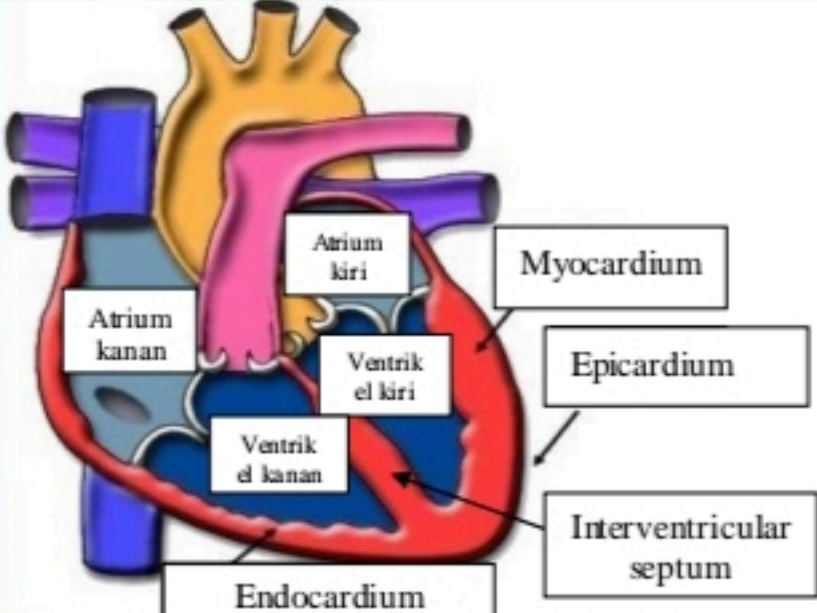
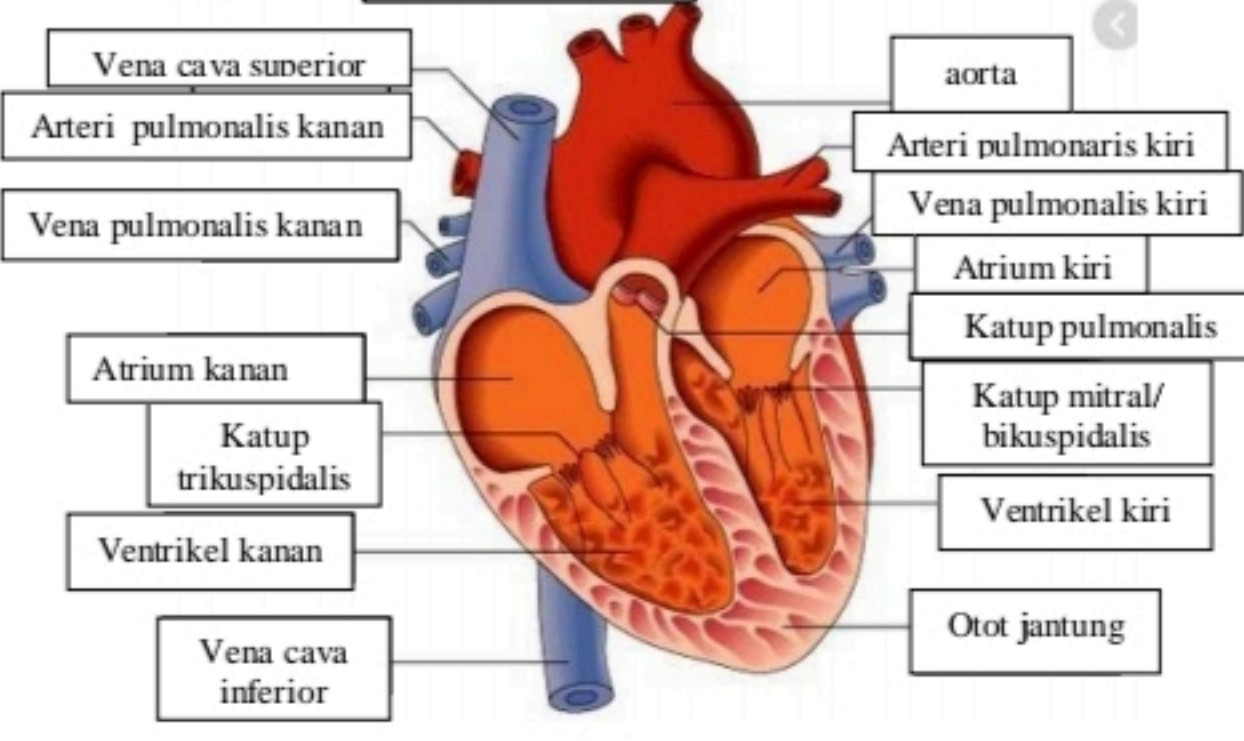
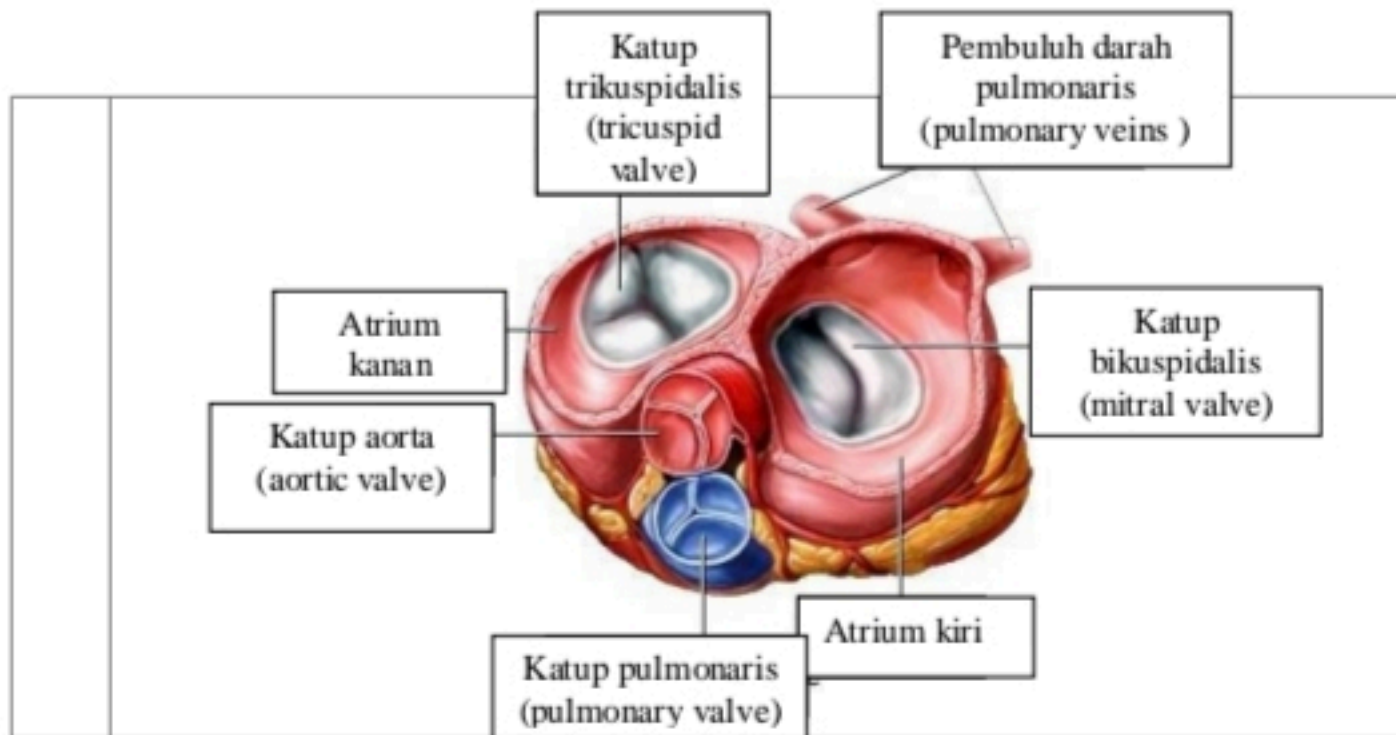


WORKSHEETS (LEMBAR KERJA)

Mata Kuliah	: Anatomi
Materi	: Anatomi Cardiovaskuler
NIM>Nama Mahasiswa	2110101050/ Mila Novika Sari

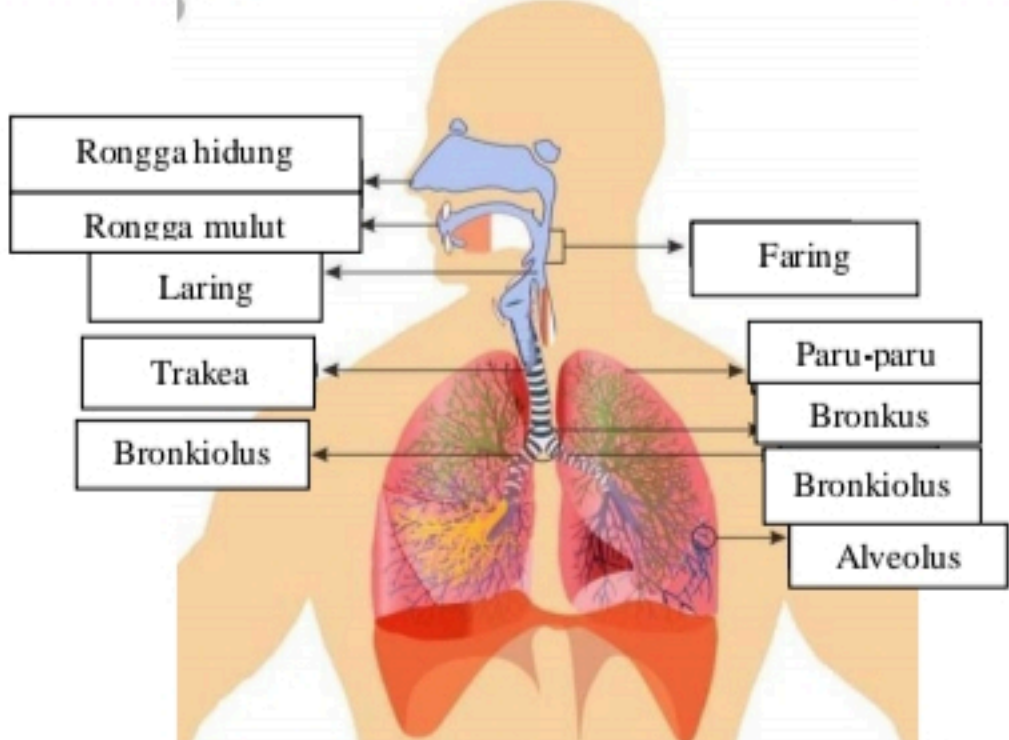
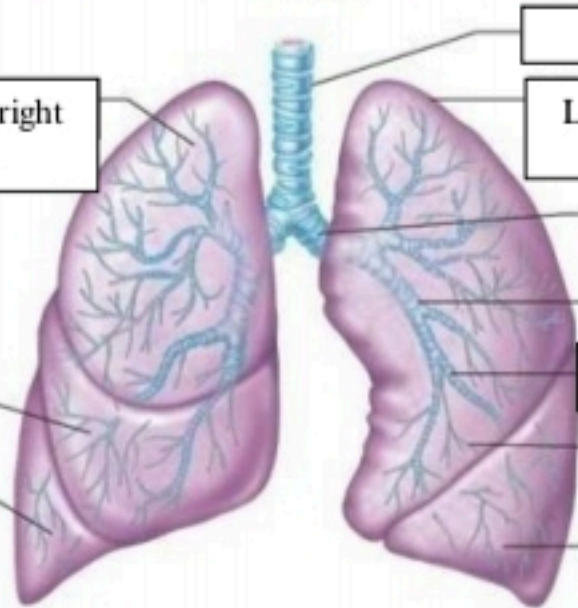
No	Keterangan	Pembahasan
1		 <p>Diagram showing the layers of the heart wall. Labels include: Atrium kiri, Myocardium, Epicardium, Interventricular septum, Endocardium, Atrium kanan, Ventrikel kiri, and Ventrikel kanan.</p>
		 <p>Diagram showing the heart with major vessels and valves. Labels include: Vena cava superior, Arteri pulmonalis kanan, Vena pulmonalis kanan, Atrium kanan, Katup trikuspidalis, Ventrikel kanan, Vena cava inferior, aorta, Arteri pulmonaris kiri, Vena pulmonalis kiri, Atrium kiri, Katup pulmonalis, Katup mitral/bikuspidalis, Ventrikel kiri, and Otot jantung.</p>



WORKSHEETS (LEMBAR KERJA)

Mata Kuliah	: Anatomi
Materi	: Anatomi Respirasi
NIM>Nama Mahasiswa	2110101050/ Mila Novika Sari

No	Keterangan	Pembahasan
1	<p>Anatomical diagram of the human respiratory system showing the airway and lungs. The labels are as follows:</p> <ul style="list-style-type: none"> Faring Rongga hidung Epiglotis Trakea Bronkus Bronkiolus Lobus superior Bronkus Lobus inferior Paru-paru Diafragma 	

No	Keterangan	Pembahasan
		 <p>Diagram of the human respiratory system with labels:</p> <ul style="list-style-type: none"> Rongga hidung Rongga mulut Laring Trakea Bronkiolus Faring Paru-paru Bronkus Bronkiolus Alveolus
	<ul style="list-style-type: none"> Lobus superior/ right upper lobe Lobus medius/ right middle lobe Lobus inferior/ right lower lobe 	 <p>Diagram of the lungs with labels:</p> <ul style="list-style-type: none"> Trakea Lobus superior/ left upper lobe Bronkus Bronkus sekunder Bronkus tersier Bronkiolus Lobus inferior/ left lower lobe

