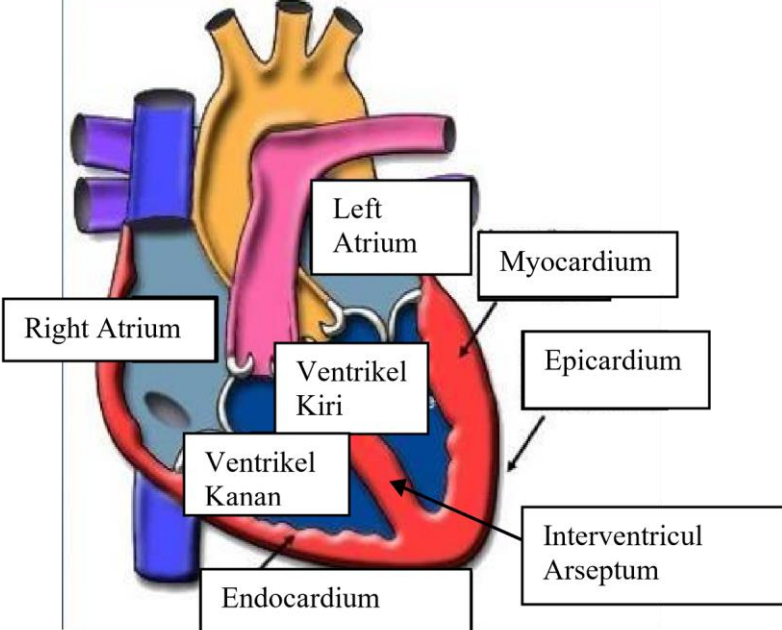
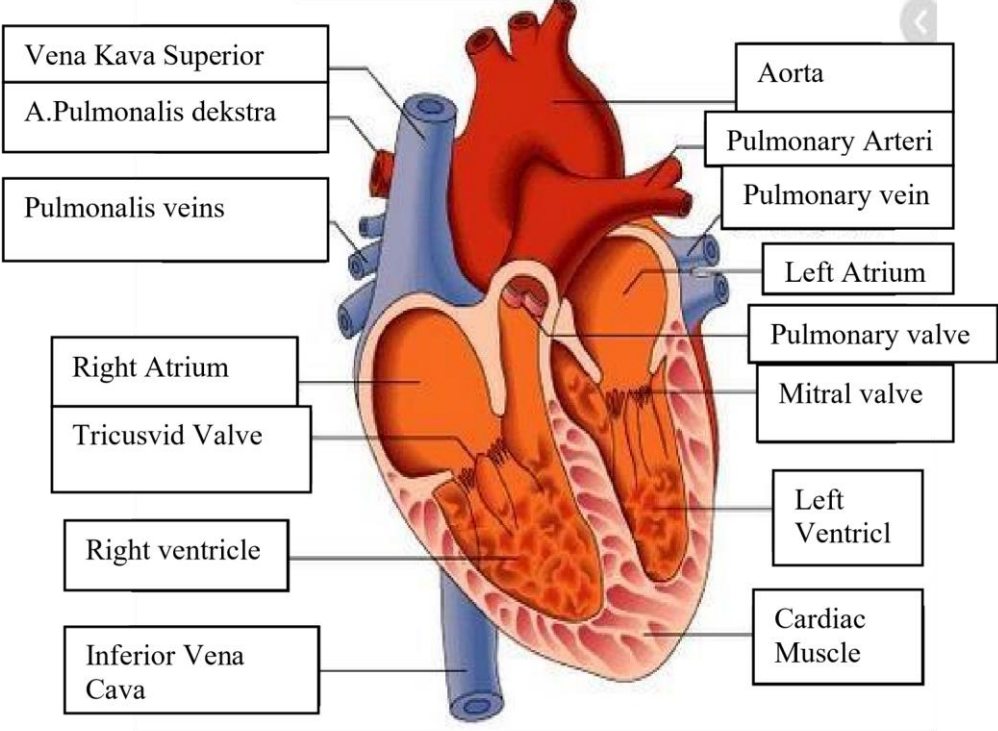


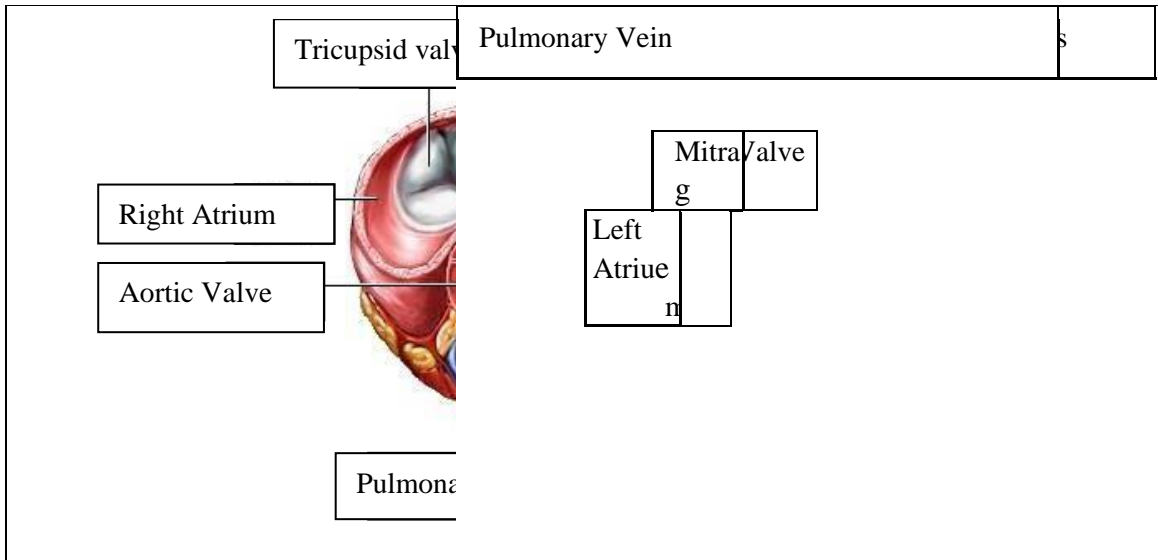
WORKSHEETS (LEMBAR KERJA)

Mata Kuliah	: Anatomi
Materi	: Anatomi Cardiovaskuler
NIM/Nama Mahasiswa	: ANGGITA PUTRI 2110101049

No	Keterangan	Pembahasan
----	------------	------------

1		 <p>This diagram shows a cross-section of the heart wall and its internal chambers. Labels include: Right Atrium, Left Atrium, Myocardium, Epicardium, Endocardium, Ventrikel Kiri (Left Ventricle), Ventrikel Kanan (Right Ventricle), and Interventricular Arseptum (Septum).</p>
---	--	--

<p>Vena Kava Superior</p> <p>A. Pulmonalis dekstra</p> <p>Pulmonalis veins</p> <p>Right Atrium</p> <p>Tricuspid Valve</p> <p>Right ventricle</p> <p>Inferior Vena Cava</p>	 <p>This diagram shows a detailed cross-section of the heart with its major vessels and valves. Labels include: Vena Kava Superior, A. Pulmonalis dekstra, Pulmonalis veins, Right Atrium, Tricuspid Valve, Right ventricle, Inferior Vena Cava, Aorta, Pulmonary Arteri, Pulmonary vein, Left Atrium, Pulmonary valve, Mitral valve, Left Ventricl, and Cardiac Musclev.</p>	<p>Aorta</p> <p>Pulmonary Arteri</p> <p>Pulmonary vein</p> <p>Left Atrium</p> <p>Pulmonary valve</p> <p>Mitral valve</p> <p>Left Ventricl</p> <p>Cardiac Musclev</p>
--	---	--



WORKSHEETS (LEMBAR KERJA)

Mata Kuliah	: Anatomi
Materi	: Anatomi Respirasi
NIM>Nama Mahasiswa	: ANGGITA PUTRI 2110101049

No	Keterangan	Pembahasan
1	<p>Pharynx</p> <p>Esophagus</p> <p>Bronkus</p> <p>Paru Paru Kanan</p> <p>Pleura</p> <p>Nasal Cavity</p> <p>Traches</p> <p>Bronkiolus</p> <p>Bronkus</p> <p>Paru-Paru Kiri</p> <p>Diafragma</p>	

No	Keterangan	Pembahasan
----	------------	------------

