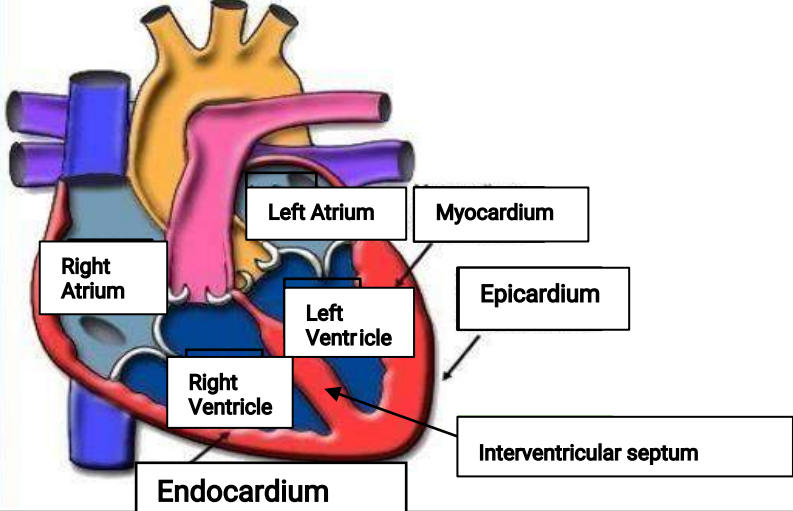
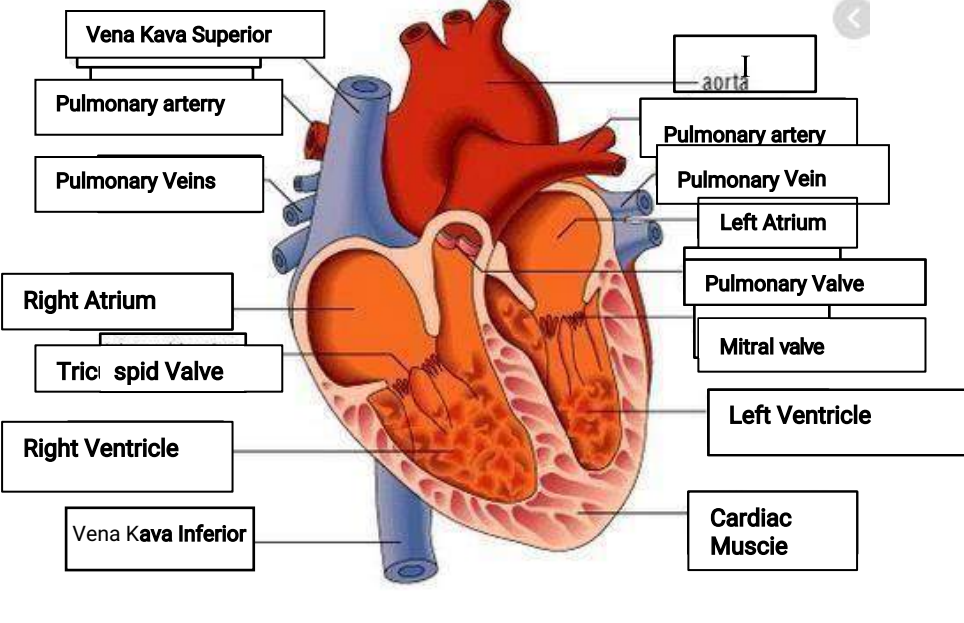
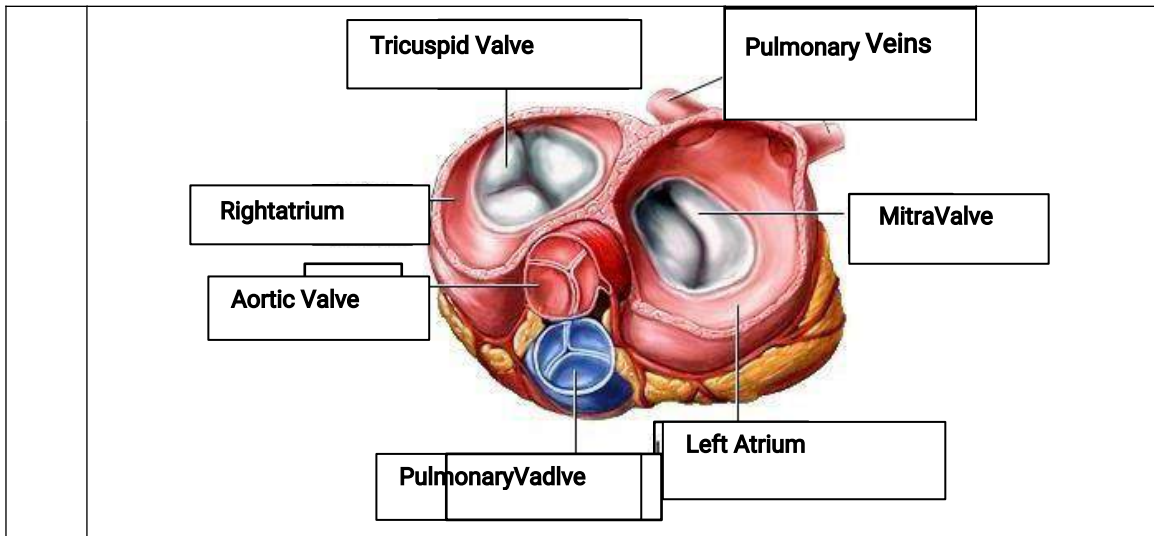


WORKSHEETS (LEMBAR KERJA)

Mata Kuliah	: Anatomi
Materi	: Anatomi Cardiovaskuler
NIM>Nama Mahasiswa	: 2110101046/Oktaviana Rahmawati

No	Keterangan	Pembahasan
1		
		



WORKSHEETS (LEMBAR KERJA)

Mata Kuliah	: Anatomi
Materi	: Anatomi Respirasi
NIM>Nama Mahasiswa	: 2110101046/Oktaviana Rahmawati

No	Keterangan	Pembahasan
1	<p>An anatomical diagram of the human respiratory system. It shows the nasal cavity (Rongga Hidung), pharynx (Faring), larynx (Laring), trachea (Trakea), bronchi (Bronkus), bronchioles (Bronkiolus), and lungs (Paru-Parukanan). The left lung (Paru-Paru kiri) is specifically labeled. The pleura (Pleura) is shown surrounding the lungs, and the diaphragm (Diafragma) is at the base. The diagram is color-coded to show the airway structure.</p>	

No	Keterangan	Pembahasan
----	------------	------------

