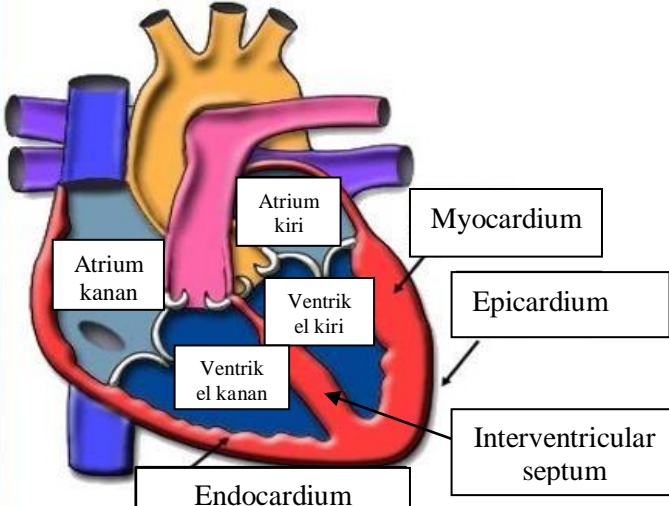
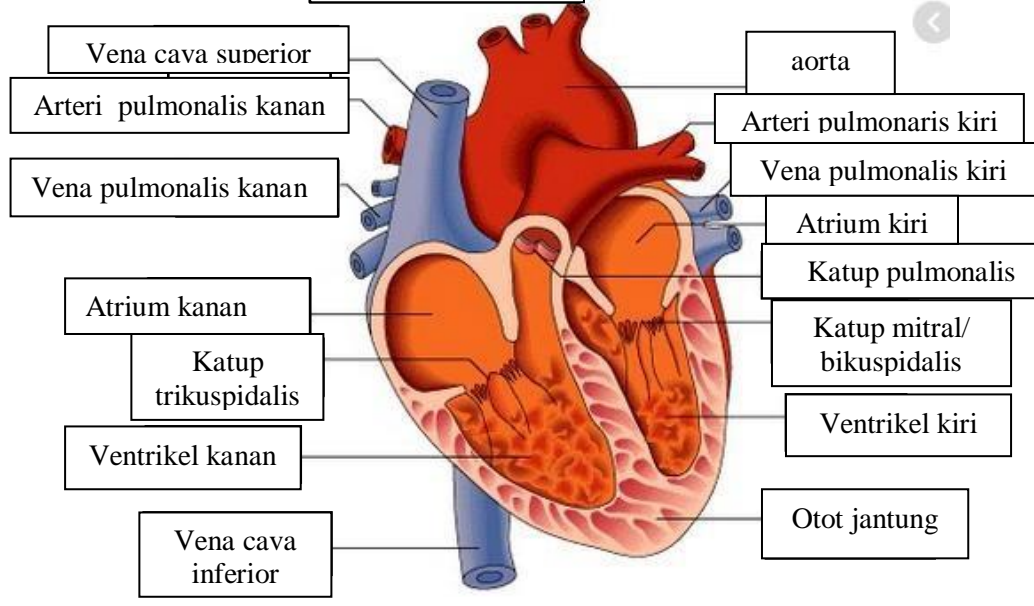
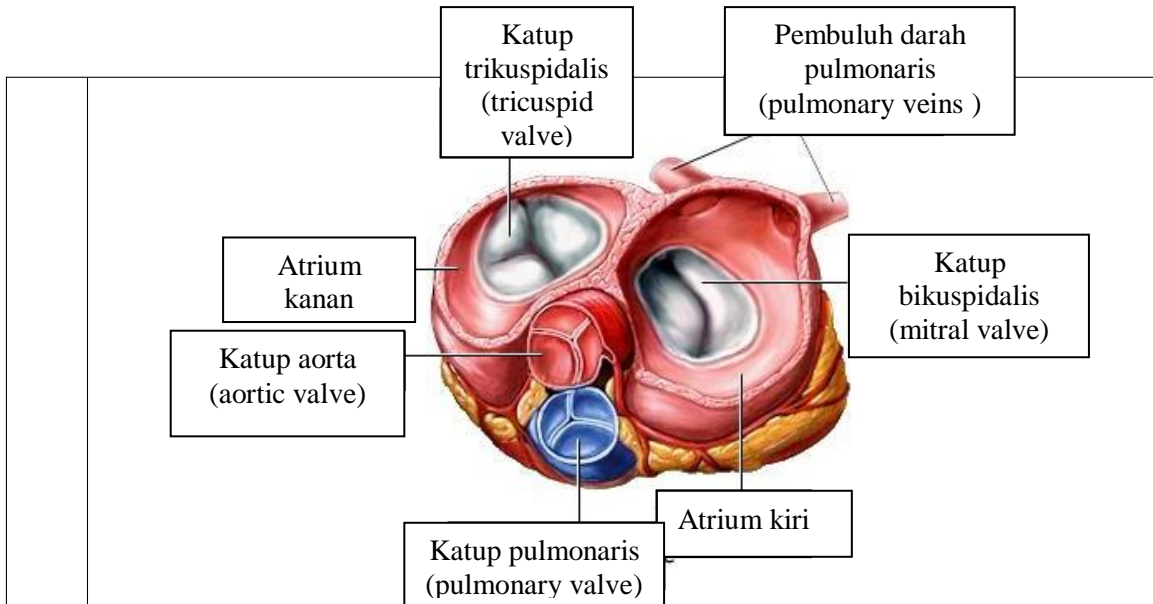


**WORKSHEETS (LEMBAR KERJA)**

|                              |  |
|------------------------------|--|
| <b>Mata Kuliah</b>           | : <b>Anatomi</b>                         |
| <b>Materi</b>                | : <b>Anatomi Cardiovaskuler</b>          |
| <b>NIM&gt;Nama Mahasiswa</b> | : <b>2110101044/Irma misbahul jannah</b> |

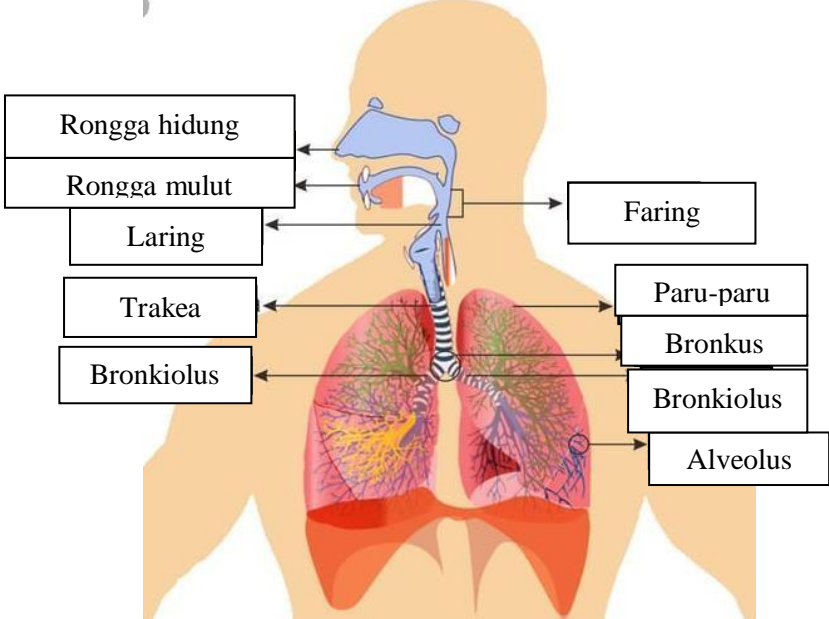
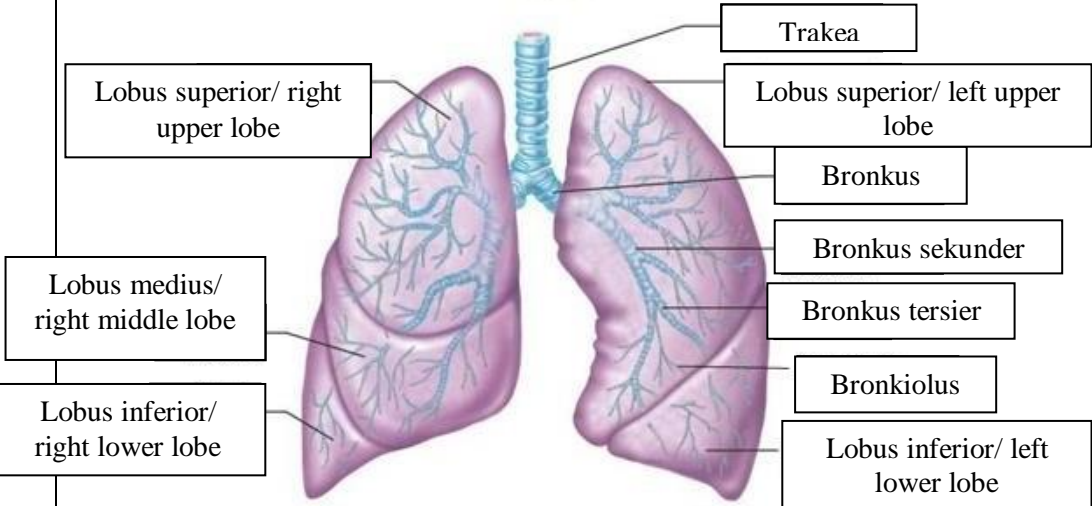
| No | Keterangan | Pembahasan   |
|----|------------|--|
| 1  |            |    |
|    |            |  |



**WORKSHEETS (LEMBAR KERJA)**

|                              |                                   |
|------------------------------|-----------------------------------|
| <b>Mata Kuliah</b>           | : Anatomi                         |
| <b>Materi</b>                | : Anatomi Respirasi               |
| <b>NIM&gt;Nama Mahasiswa</b> | : 2110101044/Irma misbahul jannah |

| No | Keterangan   | Pembahasan |
|----|--|------------|
| 1  | <p>Anatomical diagram of the human respiratory system showing the airway and lungs. The labels are as follows:</p> <ul style="list-style-type: none"> <li>Faring</li> <li>Rongga hidung</li> <li>Epiglottis</li> <li>Trakea</li> <li>Bronkus</li> <li>Bronkiolus</li> <li>Lobus superior</li> <li>Bronkus</li> <li>Paru-paru</li> <li>Lobus inferior</li> <li>Diafragma</li> </ul> |            |

| No | Keterangan | Pembahasan   |
|----|------------|--|
|    |            |  <p>Diagram of the human respiratory system with labels:</p> <ul style="list-style-type: none"> <li>Rongga hidung</li> <li>Rongga mulut</li> <li>Laring</li> <li>Trakea</li> <li>Bronkiolus</li> <li>Faring</li> <li>Paru-paru</li> <li>Bronkus</li> <li>Bronkiolus</li> <li>Alveolus</li> </ul>   |
|    |            |  <p>Diagram of the lungs with labels:</p> <ul style="list-style-type: none"> <li>Lobus superior/ right upper lobe</li> <li>Lobus medius/ right middle lobe</li> <li>Lobus inferior/ right lower lobe</li> <li>Trakea</li> <li>Lobus superior/ left upper lobe</li> <li>Bronkus</li> <li>Bronkus sekunder</li> <li>Bronkus tersier</li> <li>Bronkiolus</li> <li>Lobus inferior/ left lower lobe</li> </ul> |

