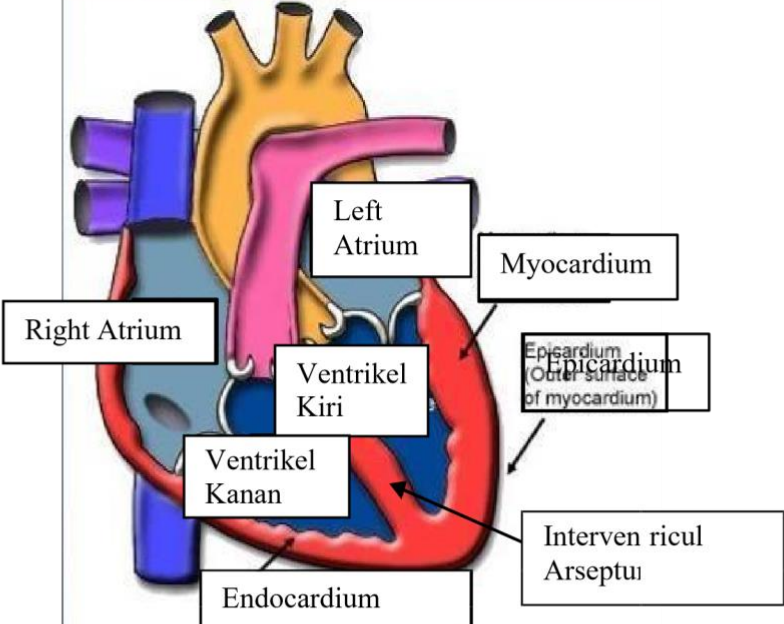
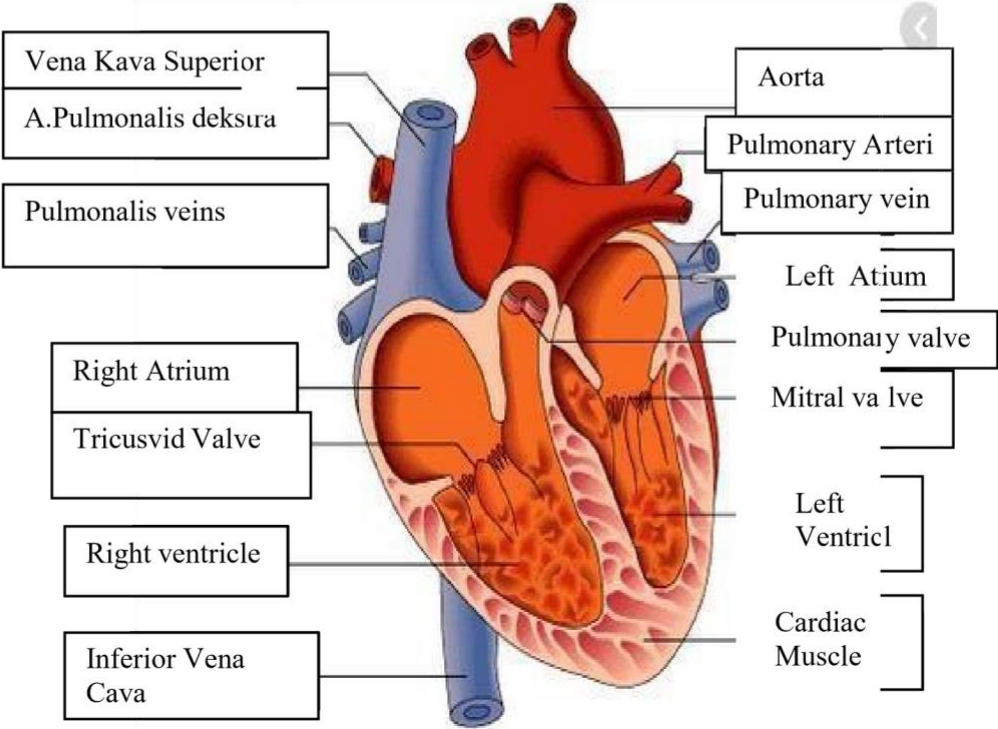
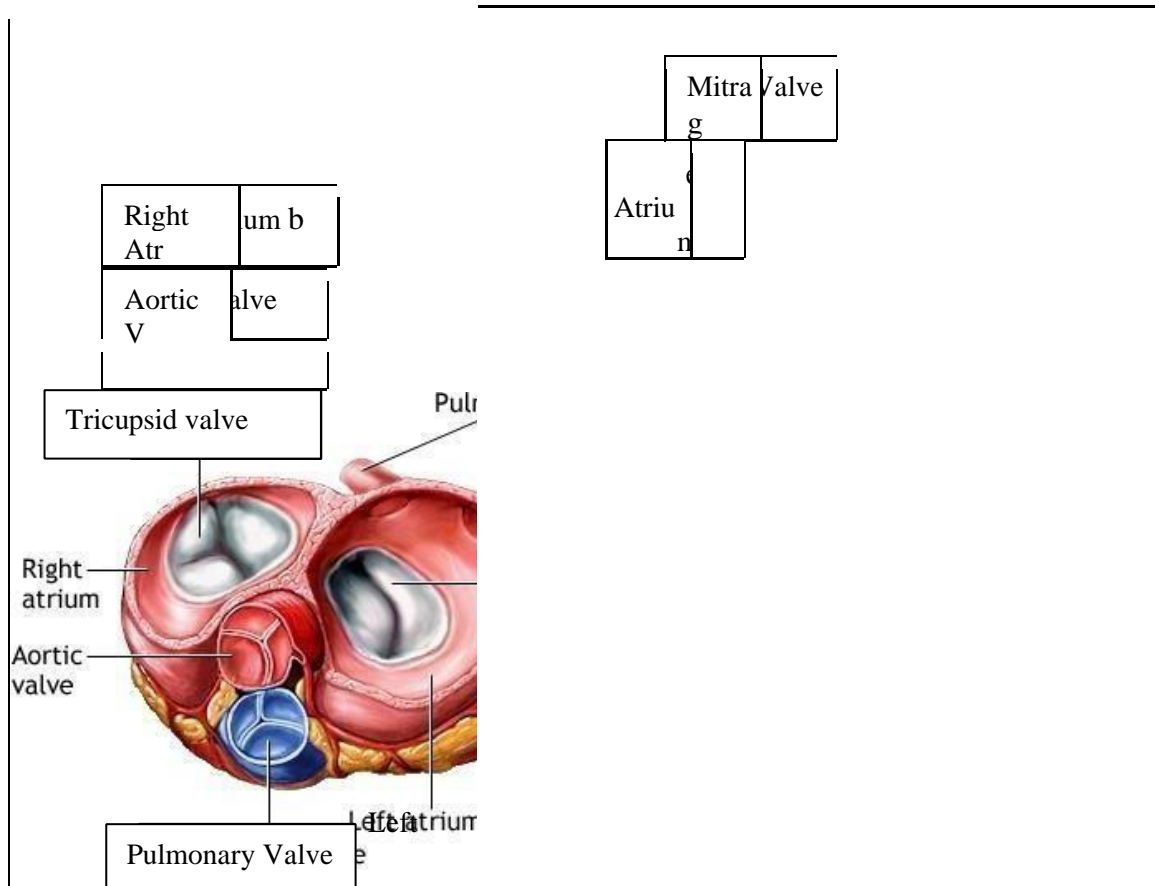


**WORKSHEETS (LEMBAR KERJA)**

<b>Mata Kuliah</b>	<b>: Anatomi</b>
<b>Materi</b>	<b>: Anatomi Cardiovasuler</b>
<b>NIM/Nama Mahasiswa</b>	<b>: 2110101043 / Rike Yulianti</b>

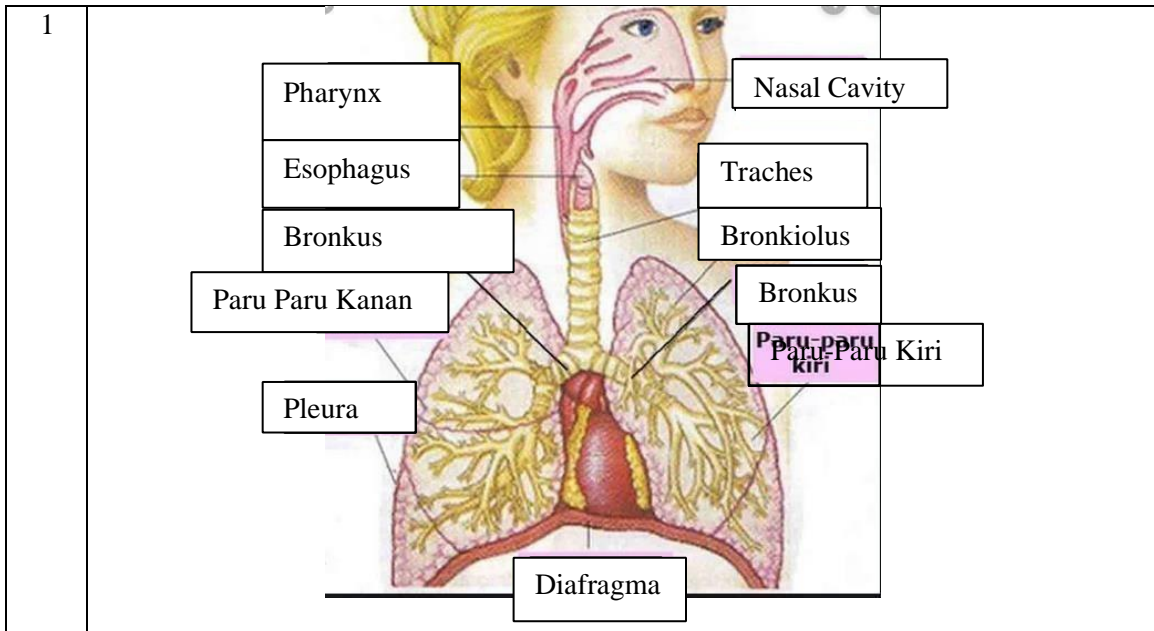
No	Keterangan	Pembahasan
1		 <p>Labels in diagram:</p> <ul style="list-style-type: none"> <li>Left Atrium</li> <li>Right Atrium</li> <li>Ventrikel Kiri</li> <li>Ventrikel Kanan</li> <li>Myocardium</li> <li>Endocardium</li> <li>Episardium (Outer surface of myocardium)</li> <li>Interven ricul Arseptu</li> </ul>
	 <p>Labels on the left side:</p> <ul style="list-style-type: none"> <li>Vena Kava Superior</li> <li>A.Pulmonalis dekstra</li> <li>Pulmonalis veins</li> <li>Right Atrium</li> <li>Tricuspid Valve</li> <li>Right ventricle</li> <li>Inferior Vena Cava</li> </ul> <p>Labels on the right side:</p> <ul style="list-style-type: none"> <li>Aorta</li> <li>Pulmonary Arteri</li> <li>Pulmonary vein</li> <li>Left Atrium</li> <li>Pulmonary valve</li> <li>Mitral valve</li> <li>Left Ventricl</li> <li>Cardiac Muscle</li> </ul>	
	Pulmonary Vein	s



### WORKSHEETS (LEMBAR KERJA)

<b>Mata Kuliah</b>	<b>: Anatomi</b>
<b>Materi</b>	<b>: Anatomi Respirasi</b>
<b>NIM&gt;Nama Mahasiswa</b>	<b>: 2110101043 / Rike Yulianti</b>

No	Keterangan	Pembahasan
----	------------	------------



No	Keterangan	Pembahasan
----	------------	------------

