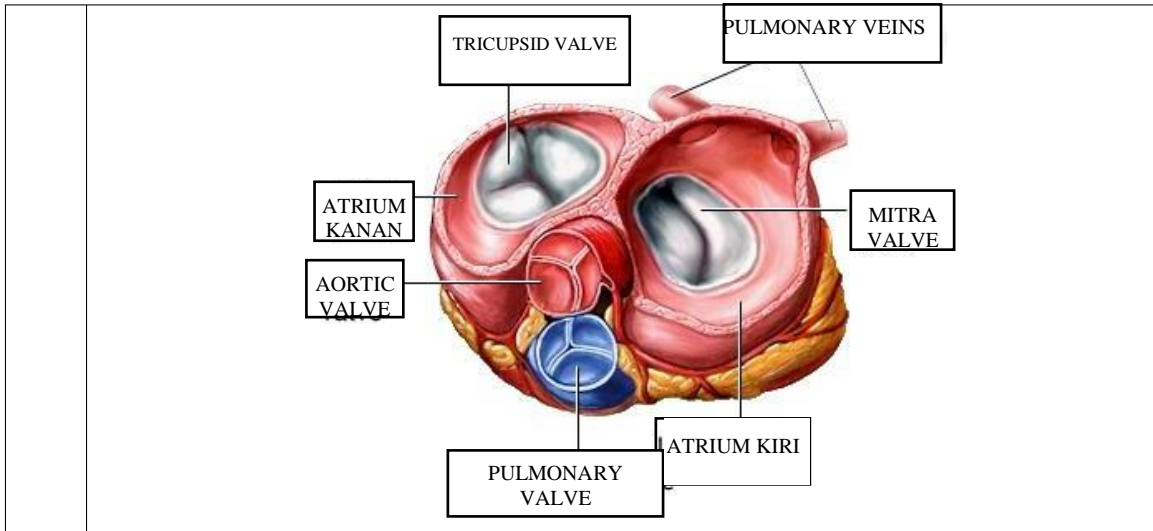


**WORKSHEETS (LEMBAR KERJA)**

<b>Mata Kuliah</b>	: <b>Anatomi</b>
<b>Materi</b>	: <b>Anatomi Cardiovaskuler</b>
<b>NIM&gt;Nama Mahasiswa</b>	: 2110101106/Fatimah Azzahra

No	Keterangan	Pembahasan
1		



**WORKSHEETS (LEMBAR KERJA)**

<b>Mata Kuliah</b>	: Anatomi
<b>Materi</b>	: Anatomi Respirasi
<b>NIM&gt;Nama Mahasiswa</b>	:

No	Keterangan	Pembahasan
1	<p>Diagram of the human respiratory system showing the following labeled parts: FARING, LARING, BRONKUS, PARUPARU KANAN, PLEURA, DIAFRAGMA, Rongga RONGGA HIDUNG, TRAKEA, BRONKIOLUS, BRONKUS, and PARUPARU KIRI. Letters 'a' and 'c' are also present near the pharynx and larynx respectively.</p>	

No	Keterangan	Pembahasan
----	------------	------------

