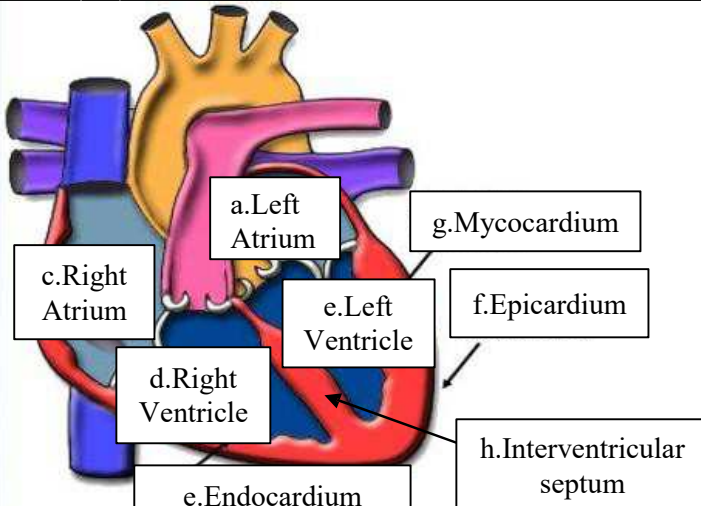
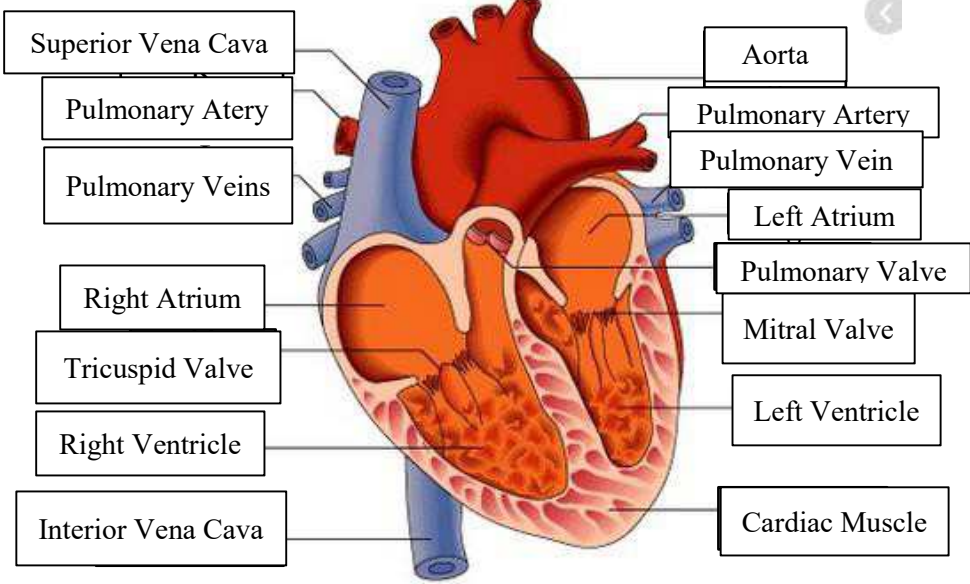
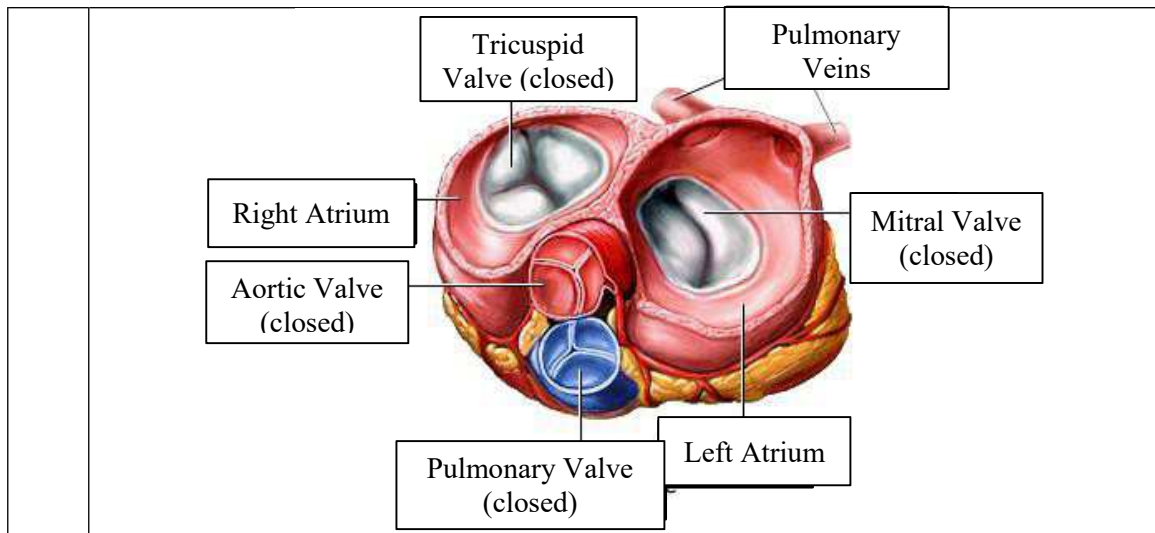


WORKSHEETS (LEMBAR KERJA)

Mata Kuliah	: Anatomi
Materi	: Anatomi Cardiovaskuler
NIM>Nama Mahasiswa	: 2110101024/INTAN LAROIBA KHURIJATI HAJID.

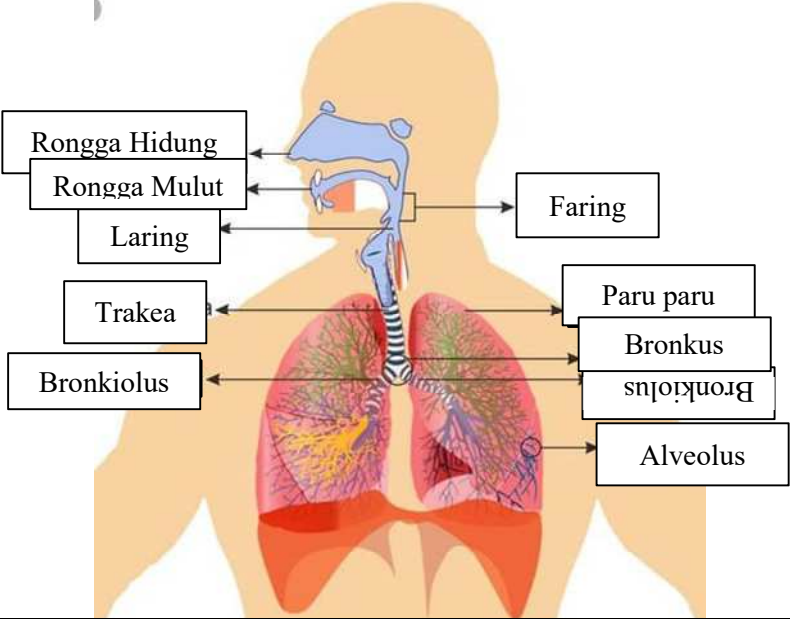
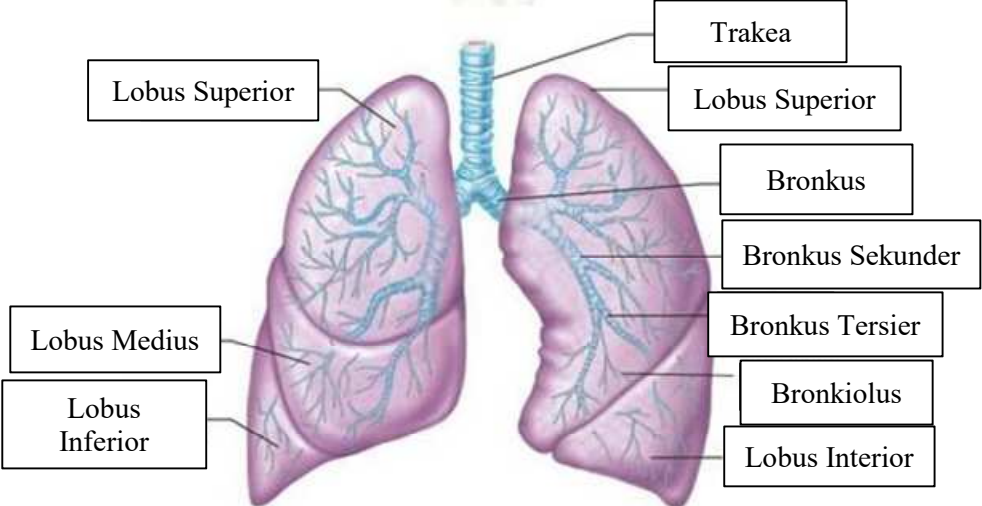
No	Keterangan	Pembahasan
1		
		



WORKSHEETS (LEMBAR KERJA)

Mata Kuliah	: Anatomi
Materi	: Anatomi Respirasi
NIM>Nama Mahasiswa	: 2110101024/INTAN LAROIBA KHURIJATI HAJID.

No	Keterangan	Pembahasan
1		<p>An anatomical diagram of the human respiratory system. It shows the nasal cavity (Rongga Hidung) leading to the pharynx (Faring), larynx (Laring), and trachea (Trakea). The trachea branches into bronchi (Bronkus) and bronchioles (Bronkiolus), which lead to the right lung (Paru paru Kanan) and left lung (Paru paru Kiri). The lungs are surrounded by the pleura (Pleura). The diaphragm (Diafragma) is shown at the base of the thoracic cavity. Labels with leader lines point to each of these structures.</p>

No	Keterangan	Pembahasan
		 <p>Diagram of the human respiratory system with the following labels:</p> <ul style="list-style-type: none"> Rongga Hidung Rongga Mulut Laring Trakea Bronkiolus Faring Paru paru Bronkus Bronkiolus Alveolus
		 <p>Detailed diagram of the lungs with the following labels:</p> <ul style="list-style-type: none"> Lobus Superior Lobus Medius Lobus Inferior Trakea Lobus Superior Bronkus Bronkus Sekunder Bronkus Tersier Bronkiolus Lobus Interior

