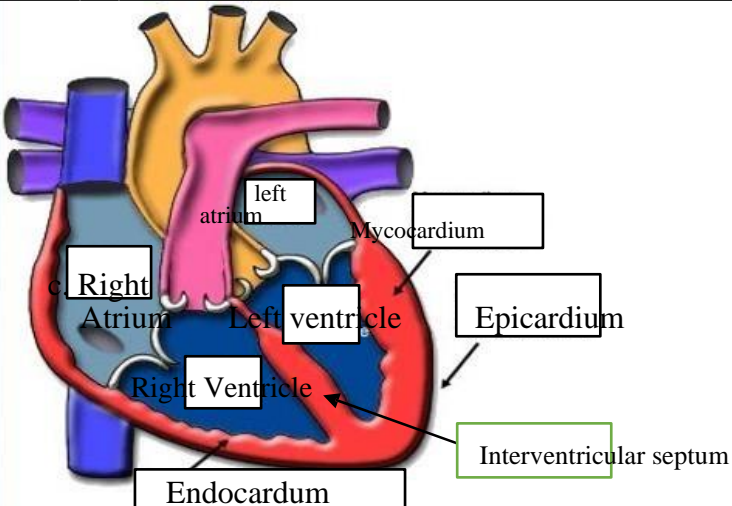
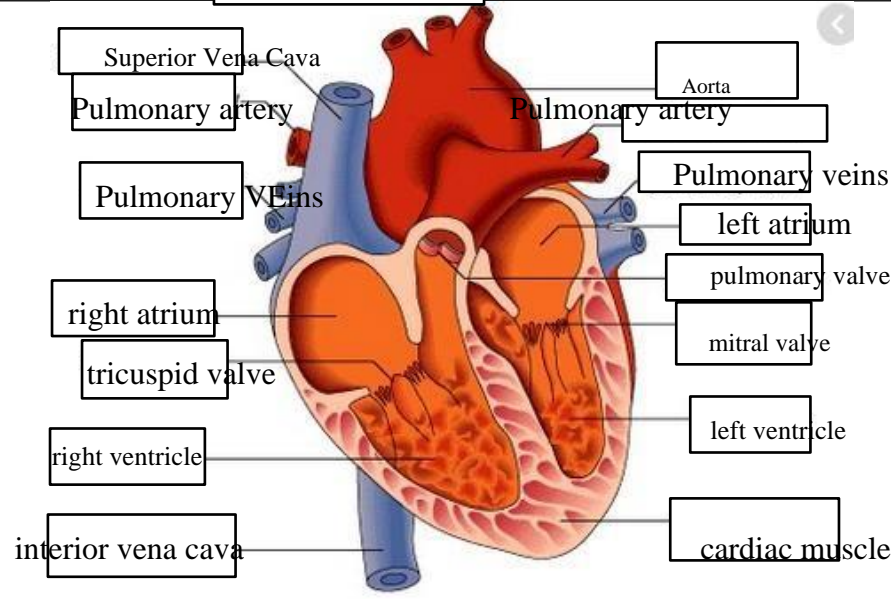
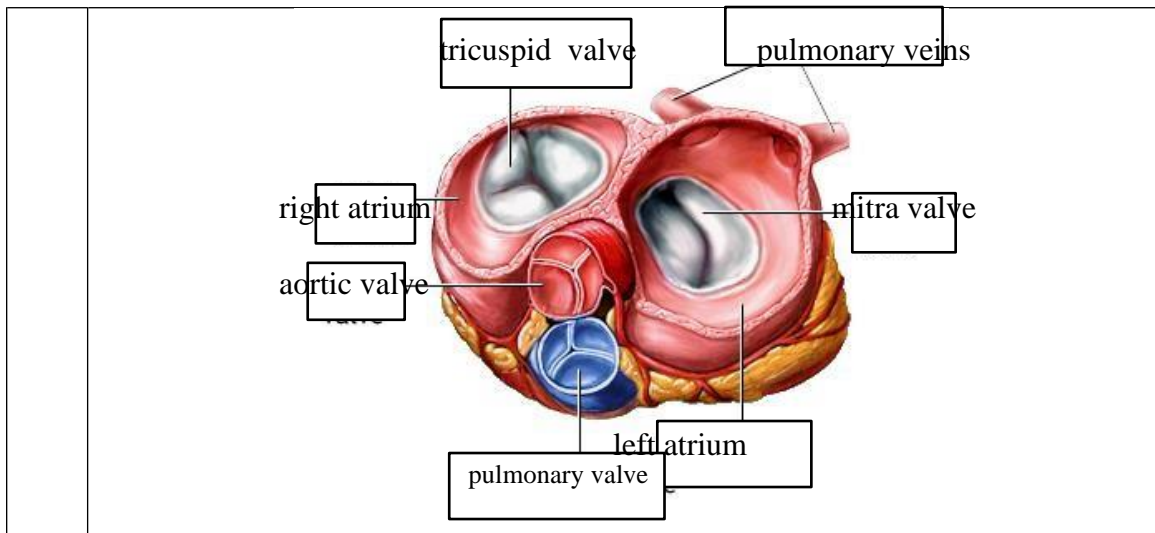


**WORKSHEETS (LEMBAR KERJA)**

<b>Mata Kuliah</b>	: <b>Anatomi</b>
<b>Materi</b>	: <b>Anatomi Cardiovaskuler</b>
<b>NIM&gt;Nama Mahasiswa</b>	: <b>PUTRI WAHYUNING PANGESTI 2110101027</b>

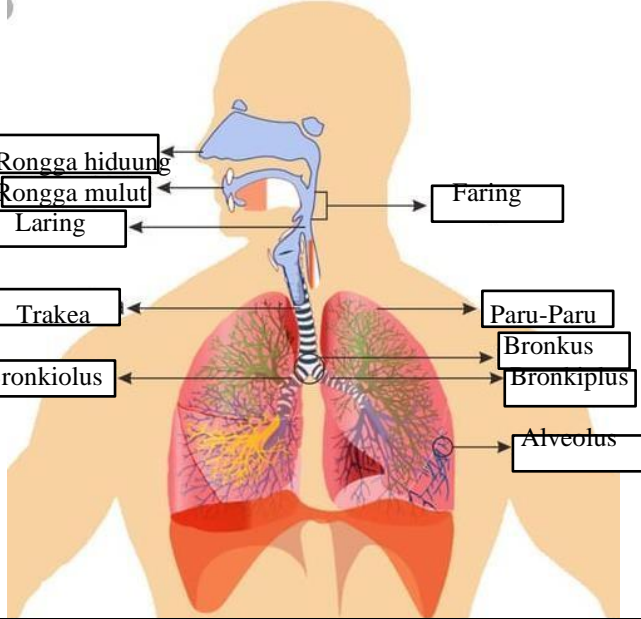
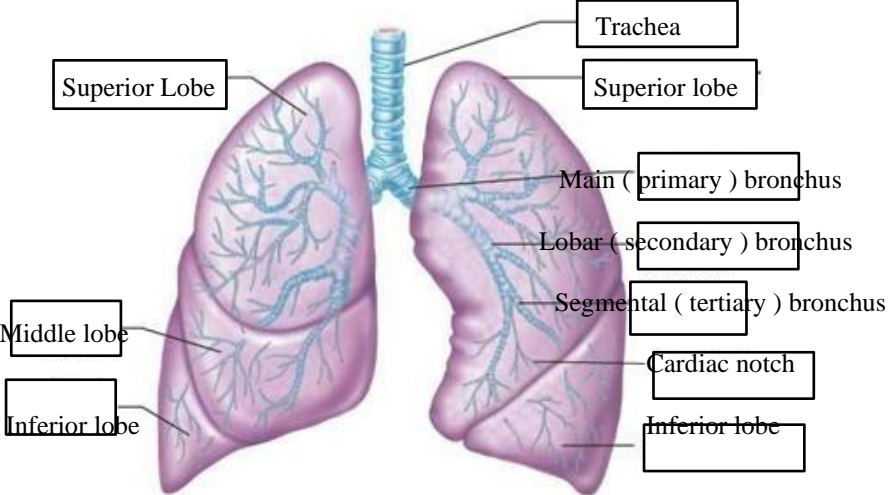
No	Keterangan	Pembahasan
1		
		



**WORKSHEETS (LEMBAR KERJA)**

<b>Mata Kuliah</b>	: <b>Anatomi</b>
<b>Materi</b>	: <b>Anatomi Respirasi</b>
<b>NIM&gt;Nama Mahasiswa</b>	: <b>2110101027 PUTRI WAHYUNING PANGESTI</b>

No	Keterangan	Pembahasan
1	<p>Diagram of the human respiratory system. Labels include: pharynx hidung, esophagus, bronkus, paru-paru kanan, pleura, nasal cavity, traches, bronkiolus, bronkus, paru-paru kiri, and Diafragma.</p>	

No	Keterangan	Pembahasan
		 <p>Diagram of the human respiratory system with labels:</p> <ul style="list-style-type: none"> <li>Rongga hidung</li> <li>Rongga mulut</li> <li>Laring</li> <li>Trakea</li> <li>Bronkiolus</li> <li>Faring</li> <li>Paru-Paru</li> <li>Bronkus</li> <li>Bronkiplus</li> <li>Alveolus</li> </ul>
		 <p>Detailed anatomical diagram of the lungs with labels:</p> <ul style="list-style-type: none"> <li>Trachea</li> <li>Superior Lobe</li> <li>Middle lobe</li> <li>Inferior lobe</li> <li>Superior lobe</li> <li>Main (primary) bronchus</li> <li>Lobar (secondary) bronchus</li> <li>Segmental (tertiary) bronchus</li> <li>Cardiac notch</li> <li>Inferior lobe</li> </ul>

