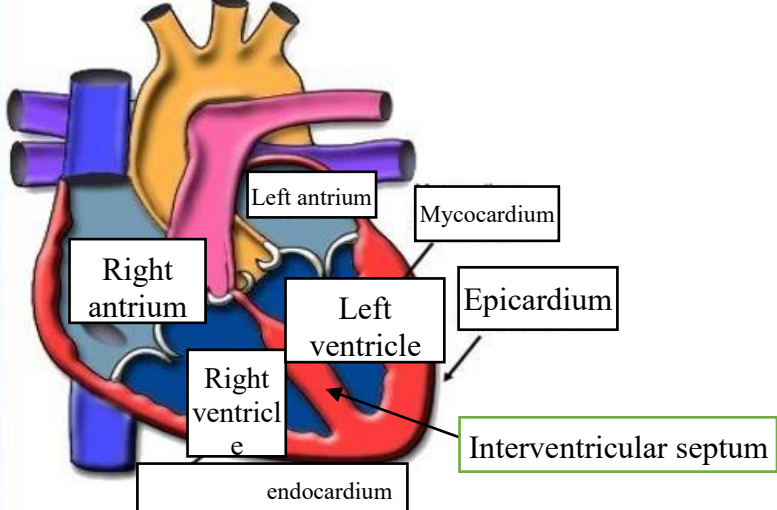
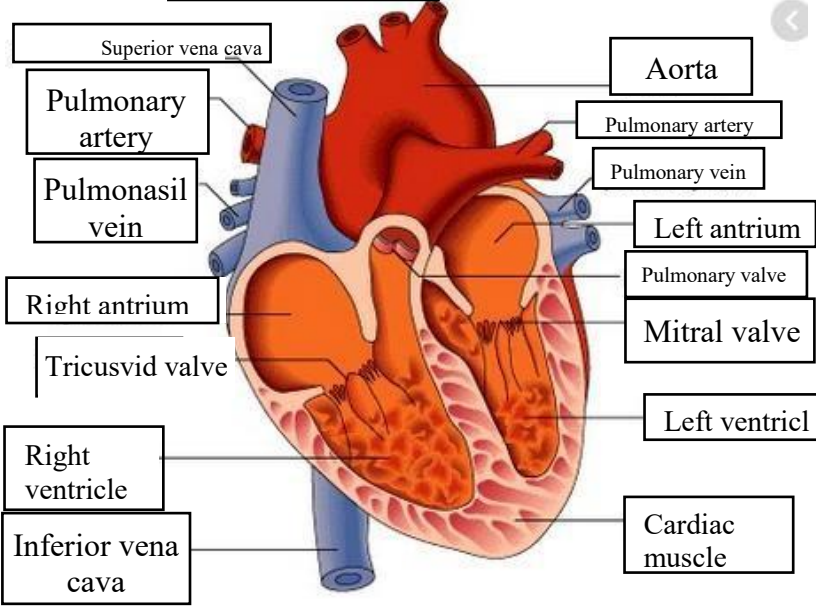
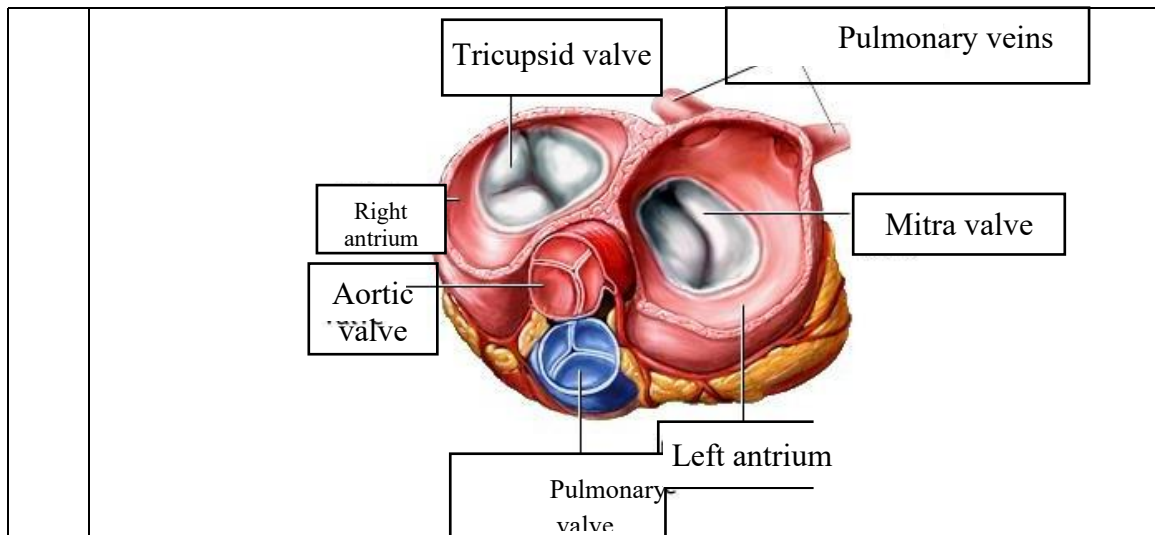


WORKSHEETS (LEMBAR KERJA)

Mata Kuliah	: Anatomi
Materi	: Anatomi Cardiovaskuler
NIM>Nama Mahasiswa	: 2110101028/ LEDY SUPRIHATIN

No	Keterangan	Pembahasan
1		 <p>This diagram shows a cross-section of the heart wall and its chambers. The layers of the heart wall are labeled as follows: Myocardium (the middle layer), Epicardium (the outer layer), and Endocardium (the inner layer). The chambers shown are the Right atrium, Right ventricle, Left atrium, and Left ventricle. The Interventricular septum is also indicated, separating the right and left ventricles.</p>
		 <p>This diagram shows a cross-section of the heart with its major vessels and valves. The vessels shown are the Superior vena cava, Pulmonary artery, Pulmonary vein, Inferior vena cava, and Aorta. The valves shown are the Tricuspid valve, Pulmonary valve, and Mitral valve. The chambers shown are the Right atrium, Right ventricle, Left atrium, and Left ventricle. The Cardiac muscle is also labeled.</p>



WORKSHEETS (LEMBAR KERJA)

Mata Kuliah	: Anatomi
Materi	: Anatomi Respirasi
NIM>Nama Mahasiswa	: 2110101028/ LEDY SUPRIHATIN

No	Keterangan	Pembahasan
1	<p>An anatomical diagram of the human respiratory system. Labels include: Pharynx, Esophagus, Bronkus, Paru paru kanan, pleura, Nasal cavity, Traches, Bronkiolus, Bronkus, Paru paru kiri, and Diafragma.</p>	

No	Keterangan	Pembahasan
----	------------	------------

