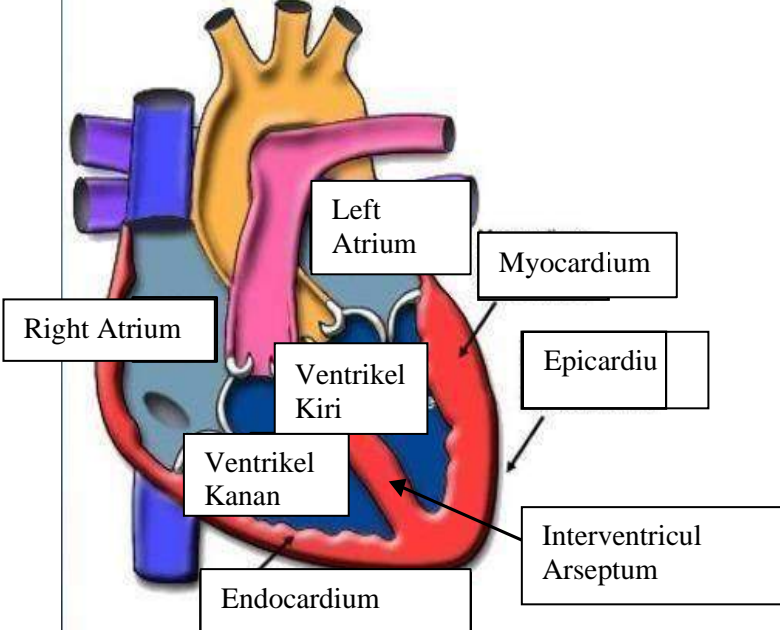
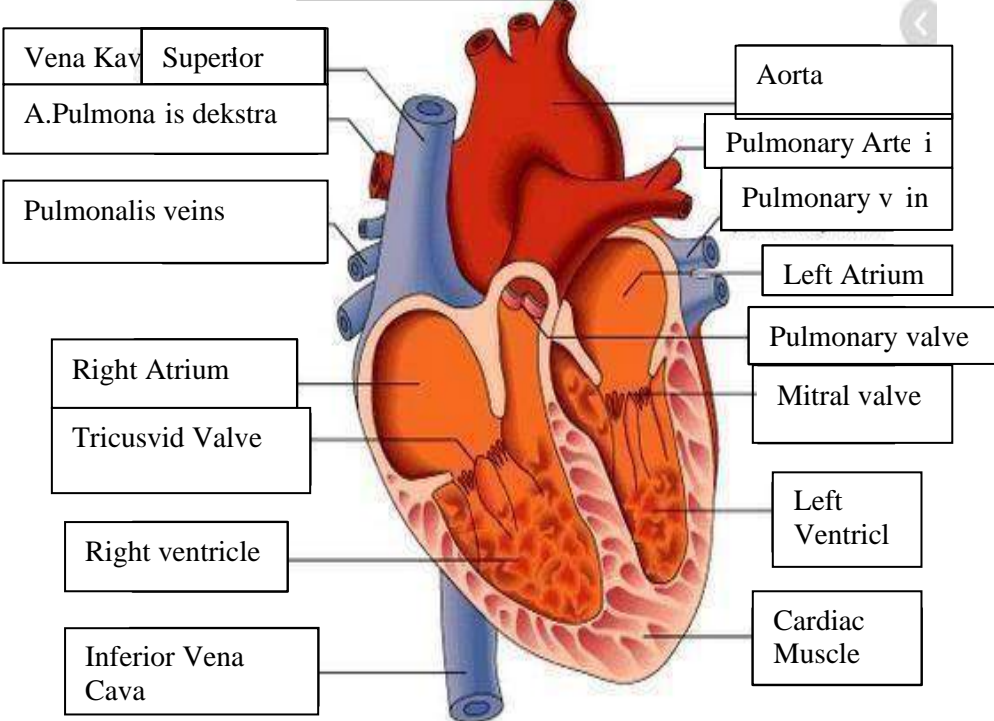
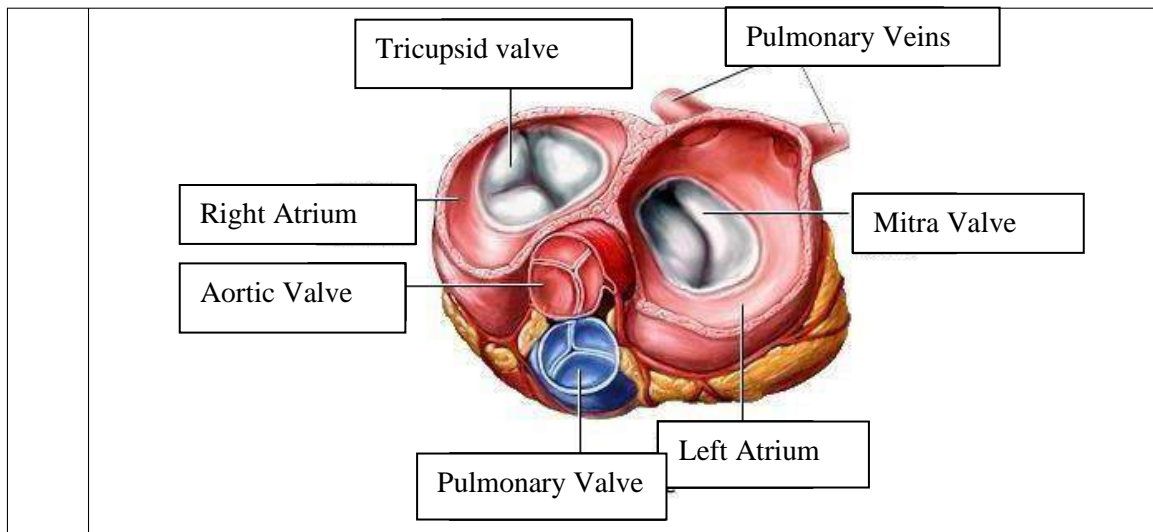


WORKSHEETS (LEMBAR KERJA)

Mata Kuliah	: Anatomi
Materi	: Anatomi Cardiovaskuler
NIM/Nama Mahasiswa	: 2110101005/ Rhani Rosalina

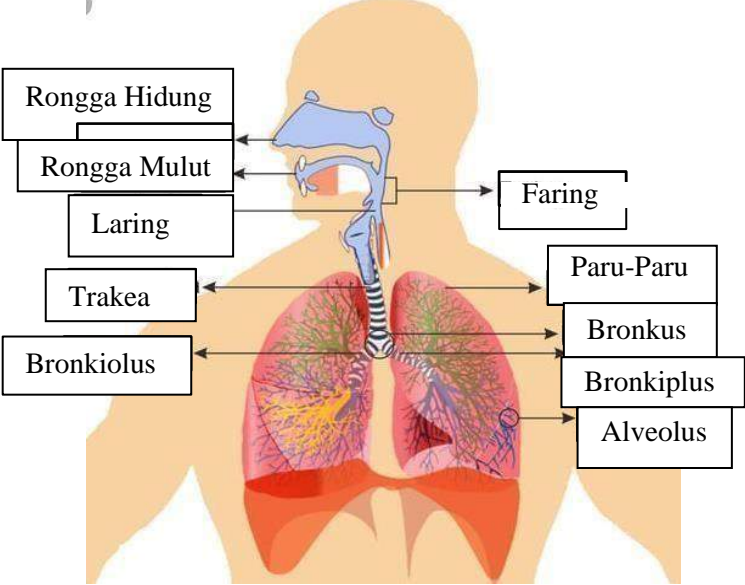
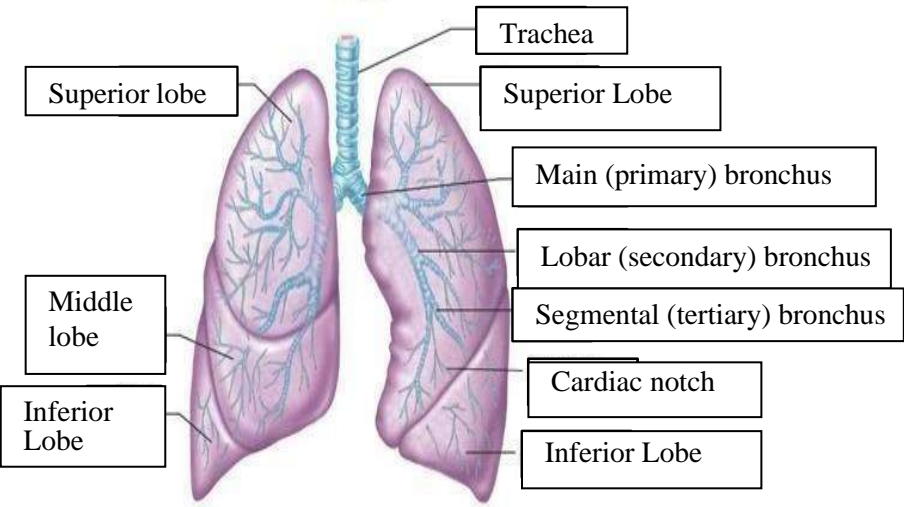
No	Keterangan	Pembahasan
1		 <p>This diagram shows a cross-section of the heart wall and its internal chambers. Labels include: Right Atrium, Left Atrium, Ventrikel Kiri (Left Ventricle), and Ventrikel Kanan (Right Ventricle). The wall layers are labeled as Endocardium (innermost), Myocardium (middle), and Epicardium (outermost). The Interventricular Arseptum (Septum) is also shown.</p>
	<p>Vena Kav Superior</p> <p>A. Pulmonalis dekstra</p> <p>Pulmonalis veins</p> <p>Right Atrium</p> <p>Tricuspid Valve</p> <p>Right ventricle</p> <p>Inferior Vena Cava</p>	 <p>This diagram shows the heart with its major blood vessels and valves. Labels include: Aorta, Pulmonary Arteri (Pulmonary Artery), Pulmonary v in (Pulmonary Vein), Left Atrium, Pulmonary valve, Mitral valve, Left Ventricl (Left Ventricle), Cardiac Muscle, Right Atrium, Tricuspid Valve, Right ventricle, and Inferior Vena Cava.</p>



WORKSHEETS (LEMBAR KERJA)

Mata Kuliah	: Anatomi
Materi	: Anatomi Respirasi
NIM>Nama Mahasiswa	: 2110101005/ Rhani Rosalina

No	Keterangan	Pembahasan
1	<p>An anatomical diagram of the human respiratory system. Labels include: Pharynx, Esophagus, Bronkus, Paru Paru Kanan, Pleura, Nasal Cavity, Traches, Bronkiolus, Bronkus, Paru-Paru Kiri, and Diafragma. The diagram shows the airway from the nasal cavity down to the lungs, which are divided into right and left lobes, and the diaphragm at the base.</p>	

No	Keterangan	Pembahasan
		 <p>Diagram of the human respiratory system with labels:</p> <ul style="list-style-type: none"> Rongga Hidung Rongga Mulut Laring Trakea Bronkiolus Faring Paru-Paru Bronkus Bronkiplus Alveolus
		 <p>Detailed diagram of the lungs with labels:</p> <ul style="list-style-type: none"> Superior lobe Middle lobe Inferior Lobe Trachea Superior Lobe Main (primary) bronchus Lobar (secondary) bronchus Segmental (tertiary) bronchus Cardiac notch Inferior Lobe

