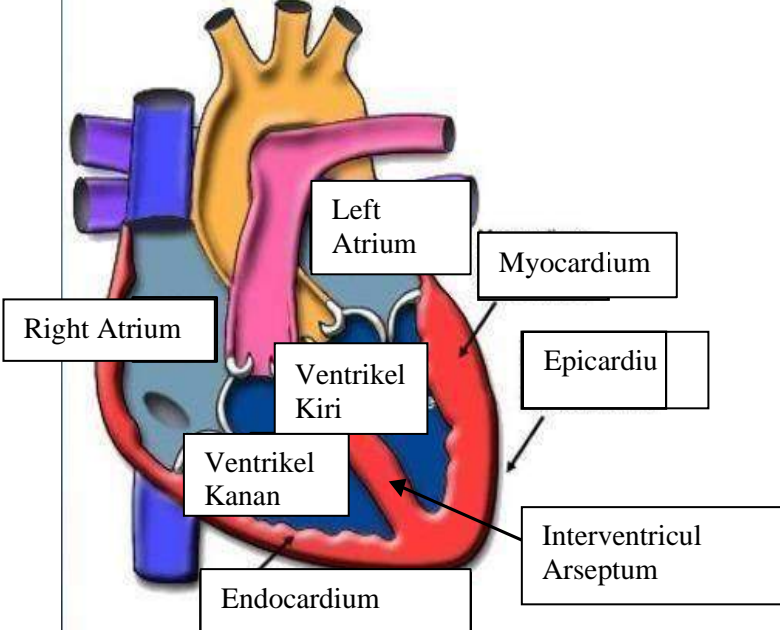
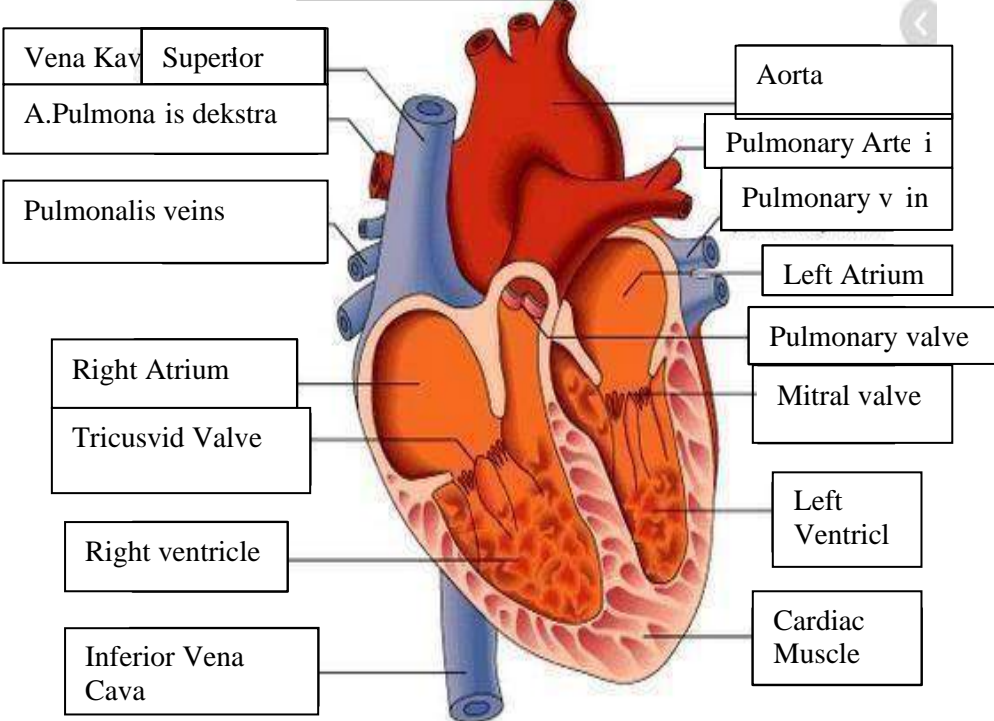
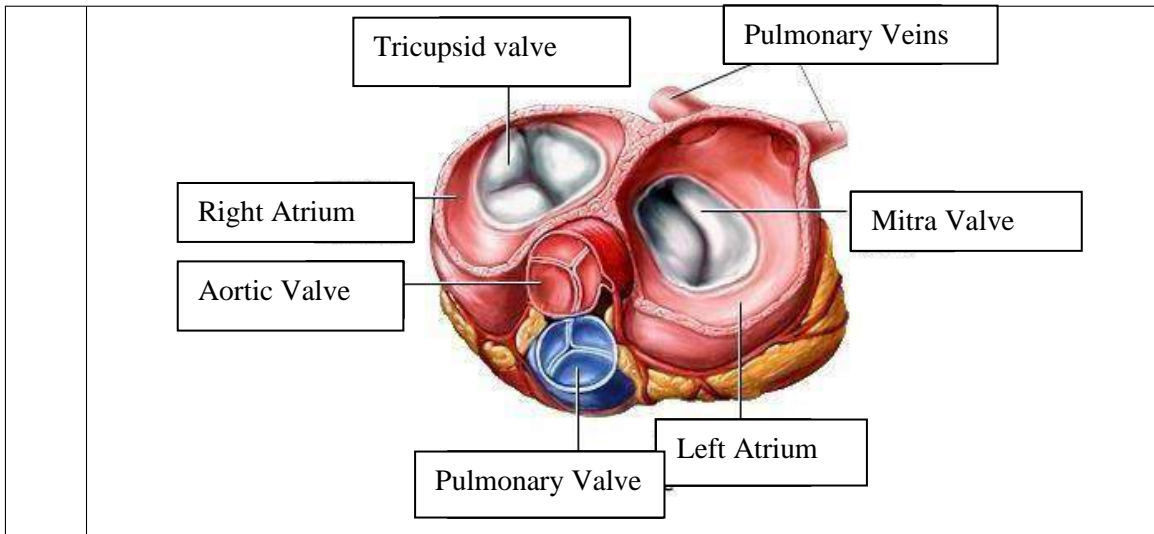


**WORKSHEETS (LEMBAR KERJA)**

<b>Mata Kuliah</b>	: <b>Anatomi</b>
<b>Materi</b>	: <b>Anatomi Cardiovaskuler</b>
<b>NIM/Nama Mahasiswa</b>	: <b>2110101001/SHAFIRDA INAYATI</b>

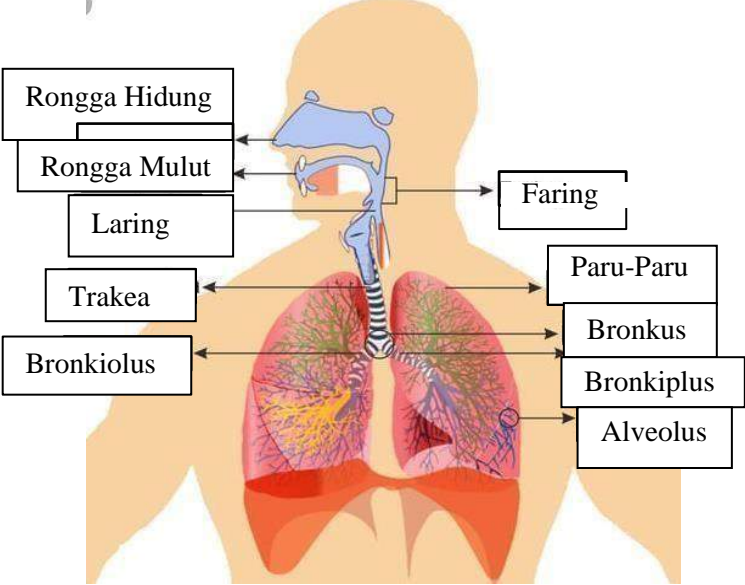
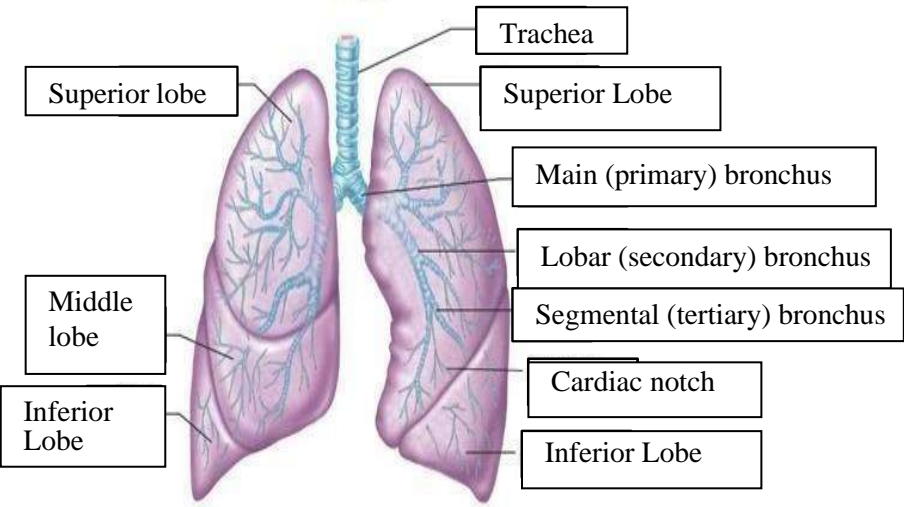
No	Keterangan	Pembahasan
1		 <p>This diagram shows a cross-section of the heart wall and its internal chambers. The layers of the heart wall are labeled as follows: Endocardium (innermost), Myocardium (middle), and Epicardium (outermost). The Interventricular Arseptum is shown separating the two ventricles. The chambers are labeled: Right Atrium, Left Atrium, Ventrikel Kiri (Left Ventricle), and Ventrikel Kanan (Right Ventricle).</p>
	<p>Vena Kav Superior</p> <p>A.Pulmonalis dekstra</p> <p>Pulmonalis veins</p> <p>Right Atrium</p> <p>Tricuspid Valve</p> <p>Right ventricle</p> <p>Inferior Vena Cava</p>	 <p>This diagram shows the heart with its major blood vessels and valves. The vessels are labeled: Vena Kav Superior, A.Pulmonalis dekstra, Pulmonalis veins, Aorta, Pulmonary Arteri, and Pulmonary v in. The valves are labeled: Pulmonary valve and Mitral valve. The chambers are labeled: Right Atrium, Left Atrium, Right ventricle, and Left Ventricl. The Cardiac Muscle is also labeled.</p>



**WORKSHEETS (LEMBAR KERJA)**

<b>Mata Kuliah</b>	: Anatomi
<b>Materi</b>	: Anatomi Respirasi
<b>NIM&gt;Nama Mahasiswa</b>	: 2110101001/SHAFIRDA INAYATI

No	Keterangan	Pembahasan
1	<p>An anatomical diagram of the human respiratory system. Labels include: Pharynx (throat), Esophagus (food pipe), Bronkus (bronchi), Paru Paru Kanan (right lung), Pleura (lung lining), Nasal Cavity (nose), Traches (trachea), Bronkiolus (bronchioles), Bronkus (bronchi), Paru-Paru Kiri (left lung), and Diafragma (diaphragm).</p>	

No	Keterangan	Pembahasan
		 <p>Diagram of the human respiratory system with labels:</p> <ul style="list-style-type: none"> <li>Rongga Hidung</li> <li>Rongga Mulut</li> <li>Laring</li> <li>Trakea</li> <li>Bronkiolus</li> <li>Faring</li> <li>Paru-Paru</li> <li>Bronkus</li> <li>Bronkiplus</li> <li>Alveolus</li> </ul>
		 <p>Detailed diagram of the lungs with labels:</p> <ul style="list-style-type: none"> <li>Trachea</li> <li>Superior lobe</li> <li>Middle lobe</li> <li>Inferior Lobe</li> <li>Superior Lobe</li> <li>Main (primary) bronchus</li> <li>Lobar (secondary) bronchus</li> <li>Segmental (tertiary) bronchus</li> <li>Cardiac notch</li> <li>Inferior Lobe</li> </ul>

