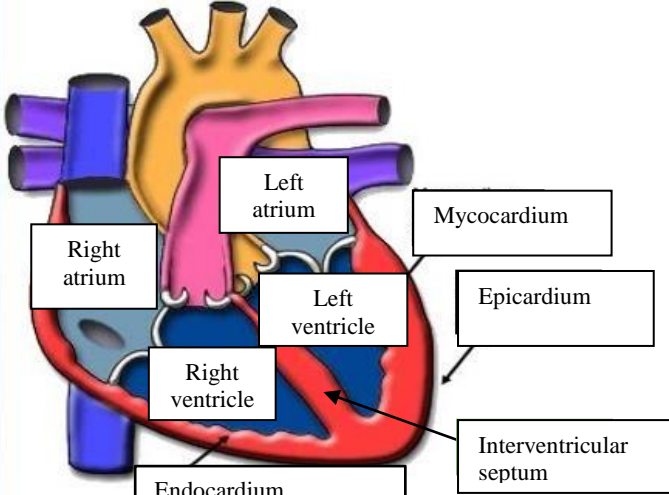
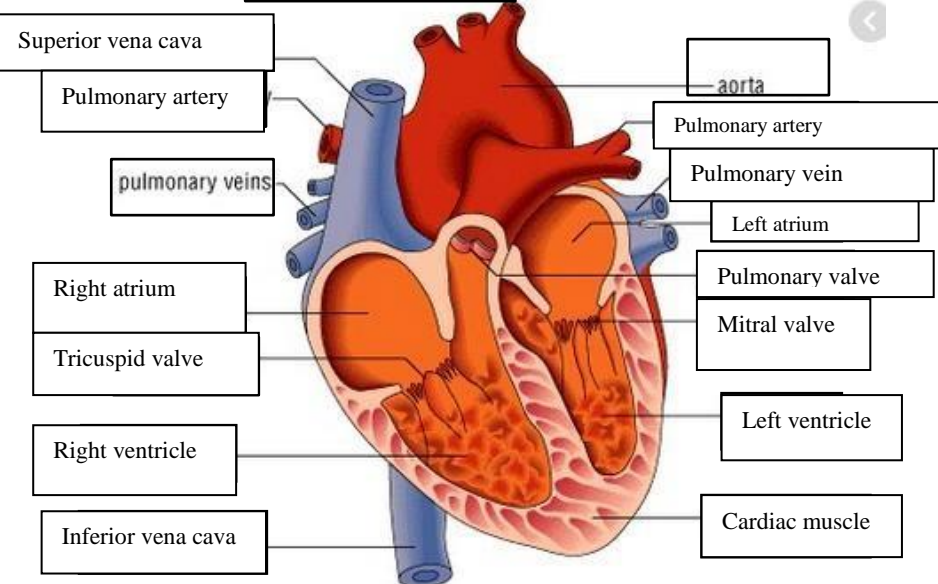
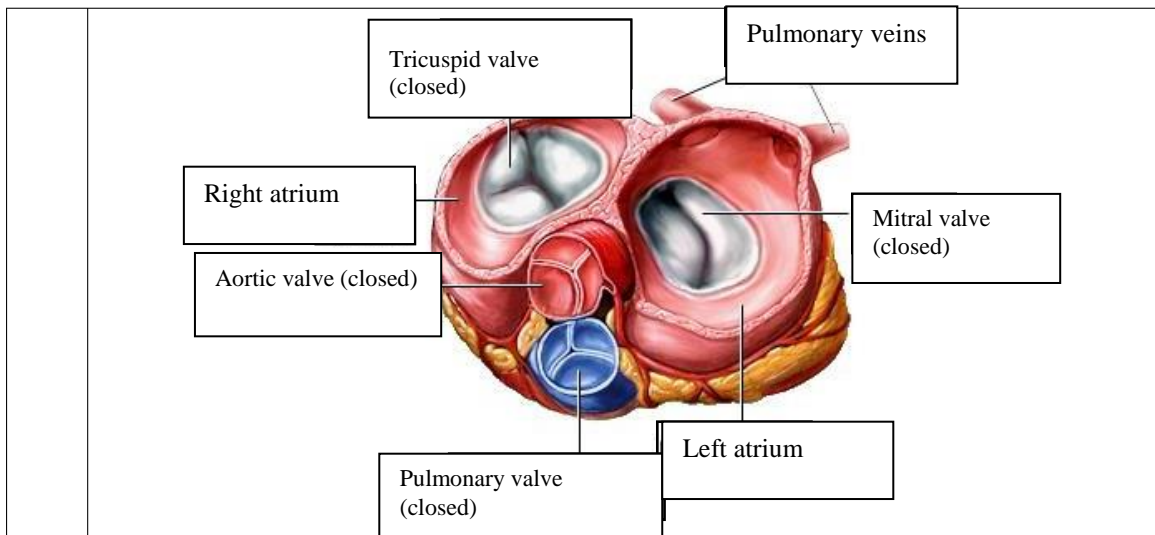


**WORKSHEETS (LEMBAR KERJA)**

<b>Mata Kuliah</b>	<b>: Anatomi</b>
<b>Materi</b>	<b>: Anatomi Cardiovaskuler</b>
<b>NIM&gt;Nama Mahasiswa</b>	<b>: 2110101025/Afifah Rosiana</b>

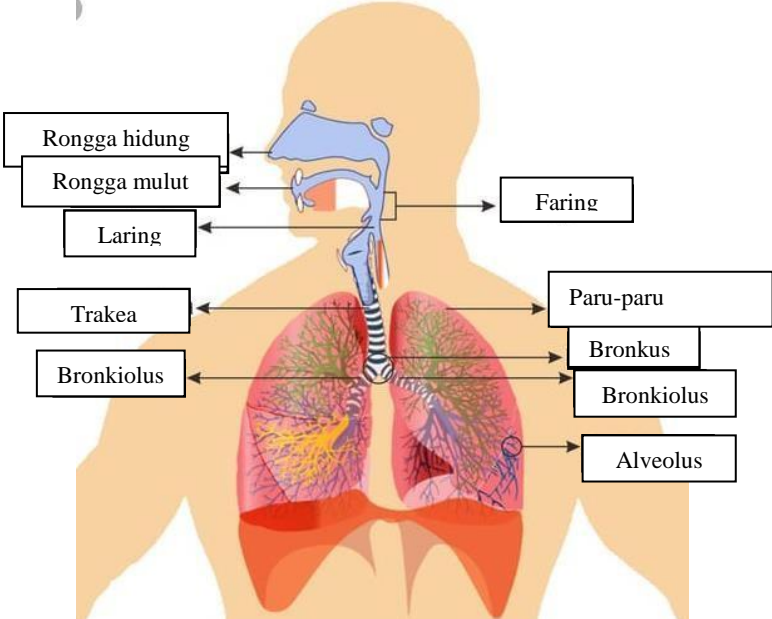
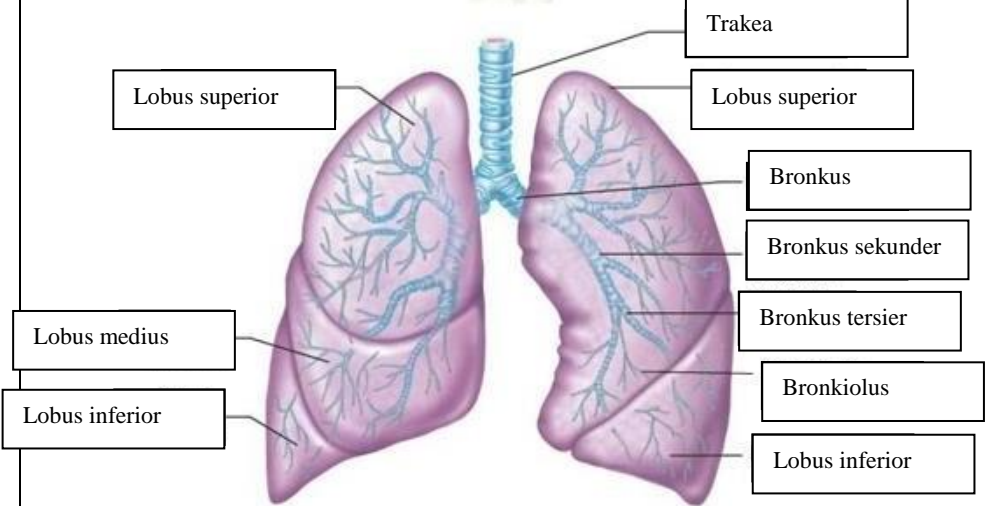
No	Keterangan	Pembahasan
1		
		



**WORKSHEETS (LEMBAR KERJA)**

<b>Mata Kuliah</b>	<b>: Anatomi</b>
<b>Materi</b>	<b>: Anatomi Respirasi</b>
<b>NIM&gt;Nama Mahasiswa</b>	<b>: 2110101025/Afifah Rosiana</b>

No	Keterangan	Pembahasan
1		<p>An anatomical diagram of the human respiratory system. Labels with leader lines point to the following parts: Faring (throat), Laring (voice box), Bronkus (bronchi), Paru-paru kanan (right lung), Pleura (lung lining), Diafragma (diaphragm), Rongga hidung (nasal cavity), Trakea (trachea), Bronkiolus (bronchioles), Bronkus (bronchi), and Paru-paru kiri (left lung).</p>

No	Keterangan	Pembahasan
		 <p>Diagram of the human respiratory system with labels:</p> <ul style="list-style-type: none"> <li>Rongga hidung</li> <li>Rongga mulut</li> <li>Laring</li> <li>Trakea</li> <li>Bronkiolus</li> <li>Faring</li> <li>Paru-paru</li> <li>Bronkus</li> <li>Bronkiolus</li> <li>Alveolus</li> </ul>
		 <p>Detailed diagram of the lungs with labels:</p> <ul style="list-style-type: none"> <li>Lobus superior</li> <li>Lobus medius</li> <li>Lobus inferior</li> <li>Trakea</li> <li>Lobus superior</li> <li>Bronkus</li> <li>Bronkus sekunder</li> <li>Bronkus tersier</li> <li>Bronkiolus</li> <li>Lobus inferior</li> </ul>

