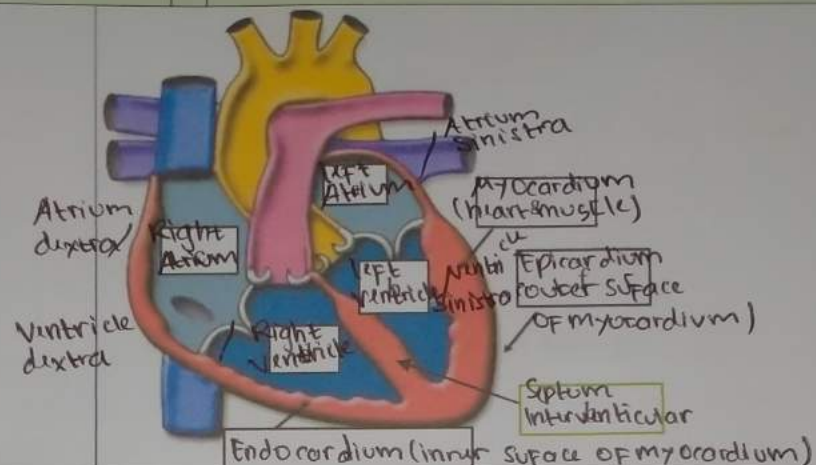
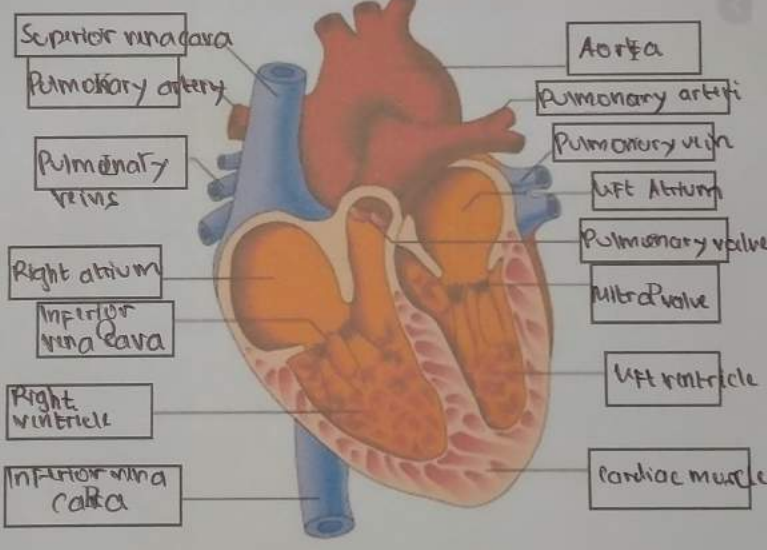
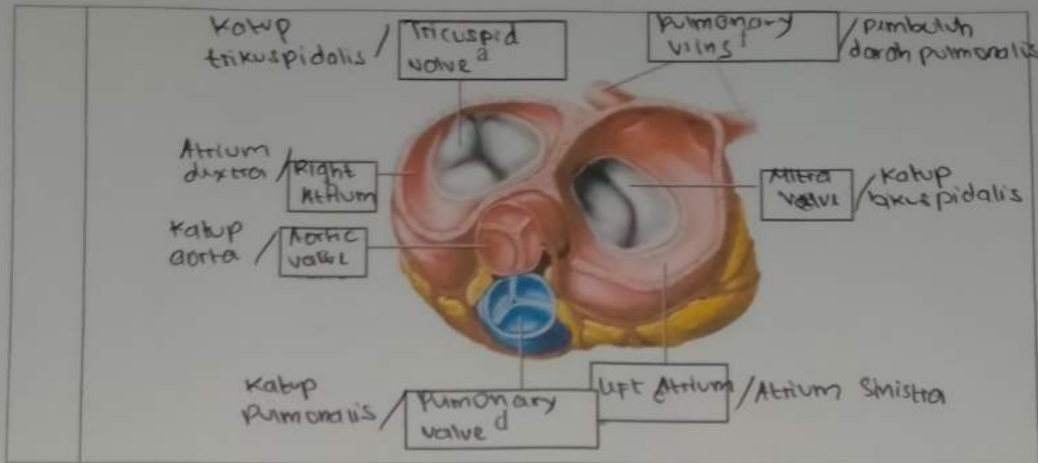


WORKSHEETS (LEMBAR KERJA)

Mata Kuliah	: Anatomi
Materi	: Anatomi Cardiovaskuler dan limfoti
NIM>Nama Mahasiswa	: MONIKA JUMARNIS /2110101006

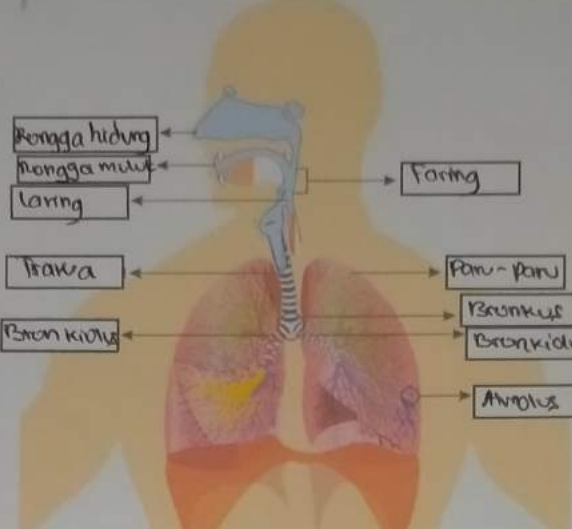
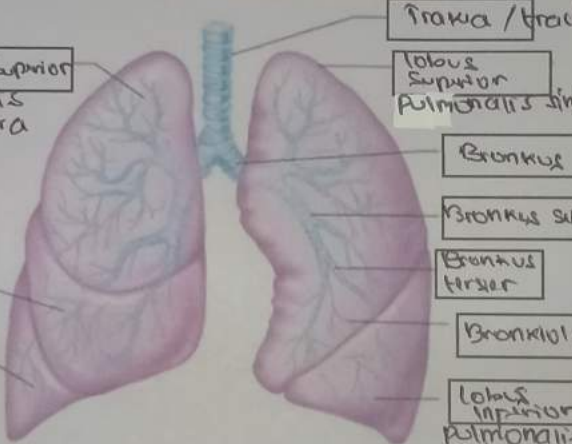
No	Keterangan	Pembahasan
1	 <p>A diagram showing a cross-section of the heart wall. The layers are labeled as follows: Endocardium (inner surface of myocardium), Myocardium (heart muscle), and Epicardium (outer surface of myocardium). The chambers shown are the Right Atrium, Left Atrium, Right Ventricle, and Left Ventricle. The Septum Interventricular is also indicated. Handwritten labels include: Atrium dextra, Right Atrium, Ventricle dextra, Right Ventricle, Atrium sinistra, Left Atrium, Myocardium (Heart muscle), Left Ventricle, Epicardium (outer surface of myocardium), and Septum Interventricular.</p>	
	 <p>A diagram of the heart with various vessels and valves labeled in boxes. On the left side, labels include: Superior vena cava, Pulmonary artery, Pulmonary veins, Right atrium, Inferior vena cava, Right ventricle, and Inferior vena cava. On the right side, labels include: Aorta, Pulmonary artery, Pulmonary vein, Left Atrium, Pulmonary valve, Mitral valve, Left ventricle, and Cardiac muscle.</p>	



WORKSHEETS (LEMBAR KERJA)

Mata Kuliah	: Anatomi
Materi	: Anatomi Respirasi
NIM>Nama Mahasiswa	: 2110101006 / MOAIKA LUMARAH

No	Keterangan	Pembahasan
1	Epiglottis / laring Bronkus lobus superior / paru-paru kanan lobus inferior / paru-paru Diafragma	Rongga Mulut Trakea Bronchus Bronkus Paru-paru Kiri / Sinistra Diafragma

No	Keterangan	Pembahasan
		 <p> Diagram of the human respiratory system with the following labels: <ul style="list-style-type: none"> Rongga hidung Rongga mulut Laring Trakea Bronkiolus Faring Paru-paru Bronkus Bronkiolus Diaphragma </p>
		 <p> Detailed diagram of the lungs with the following labels: <ul style="list-style-type: none"> Trakea / trachea Lobus Superior Pulmonalis dextra Lobus Superior Pulmonalis sinistra Bronkus Bronkus sekundur Bronkus tersier Bronkiolus Lobus Inferior Pulmonalis dextra Lobus Inferior Pulmonalis sinistra </p>