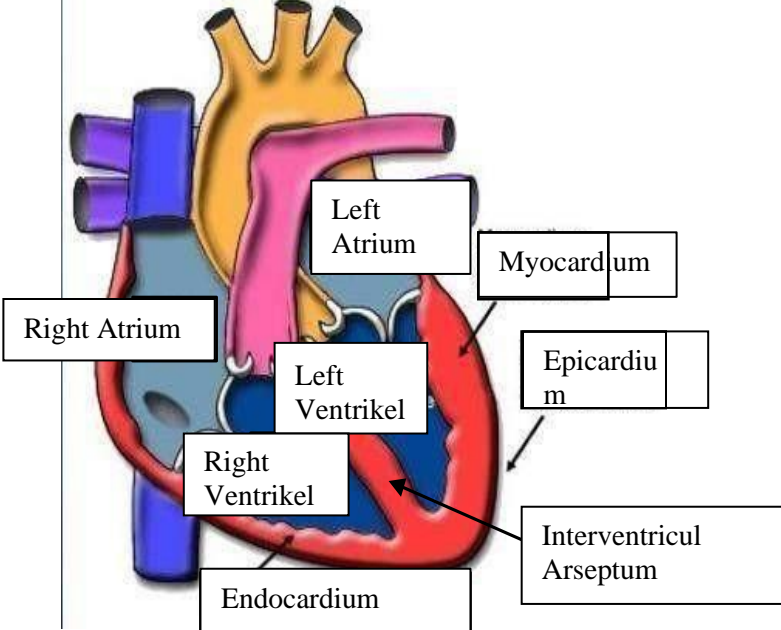
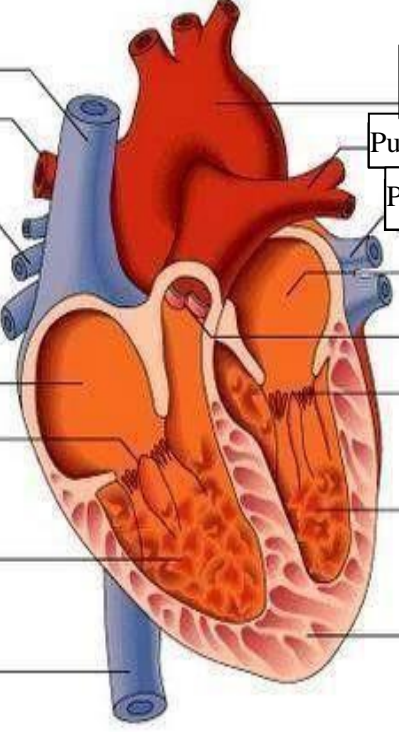
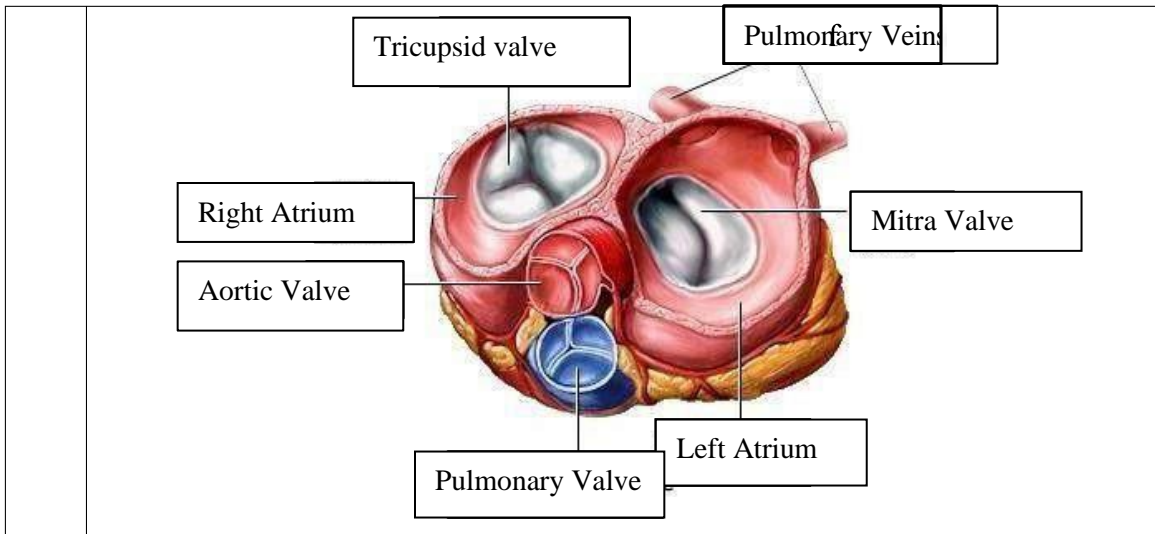


**WORKSHEETS (LEMBAR KERJA)**

<b>Mata Kuliah</b>	: Anatomi
<b>Materi</b>	: Anatomi Cardiovaskuler
<b>NIM/Nama Mahasiswa</b>	: 2110101015/Fitrilia Rahmawati

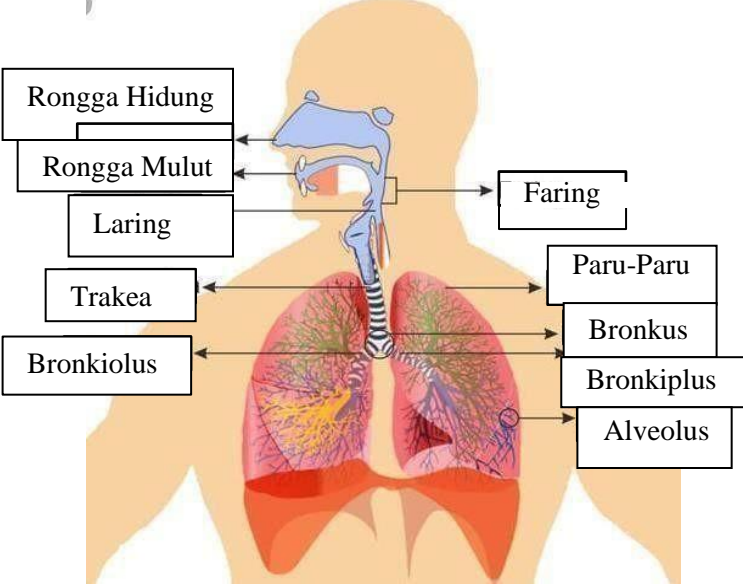
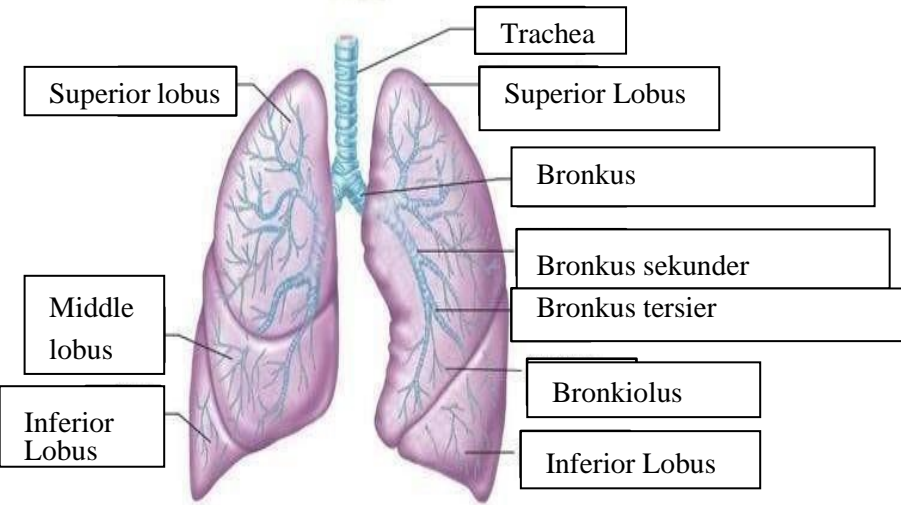
No	Keterangan	Pembahasan
1		 <p>This diagram shows a cross-section of the heart wall and its internal chambers. The chambers are labeled as the Right Atrium, Left Atrium, Right Ventrikel, and Left Ventrikel. The wall layers are labeled as the Endocardium (innermost), Myocardium (middle), and Epicardium (outermost). The Interventricular Arseptum is also shown separating the ventricles.</p>
	<p>Vena Kav Superior</p> <p>A. Pulmonalis dekstra</p> <p>Pulmonalis veins</p> <p>Right Atrium</p> <p>Tricuspid Valve</p> <p>Right ventricle</p> <p>Inferior Vena Cava</p>	 <p>This diagram shows the heart with its major vessels and valves. On the left side, the Aorta, Pulmonary artery, and Pulmonary vein are labeled. On the right side, the Vena Kav Superior, A. Pulmonalis dekstra, and Inferior Vena Cava are labeled. The chambers and valves are labeled as the Left Atrium, Pulmonary valve, Mitral valve, Left Ventricl, Cardiac Muscle, Right Atrium, Tricuspid Valve, and Right ventricle.</p>



**WORKSHEETS (LEMBAR KERJA)**

<b>Mata Kuliah</b>	<b>: Anatomi</b>
<b>Materi</b>	<b>: Anatomi Respirasi</b>
<b>NIM&gt;Nama Mahasiswa</b>	<b>: 2110101015/Fitrilia Rahmawati</b>

No	Keterangan	Pembahasan
1	<p>Pharynx</p> <p>Esophagus</p> <p>Bronkus</p> <p>Paru Paru Kanan</p> <p>Pleura</p> <p>Nasal Cavity</p> <p>Traches</p> <p>Bronkiolus</p> <p>Bronkus</p> <p>Paru-Paru Kiri</p> <p>Diafragma</p> <p>Detailed description: This diagram shows the human respiratory system. It includes the nasal cavity, pharynx, trachea (windpipe), bronchi (main airways), bronchioles (smaller airways), and the lungs (right and left). The diaphragm is shown at the base of the thoracic cavity. The pleura is the membrane surrounding the lungs. Labels with leader lines identify each part.</p>	

No	Keterangan	Pembahasan
		 <p>Diagram of the human respiratory system with labels: Rongga Hidung, Rongga Mulut, Laring, Trakea, Bronkiolus, Faring, Paru-Paru, Bronkus, Bronkiplus, Alveolus.</p>
		 <p>Detailed diagram of the lungs with labels: Superior lobus, Middle lobus, Inferior Lobus, Trachea, Superior Lobus, Bronkus, Bronkus sekunder, Bronkus tersier, Bronkiolus, Inferior Lobus.</p>

