

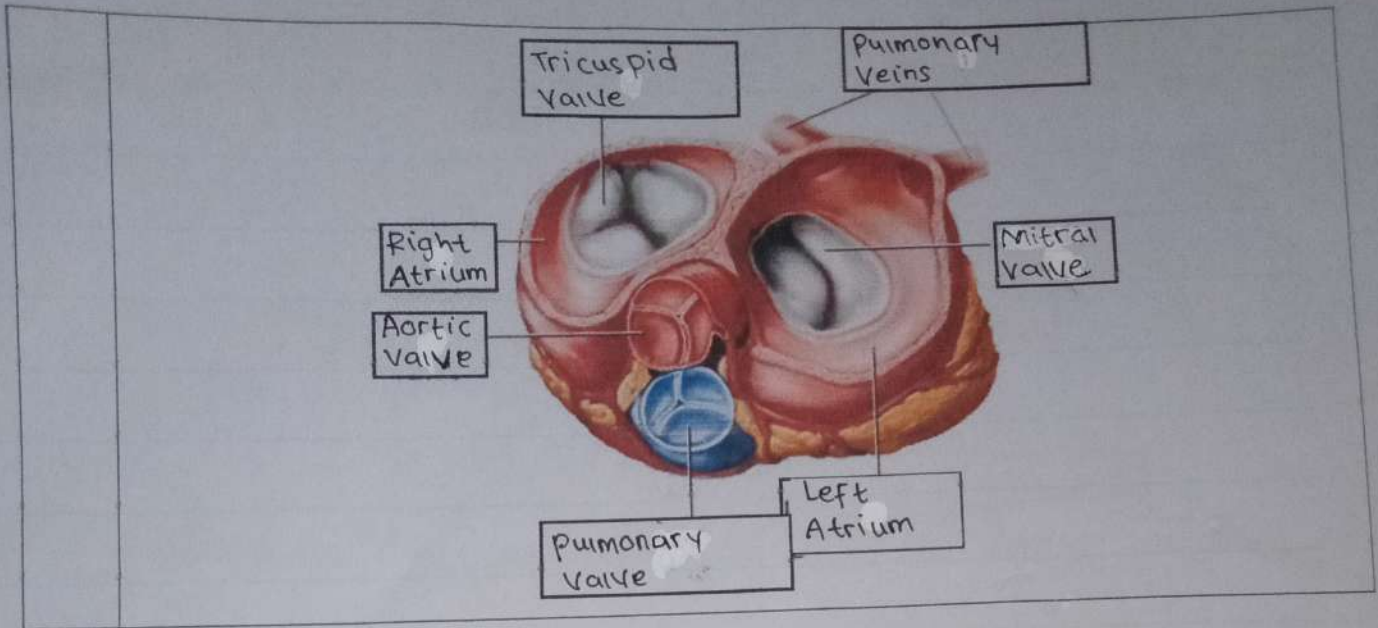
**WORKSHEETS (LEMBAR KERJA)**

<b>Mata Kuliah</b>	: Anatomi
<b>Materi</b>	: Anatomi Cardiovaskuler
<b>NIM&gt;Nama Mahasiswa</b>	: 2110101008 / Pita Aningsih

No	Keterangan	Pembahasan
----	------------	------------

1		
---	--	--

<ul style="list-style-type: none"> <li>Superior Vena cava</li> <li>pulmonary artery</li> <li>Pulmonary Veins</li> <li>Right Atrium</li> <li>tricuspid Valve</li> <li>right Ventricle</li> <li>Inferior Vena cava</li> </ul>		<ul style="list-style-type: none"> <li>Aorta</li> <li>Pulmonary artery</li> <li>Pulmonary Vein</li> <li>left Atrium</li> <li>Pulmonary valve</li> <li>mitral Valve</li> <li>left Ventricle</li> <li>Cardiac muscle</li> </ul>
---	--	---



**WORKSHEETS (LEMBAR KERJA)**

<b>Mata Kuliah</b>	: Anatomi
<b>Materi</b>	: Anatomi Respirasi
<b>NIM&gt;Nama Mahasiswa</b>	:

No	Keterangan	Pembahasan
1	<p>Faring</p> <p>Laring</p> <p>Bronkus</p> <p>Paru-paru Kanan</p> <p>Pleura</p> <p>Nasal cavity</p> <p>Trakea</p> <p>Bronkiolus</p> <p>Bronkus</p> <p>Paru-paru Kiri</p> <p>Diafragma</p>	

No	Keterangan	Pembahasan
----	------------	------------

