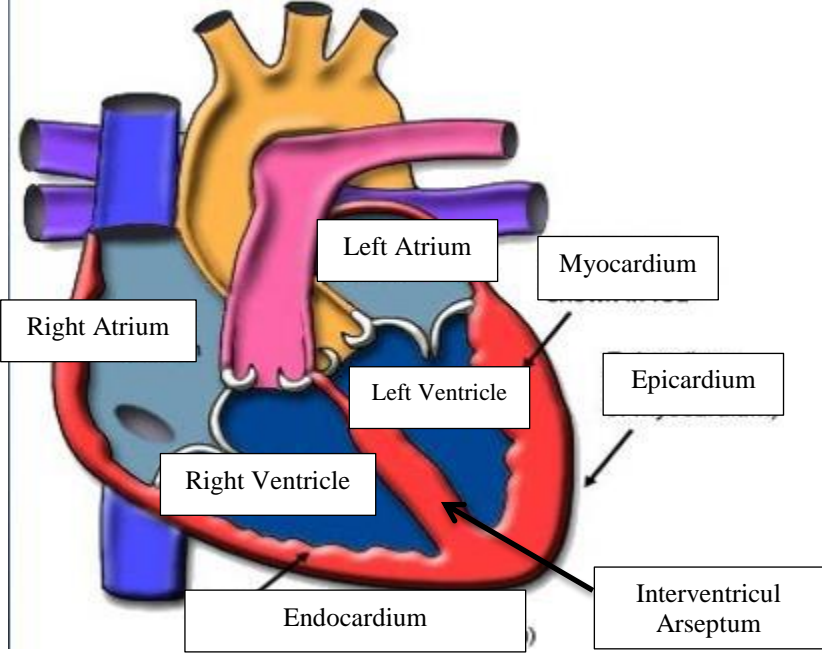
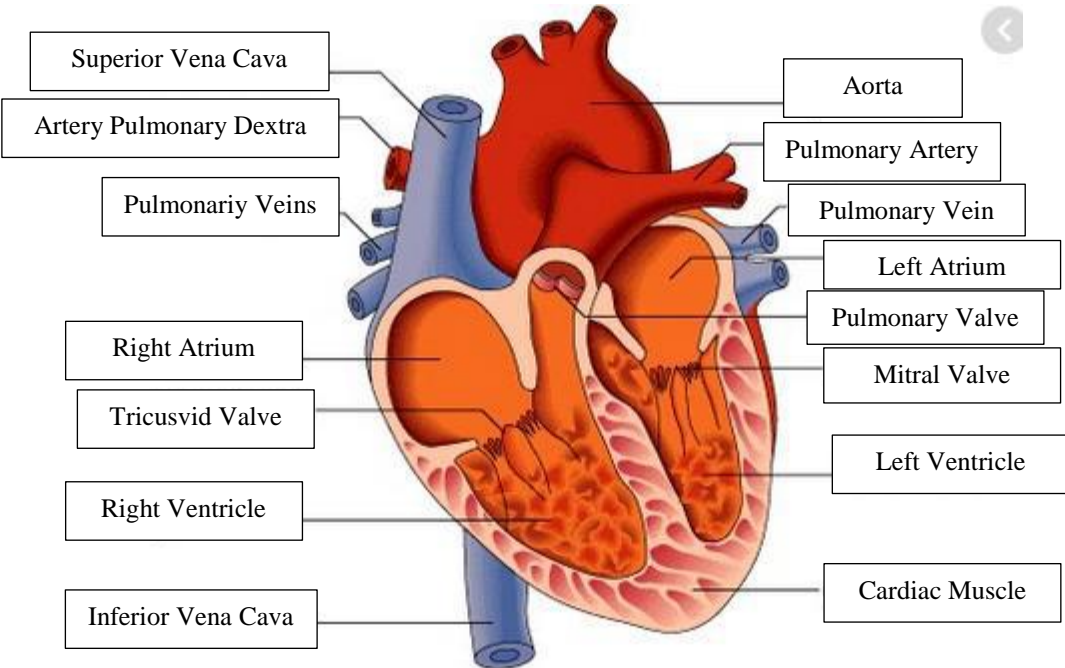
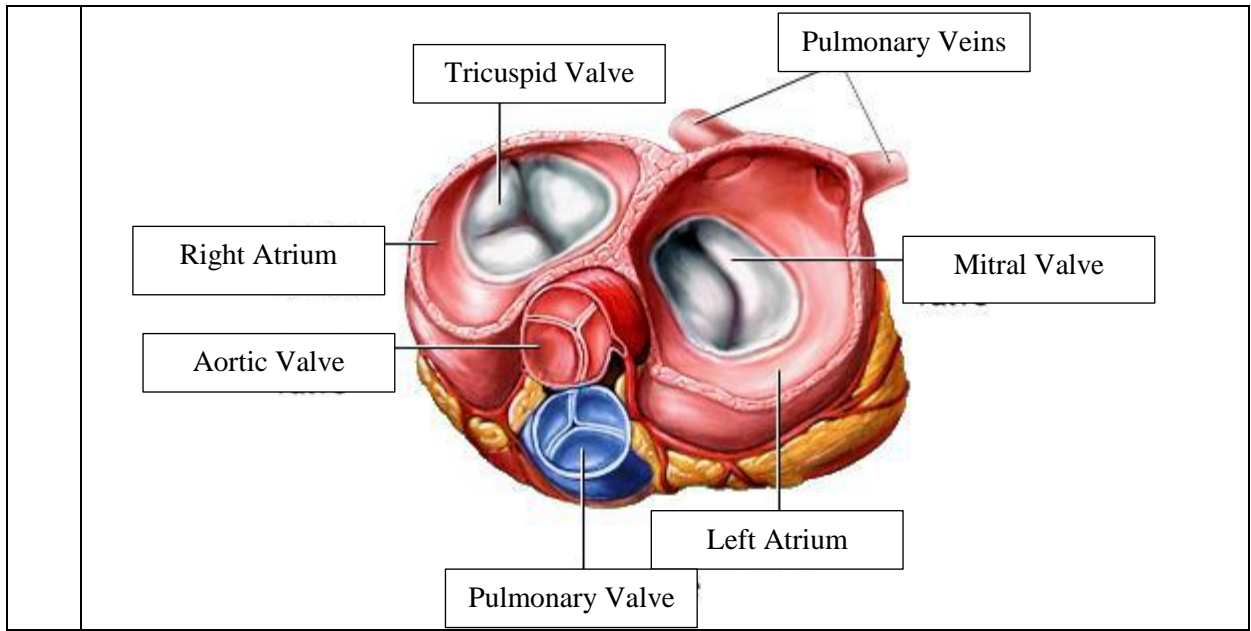


**WORKSHEETS (LEMBAR KERJA)**

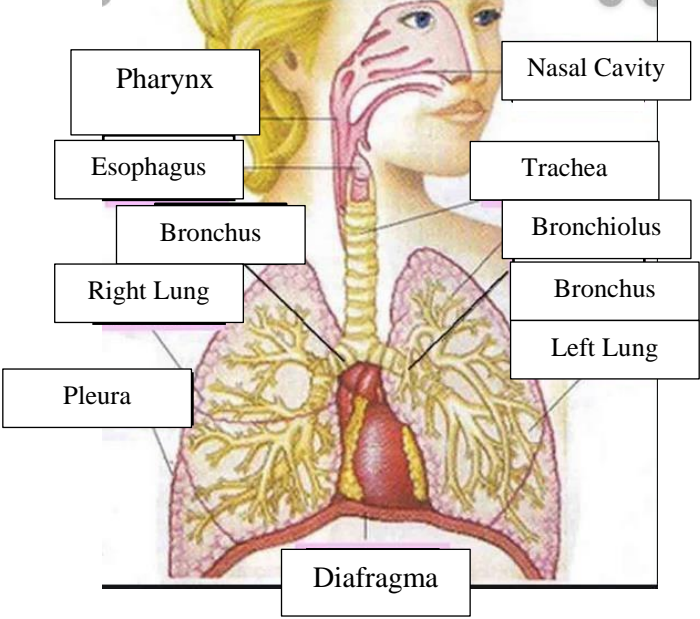
<b>Mata Kuliah</b>	: <b>Anatomi</b>
<b>Materi</b>	: <b>Anatomi Cardiovaskuler</b>
<b>NIM&gt;Nama Mahasiswa</b>	: <b>2110101009/Azira Syiffa Ramadhani</b>

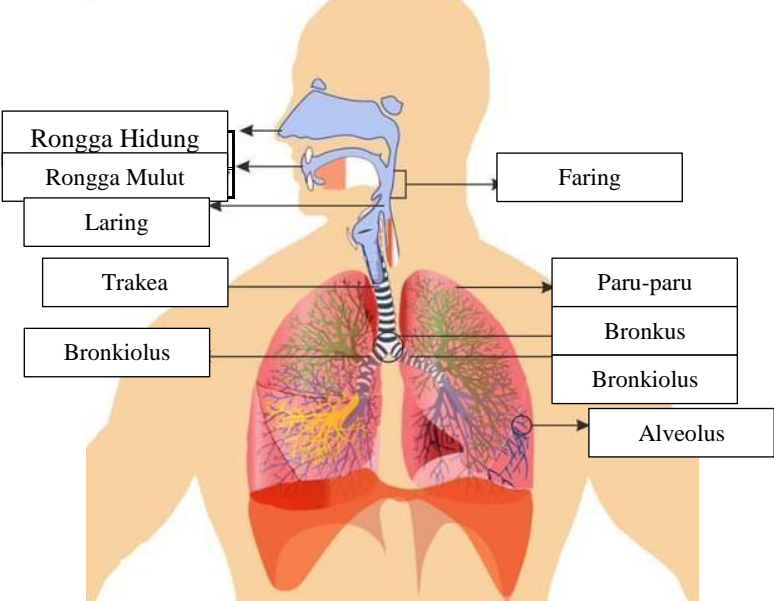
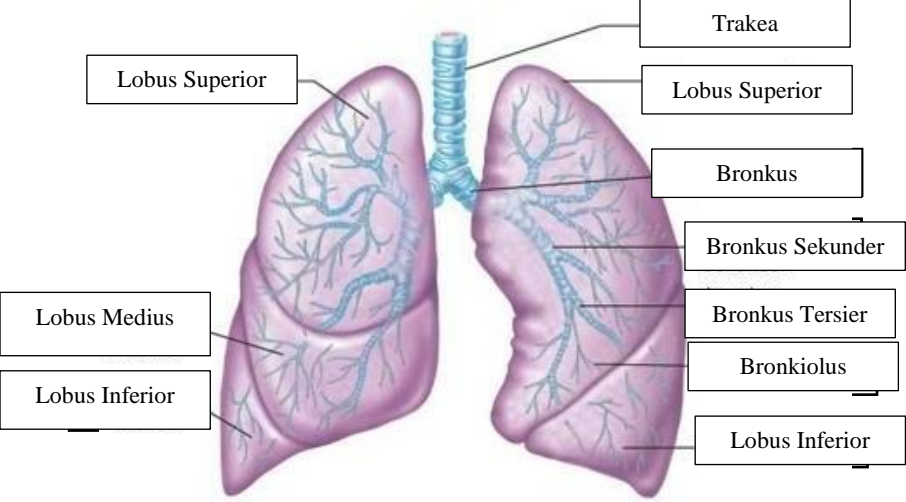
No	Keterangan	Pembahasan
		 <p>This diagram shows a cross-section of the heart wall and its chambers. The chambers are labeled: Right Atrium, Left Atrium, Right Ventricle, and Left Ventricle. The wall layers are labeled: Endocardium (innermost), Myocardium (middle), and Epicardium (outermost). The Interventricular Arseptum is also labeled, separating the right and left ventricles.</p>
		 <p>This diagram shows a cross-section of the heart with its major vessels and valves. The vessels are labeled: Superior Vena Cava, Artery Pulmonary Dextra, Pulmonary Veins, Inferior Vena Cava, Aorta, Pulmonary Artery, and Pulmonary Vein. The valves are labeled: Tricuspid Valve, Pulmonary Valve, and Mitral Valve. The chambers are labeled: Right Atrium, Right Ventricle, Left Atrium, and Left Ventricle. The Cardiac Muscle is also labeled.</p>



**WORKSHEETS (LEMBAR KERJA)**

<b>Mata Kuliah</b>	<b>:</b>	<b>Anatomi</b>
<b>Materi</b>	<b>:</b>	<b>Anatomi Respirasi</b>
<b>NIM&gt;Nama Mahasiswa</b>	<b>:</b>	<b>2110101009/Azira Syiffa Ramadhani</b>

No	Keterangan	Pembahasan
1		 <p>The diagram illustrates the human respiratory system. On the left side, labels point to the Pharynx, Esophagus, Bronchus, Right Lung, and Pleura. On the right side, labels point to the Nasal Cavity, Trachea, Bronchiolus, Bronchus, and Left Lung. At the bottom, a label points to the Diafragma (diaphragm).</p>

No	Keterangan	Pembahasan
		 <p>Diagram of the human respiratory system with labels:</p> <ul style="list-style-type: none"> <li>Rongga Hidung</li> <li>Rongga Mulut</li> <li>Laring</li> <li>Trakea</li> <li>Bronkiolus</li> <li>Faring</li> <li>Paru-paru</li> <li>Bronkus</li> <li>Bronkiolus</li> <li>Alveolus</li> </ul>
		 <p>Diagram of the lungs with labels:</p> <ul style="list-style-type: none"> <li>Lobus Superior</li> <li>Lobus Medius</li> <li>Lobus Inferior</li> <li>Trakea</li> <li>Lobus Superior</li> <li>Bronkus</li> <li>Bronkus Sekunder</li> <li>Bronkus Tersier</li> <li>Bronkiolus</li> <li>Lobus Inferior</li> </ul>